

Comprehensive Review

Anatomy, Pathophysiology and Interventional Therapies for Chronic Pelvic Pain: A Review

Corey W. Hunter, MD¹, Brad Stovall, DO², Grant Chen, MD³, Jonathan Carlson, MD⁴, and Robert Levy, MD, PhD⁵

From: ¹Dept. Physical Medicine and Rehabilitation, Ainsworth Institute of Pain Management, Icahn School of Medicine at Mount Sinai, New York, NY; ²Virginia Commonwealth University, VCU Health, Richmond, VA; ³Memorial Sloan-Kettering Cancer Center, New York, NY; ⁴Arizona Pain, Glendale, AZ; ⁵Boca Raton Regional Hospital, Boca Raton, FL

Address Correspondence:
Corey W. Hunter, MD
Dept. Physical Medicine and Rehabilitation
Ainsworth Institute of Pain Management
Icahn School of Medicine at Mount Sinai
115 East 57th Street, Suite 1210
New York, NY 10022
E-mail:
chunter@ainpain.com

Disclaimer: There was no external funding in the preparation of this manuscript.
Conflict of interest: Dr. Hunter is a consultant for Abbott, Nevro, Nuvectra, and Flonox. He is on the medical advisory board for Vertiflex and on the speaker's bureau for Jazz.

Manuscript received: 07-31-2017
Accepted for publication:
09-25-2017

Free full manuscript:
www.painphysicianjournal.com

Background: Chronic pelvic pain (CPP) represents a group of poorly understood disorders that are often refractory to conventional treatment. Referral to pain management typically occurs later in the continuum of care; as such, many of the injections and nerve blocks commonly prescribed for such patients are potentially limited in efficacy. While neuromodulation is conventionally considered the next algorithmic step in the treatment of chronic pain after injections fail, there is a common perception that neuromodulation is largely ineffective for CPP conditions. However, there is evidence that suggests neuromodulation may in fact be a viable treatment option for this particular patient population when utilized properly.

Objectives: To provide a basic overview of the pathophysiology of CPP and the relevant neuroanatomy as it pertains to various available treatment options, as well as the techniques and potential targets for neuromodulation.

Study Design: Literature review.

Setting: Private practice, academic and hospital setting.

Methods: A comprehensive review of the available literature was performed targeting publications focused on CPP and various techniques for utilizing neuromodulation to treat it.

Results: Neuromodulation is an established treatment modalities, however its usefulness as it relates to treating CPP has typically been drawn into question. In this literature review, we discuss the efficacy of various techniques for treating CPP with neuromodulation.

Limitations: Evidence to support the various treatments, while encouraging, is based on small studies and case series. Large-scale randomized, placebo-controlled clinical trials are warranted to evaluate the clinical efficacy and safety of the different treatments described, particularly neuromodulation.

Conclusions: In addition to the percutaneous, injection-based treatments described herein, neuromodulation remains a plausible option for recalcitrant cases that fail to respond to more conventional means.

Key words: Chronic pelvic pain, neuromodulation, spinal cord stimulation, CRPS, complex regional pain syndrome, neuropathic pain.

Pain Physician 2018; 21:147-167

Rather than a single objective diagnosis, chronic pelvic pain (CPP) represents a number of complex, potentially debilitating disorders defined as "a nonmalignant pain

perceived in the pelvis in either men or women...in the case of documented nociceptive pain that becomes chronic, the pain must have been continuous for at least 6 months (1)." From this published definition, it is clear

that CPP is a nonspecific, all-inclusive term that includes a variety of diagnoses ranging from pudendal neuralgia (PN) and coccydynia to prostaticdynia, vulvodynia, and

painful bladder syndrome (2). In broad terms, the usual symptoms of CPP include neuropathic symptoms, such as paresthesias, numbness, burning, or lancinating pain, in the pelvis, anus, and/or genitals. Pain often occurs with sitting, urinating, defecating, intercourse, and ejaculation.

Table 1. Gender-specific causes (2,11).

Women	Men
Infection	Prostatitis
Endometriosis	Chronic Orchalgia
Dysmenorrhea	Prostaticdynia
Dysparenia	Interstitial Cystitis
Myofascial Pain Syndrome	Scrotal Pain
Vulvodynia	Penile Pain
Vulvitis	Ureteral Obstruction
Cystitis	Irritable Bowel Syndrome
Ovarian Remnant Congestion	Sexual/Physical Abuse
Sympathetically Mediated Pain	Cancer Pain
Pelvic Congestion	Psychiatric Disorders
Pelvic Fibrosis	Proctalgia Fugax
Pelvis Neurodystonia	Radiation proctitis
Irritable Bowel Syndrome	Surgical Procedures (adhesions)
Sexual/Physical Abuse	
Cancer Pain	
Psychiatric Disorders	
Surgical Procedures (adhesions)	

While the exact cause is unclear, there are a variety of gender and organ specific conditions which carry a high risk for the development of CPP (Tables 1 and 2). In many cases, CPP is a diagnosis of exclusion likely encompassing other pathologic states, and often comprises an evolution of those states into a clearly chronic neuropathic pain (NP) condition. It has been compared to complex regional pain syndrome (CRPS) due to the many similarities the 2 conditions share (1,3,4). Just as patients with CRPS complain of allodynia and hyperesthesia in the affected area(s), those suffering with CPP will similarly report extreme pain from normally nonnoxious stimuli like urination, sensation of a full bladder, ovulation, or sexual intercourse. There also appears to be central sensitization (5), dysfunction, autonomic dysregulation (pelvic congestion), and a significant sympathetic component to both conditions, at least in the early stages – each usually responds to sympathetic blocks: CRPS with stellate or lumbar sympathetic blocks and CPP with ganglion of impar or hypogastric blocks (6).

Table 2. Organ-specific causes (2,11).

Organ System	Organ-Specific Pathologies
Reproductive	Visceral: uterus, ovaries, bladder, urethra Somatic: skin, vulva, clitoris, vaginal canal Adhesions, endometriosis, salpingo-oophoritis
Vascular	Dilated pelvic vein/pelvic congestions theory
Musculoskeletal	Ligamentous structures, muscular (iliopsoas, piriformis, quadratus lumborum, sacroiliac joint, obturator internus, pubococcygeus) Skeletal (referred pain) Pelvic floor muscle tension/spasm
Spinal	Degenerative joint disease, disc herniation, spondylosis, neoplasm of spinal cord/sacral nerve, coccydynia, degenerative disease
Neurologic	Neuralgia/cutaneous nerve entrapment (surgical scar in the lower part of the abdomen), iliohypogastric, ilioinguinal, genitofemoral, lateral femoral cutaneous nerve, PN, shingles (herpes zoster infection), spine-related nerve compressions
Gastrointestinal	Irritable bowel syndrome, abdominal epilepsy, abdominal migraine, recurrent small bowel obstruction, hernia
Urologic	Bladder dysfunction, chronic (nonbacterial) prostatitis, chronic orchalgia, and prostaticdynia
Psychological (Psychosocial/ Sexual)	Anxiety, depression, somatization, physical or sexual abuse, drug addiction, dependence, family problems, sexual dysfunction

In many cases of CPP, there is a history of injury, related surgical procedure or medical condition (i.e., endometriosis, ectopic pregnancy, infection, etc.) that one can point to, predating the development of CPP, which may have precipitated a cascade of events leading to this neuropathic syndrome (5). Much like CRPS, this event may be innocuous or a routine surgical procedure resulting in a nerve injury that fails to heal (7).

Intuitively, spinal cord stimulation (SCS) would appear to be an appropriate therapy for CPP. SCS has proven track record when it comes to treating CRPS, and CRPS is among the top 5 most common etiologies treated with SCS (8,9). Given the neuropathic, “CRPS-like” nature of CPP, SCS would be a logical choice for refractory cases. Despite appreciable crossover between CPP and CRPS, interventional pain physicians have unfortunately experienced a great deal of frustration with the use of SCS for these disorders. CPP patients have the highest rate of explant of all diagnoses treated with SCS at 33.3% with the most commonly reported reason for explantation being loss of therapeutic effect (39%) (10). While there is no published data reporting the ratio of trials to perma-

nently implanted systems in CPP patients, anecdotally they are amongst the lowest. While there is no obvious reason for these disproportionately higher failure rates, the complex innervation of the pelvic region makes obtaining adequate coverage to the painful area(s) a challenge.

Unlike most other regions of the body, which have predictable dermatomal patterns of innervation, the dermatomes of the pelvic region are much less intuitive. Progressing caudally for the low back and legs, for example, the innervation progresses in a linear fashion from L2 to L3 to L4, etc. The pelvic region, on the other hand, has a more three-dimensional representation and the dermatomal enervation appears to skip in a nonadjacent manner (Fig. 1). For example, a patient complaining of pain in the pubic/groin region with radiation into the perineum has a dermatomal pain distribution potentially involving T12, L1, and L2, as well as S2 and S3 (Table 3). This presents an obvious challenge when attempting to identify the spinal target for SCS.

In summary, the obstacles for treating CPP with SCS include difficulties in determining the location of the pain generator, via what nerves this pain is communicated to the spinal cord, and how to capture multiple dermatomes simultaneously that span relatively large

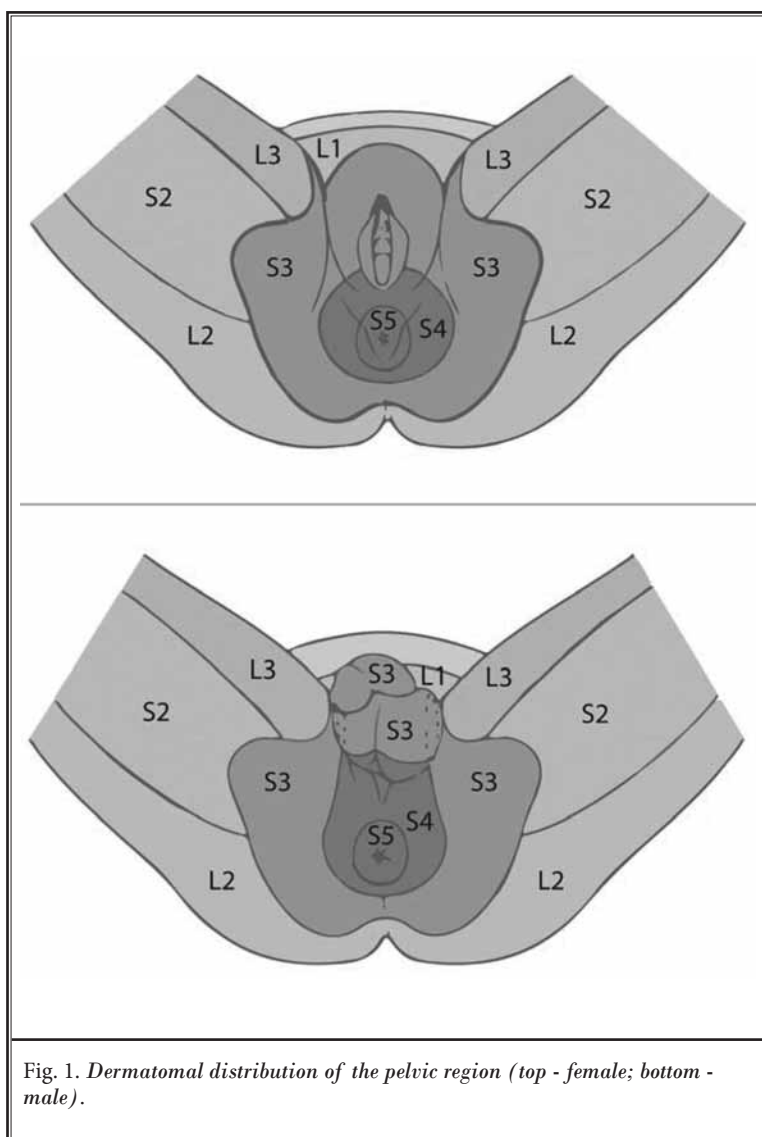


Fig. 1. Dermatomal distribution of the pelvic region (top - female; bottom - male).

Table 3. Nerves of the pelvic region and the spinal segments from which they receive innervation.

Nerve	T12	L1	L2	L3	L4	S1	S2	S3	S4	S5
Iliohypogastric	■									
Ilioinguinal		■								
Genitofemoral		■	■							
Obturator			■	■	■					
Posterior Femoral Cutaneous						■	■	■	■	
Inferior Rectal							■	■	■	
Pudendal							■	■	■	
Coccygeal									■	■

distances within the spinal cord. A fundamental understanding of the anatomy of the innervation of the pelvic region is essential when considering how and where to administer interventional therapies.

INNERVATION OF THE PELVIC REGION

The visceral pain and sympathetic nerve fibers of the pelvic region often travel with somatic fibers. Each spinal nerve receives sympathetic input from unmyelinated, postganglionic fibers via gray rami communicans (GRC) from the adjacent ganglion. White rami communicans (WRC), present from T1 to L1 or L2, allow this input to continue into the spinal cord, now as myelinated, preganglionic fibers (2). This would suggest that information carried within sympathetic fibers originating in the pelvic region below L2 would enter the paravertebral chain at its respective level through the GRC, travel within the chain cephalad until at least L2 (or potentially even higher) seeking out the first WRC to enter the spinal cord and report to the central nervous system (Figs. 2 and 3).

Sympathetic Innervation

The pelvic viscera are sympathetically innervated through fibers from T12 to L2. Most sympathetic information traveling to and from the pelvic region arises from the thoracolumbar spinal cord via the superior hypogastric plexus.

Parasympathetic Innervation

The pelvic viscera receives parasympathetic innervation through the S2 to S4 nerve roots. The parasympathetic outflow is transmitted via the aforementioned roots in the splanchnic nerves, which converge into the preganglionic pelvic splanchnic nerves.

Pelvic Splanchnic Nerves

Also known as the nervi erigentes, these are splanchnic nerves arising from the S2, S3, and S4 spinal nerves that provide parasympathetic innervation to the hindgut.

Sacral Splanchnic Nerves

These are paired visceral nerves connecting the

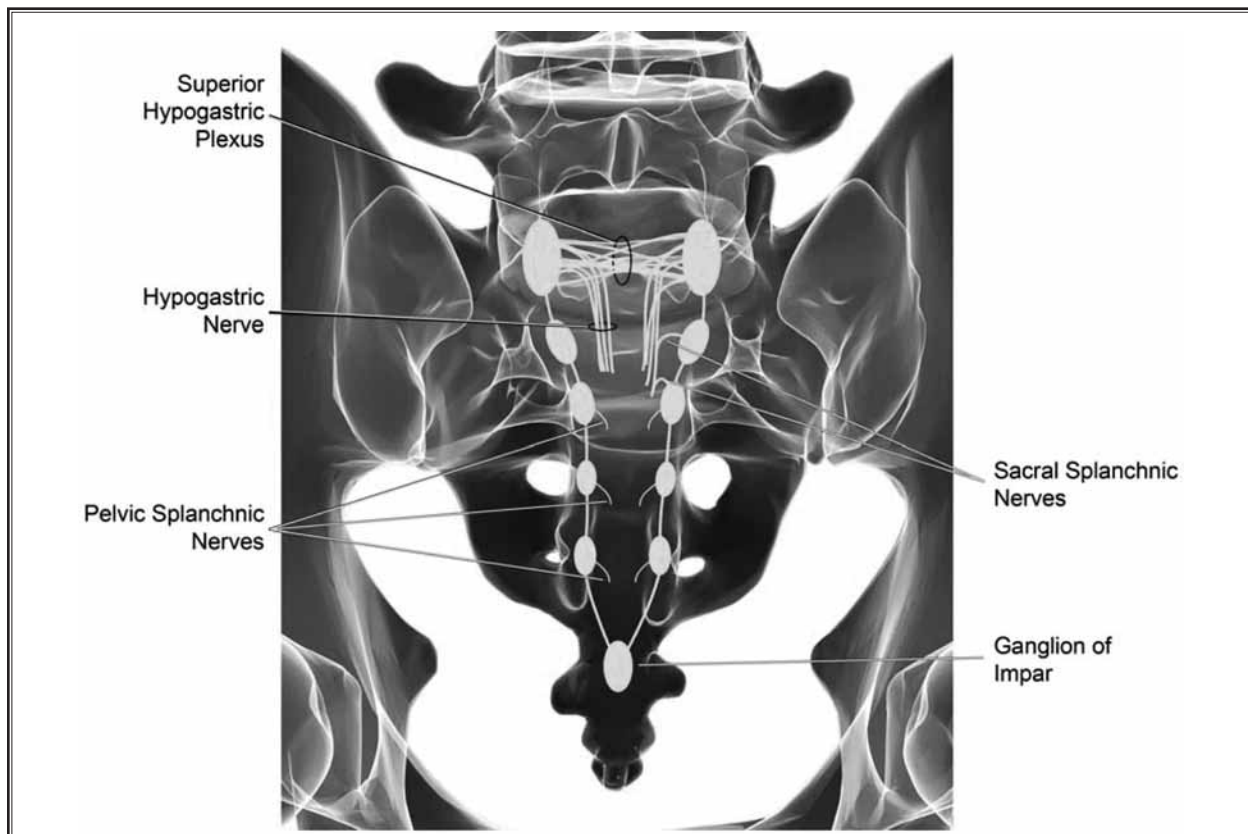
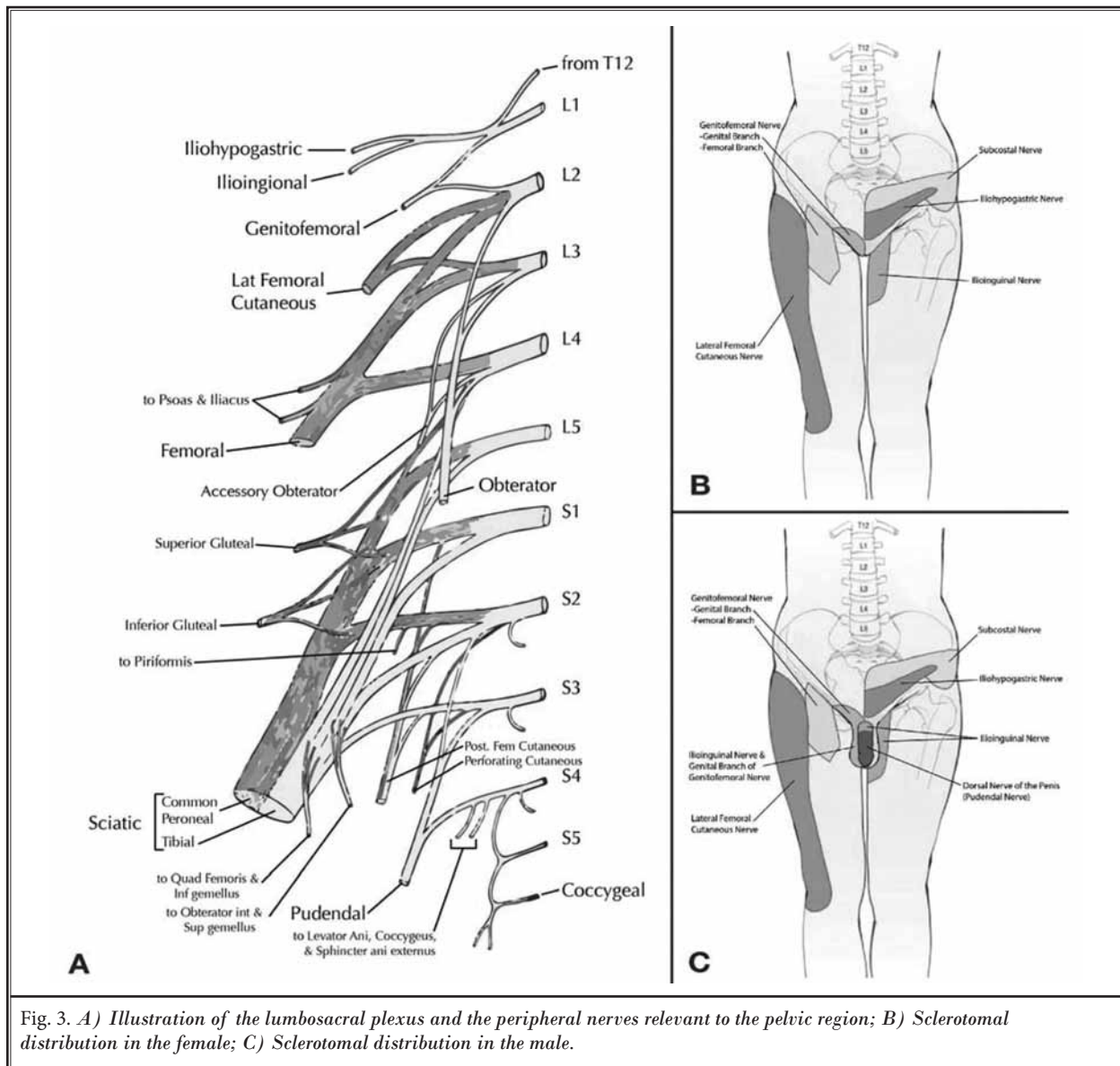


Fig. 2. Illustration of the sympathetic and parasympathetic innervation of the pelvic region.



inferior hypogastric plexus to the sympathetic trunk in the pelvis. The fibers emerge anteriorly from the ganglia of the sympathetic trunk and are comprised of a mix of preganglionic and mostly postganglionic fibers.

Superior Hypogastric Plexus

The superior hypogastric plexus is a collection of nerves located in the retroperitoneal space at the bifurcation of the aorta and lies directly in front of the L5-S1 intervertebral disc. It contains afferent and efferent fibers from the SNS (LEVY: spell out SNS) and

to a lesser extent carries parasympathetic information to the structures of the pelvis as well (11). Overall, it provides innervation to most, if not all, structures of the pelvic region: the bladder, urethra, vagina, vulva, ovaries, prostate, penis, testicles, uterus, ureter, pelvic floor (perineum), descending colon, and rectum.

Inferior Hypogastric Plexus

The inferior hypogastric plexus is a continuation of the superior hypogastric plexus and forms the hypogastric nerve. It is located on either side of the rectum, in men and the vagina in women. It supplies innervation

to the uterovaginal plexus, prostatic plexus, visceral plexus, and middle rectal plexus.

Ganglion of Impar

The ganglion of impar, also known as the ganglion of Walther or sacrococcygeal ganglion, is a singular retroperitoneal structure located at the level of the sacrococcygeal junction (SCJ). There are 4 or 5 small sacral ganglia with the ganglion impar being the most caudal segment of the confluence of the sacral sympathetic chain as it passes anteromedially over the sacrum. More specifically, the ganglion impar is the terminal fusion of the 2 sacral sympathetic chains and is located with some anatomical variability between the SCJ and the lower segment of the first coccygeal segment. The fusion of the 2 chains typically positions the ganglion midline, which makes it relatively easy to find. There is, however, a wide range of variability in the anatomical location of the SCJ (12).

This structure is of particular importance when considering patients who suffer from pain in the pelvic and perineal structures as it provides nociceptive and sympathetic supply to those regions. It receives afferent innervation from the perineum, distal rectum, anus, distal urethra, distal vagina, vulva, coccyx, and scrotum.

Pudendal Nerve

The pudendal nerve is considered the main nerve of the perineum and chief sensory nerve of the external genitalia carrying sensory, motor, somatic, and sympathetic innervations (13). It is derived from anterior divisions of the ventral rami of the S2, S3, and S4 nerves of the sacral plexus. Anatomically, it originates in Onuf's nucleus within the sacral region of the spinal cord; it curves around the ischial spine and sacrospinous ligament and enters the perineum through the lesser sciatic foramen (14) then exiting the pelvis through the greater sciatic notch between the piriformis and coccygeus muscles. It accompanies the internal pudendal artery along the lateral wall of the ischiorectal fossa in the pudendal canal. Its branches include the inferior rectal nerves and the perineal nerve; it terminates as the posterior scrotal/labial nerves and the dorsal nerve of the penis/clitoris.

The pudendal nerve innervates the external genitalia of both men and women (including the bulbospongiosus and ischiocavernosus), as well as the bladder, rectum, pelvic floor muscles, the skin and muscles of the perineum, the external urethral sphincter, and the external anal sphincter. It also contains sympathetic fibers which innervate penile erectile tissue.

Obturator Nerve

The obturator nerve is derived from the lumbar plexus (from L2 to L4) and provides the majority of innervation to the hip joint, including the adductor, obturator, gracilis, and pectineous muscles. It contains 2 branches: the anterior branch provides sensation to the hip joint and superficial adductors with a cutaneous branch at the medial aspect of the distal thigh; and the posterior branch provides motor innervation to the deep adductors and an articular branch to the posterior knee joint. Anatomically, it courses in the extraperitoneal fat along the lateral wall of the pelvis to the obturator canal; it then divides into anterior and posterior parts; the anterior branch runs between the adductor longus and brevis muscles, while the posterior branch descends between adductor brevis and magnus muscles. It emerges at the medial border of the psoas major, passes through the pelvis to the medial thigh and eventually exits the pelvis through the obturator canal. The obturator nerve also communicates with the saphenous nerve to supply the skin on the anterior, medial, and posterior proximal thigh.

Genitofemoral Nerve

The genitofemoral nerve is derived from the upper portion of the lumbar plexus with fibers of the L1 and L2 nerve roots. Anatomically, it descends on the anterior surface of psoas major and divides into genital and femoral branches. The femoral branch supplies skin over femoral triangle while the genital branch supplies skin over the scrotum and labia majora, as well as the cremaster muscle. In men, the genital branch travels with the spermatic cord in the inguinal canal, while in women, it terminates in the skin of the mons pubis and labia majora. It is responsible for both the efferent and afferent limbs of cremasteric reflex.

Ilioinguinal Nerve

The ilioinguinal nerve arises from the ventral ramus of L1 with occasional input from T12. Anatomically, the ilioinguinal nerve runs between the second and third layers of abdominal muscles and passes in the inguinal canal. It enters the abdomen posterior to the medial arcuate ligaments and runs inferior-laterally through the transverse abdominal muscle, while its branches pierce the external oblique aponeurosis. It accompanies the blood and lymphatic vessels, the spermatic cord, or round ligament in the inguinal canal of both genders. The ilioinguinal nerve supplies cutaneous innervation to the skin of the scrotum, or labium majora via the

scrotal and labial branches, respectively, the root of the penis, mons pubis, and the adjacent medial aspect of the thigh. It supplies motor innervation to the internal oblique and transverse abdominal muscles.

Iliohypogastric Nerve

The iliohypogastric nerve arises from the ventral ramus of L1. Anatomically, it runs through the transverse abdominal muscle, while its branches pierce the external oblique aponeurosis (along with the ilioinguinal nerve), running deep to the internal oblique. It enters the abdomen posterior to the medial arcuate ligaments and passes inferior laterally, anterior to the quadratus lumborum and runs parallel along the iliac crest. The ilioinguinal nerve supplies the skin of the hypogastric region superior to the pubis, the superolateral quadrant of the buttock via the lateral cutaneous branch and over the iliac crest supplying motor innervation to the internal oblique and transverse abdominal muscles. This function overlaps that of the ilioinguinal nerve.

NONIMPLANTABLE THERAPIES FOR CPP

Typically, patients with CPP seek care with a pain management specialist very late in their treatment continuum. This is likely due to the fact that they are being treated by their primary care physician and/or specialists in obstetrics, gynecology, or urology. Only when their treatment fails are patients usually referred to pain management specialists. Due to differences in philosophy and preferred treatment methods, these physicians will typically spend months to years attempting to look for a specific cause (i.e., infection or structural abnormality) and attempt to treat the symptoms with multiple medications (i.e., antibiotics, anticonvulsants, and opioids). When such approaches fail, patients are left without effective treatment for a substantial period of time and their pain may worsen.

While there are many potentially effective treatments and/or procedures aimed at treating CPP, there is no clear “gold-standard” for its many variants. Some widely used treatments include:

Physical Therapy (PT)

As with most chronic pain syndromes, PT can offer some therapeutic effect. When offered in conjunction with interventional pain treatments to provide a multimodal approach, in the case of CPP, it has been shown to provide significant benefit (15,16). Given the prevalence of psychosocial components in CPP, the ad-

dition of cognitive behavioral therapy can add to a multidisciplinary treatment option (17). Exercises typically focus on pelvic floor muscle relaxation, ultrasound, and stretching.

Trigger Point Injections and Botox Injections

In cases where CPP is related to tender or tight muscles, simple injections or needling in the form of trigger point injections may offer some relief (18). In cases of spasticity, injections of botulinum toxin to the muscles of the pelvic floor have shown to significantly improve dyschezia and dyspareunia (19).

Superior Hypogastric Block

This procedure is used as both a diagnostic and therapeutic tool. Under radiographic guidance, a thin needle is inserted through the skin and advanced toward the L5 vertebra, the location of the superior hypogastric plexus. A blockade of the superior hypogastric plexus has been reported to decrease pelvic pain associated with malignancy by 70% (20). While this block has not been well documented in nonmalignant CPP, Rosenberg et al (21) reported that the block successfully treated severe chronic penile pain after transurethral resection of the prostate.

Ganglion of Impar Block

Like the superior hypogastric block, this procedure can also be used for both diagnostic and therapeutic purposes. This procedure is performed under radiographic guidance with the target being a small area directly in front of the coccyx. The ganglion of impar provides nociceptive and sympathetic innervation to the perineal region and its blockade can be beneficial in providing relief for rectal, anal, perineal, and genital pain (22). This injection may be extremely effective in treating pain originating from the cervix, colon, bladder, rectum, and endometrium. Studies have reported 70–100% pain relief from this procedure (6).

Peripheral Nerve Blocks

Like many types of pain, a peripheral nerve block can be extremely effective in treating CPP pain. There are an abundance of nerves providing innervation to the pelvic region and its organs, any of which can be targeted and blocked with a small amount of local anesthetic to potentially provide pain relief. In the case of PN, a pudendal nerve block is considered to be the first line approach for both establishing the diagnosis and managing the symptoms of PN.

Neurolysis and Ablation

In many cases, an injection or block will provide only temporary relief. In cases such as these, neurolysis or neuroablation can be utilized to provide longer relief. There are several different techniques that can be utilized:

Chemodeneration

Small amounts of either alcohol or phenol can be injected onto a target area thus blocking the nociceptive pathways through destruction of neural tissue. This can be performed on the ganglion of impar and the superior hypogastric plexus with less concern than if it were a mixed peripheral nerve due to the lack of cutaneous innervation and/or motor fibers (20,23). There is less risk for neuroma formation with this modality than surgical denervation or radiofrequency ablation (RFA) due to preservation of the neural sheath (12,24,25).

Pulsed Radiofrequency Ablation (PRFA)

PRFA is a nondestructive variant of conventional or thermal RFA for providing long-term pain relief (26). It is not temperature dependent and the cannula tip rarely exceeds 42° to 45°C. This is particularly important when considering using neurolysis on a peripheral nerve known to contain motor fibers as PRFA can be used to ablate pain pathways with a certain degree of safety. Similar to conventional RFA, cannulas are positioned adjacent to the presumed pain-transmitting nerve(s). As it pertains to CPP, PRFA has recently been shown in many cases to be a promising option for a variety of pelvic pain syndromes, including PN and orchalgia (27-31).

Even in cases where the above procedures fail to provide pain relief, one can ascertain a great deal of information about the pain generator and the route of conveyance of pain information to the central nervous system. For example, a patient presented with what

appeared to be PN, but failed to get any relief from a pudendal nerve block. The patient, however, obtained transient, yet incomplete, relief from a ganglion of impar block. The area of pain that was left unaffected by the impar block was a small patch bilaterally that resembled the sensory territory of the genitofemoral nerve (L1-L2). If one were to attempt to place a trial lead over the pudendal nerve only or in the sacral spinal canal, the patient would potentially fail due to lack of coverage of genitofemoral nerve territory.

NEUROSTIMULATION THERAPIES FOR CPP

There is no consensus as to the optimal target or location for neurostimulation for the treatment of CPP. A wide variety of neurostimulation targets for CPP, the rationale for their use, techniques for delivery of the therapies, and their relative strengths and weaknesses are presented in Tables 4 and 5 and discussed below.

Pudendal Nerve Stimulation

PN is a particularly painful CPP syndrome and is often refractory to conventional therapies. It involves neuropathic symptoms in the distribution of the pudendal nerve, comprised of fibers from S2 through S4, and is most common after childbirth, pelvic trauma, and surgical injury in women. In men, pelvic trauma is the most common cause. It is formally diagnosed using the Nantes Criteria (2008) and characterized by pain in the pudendal nerve distribution associated with no objective sensory loss; the pain is worsened with sitting, but does not wake the patient up at night (32). PN is relieved, at least temporarily and sometimes incompletely, with pudendal nerve blockade.

CPP that is refractory to conservative care has been shown to respond well to sacral nerve root stimulation (33,34). Between 10–25% of patients with PN, however, do not respond to sacral nerve stimulation and pudendal nerve stimulation is a potentially efficacious

Table 4. Various techniques for placing leads in the sacral canal.

Approach	Description
Retrograde Technique	Cephalocaudal lead placement
Anterograde Trans-hiatus Technique	Caudally placed needle with leads advanced anterograde into sacral canal
Transforaminal Technique (36)	Typically through S3 for placement of InterStim®
Epidural technique with laminotomy (92)	Retrograde paddle placement via laminotomy at L5/S1
Percutaneous Cephalocaudal/Retrograde Peripheral Nerve Stimulation (36,51)	Lead placed retrograde over the dorsal sacral foramina

Table 5. Pros and cons of anterograde vs. retrograde techniques.

Technique	Advantages	Disadvantages
Retrograde (Cephalocaudal)	Steerability comparable to traditional dorsal column lead placement Securing lead during trial same as a traditional trial Tunneling lead and anchoring same as in traditional implant Lower migration risk Decreased dehiscence risk with implant Away from painful pelvic region/coccyx	Technically more challenging Increased risk of dural puncture Increased risk of intrathecal lead placement
Anterograde Trans-Hiatus	Technically less challenging procedure – same as a caudal epidural injection Decreased risk of dural puncture or intrathecal lead placement Shorter distance to steer leads	Increased risk of infection during trial due to proximity of lead to rectum Increased difficulty in securing lead trial and maintaining site integrity during trial due to location in the intergluteal cleft Increased challenge with anchoring due to lack of tissue surrounding hiatus Lead tunneling is more challenging due to increased distance and having to navigate around the buttock Increased risk of skin erosion due to proximity of implanted leads to skin Limited steerability of leads

alternative (35). Not only does PN respond to pudendal nerve stimulation, but significant responses have been reported in patients with interstitial cystitis and painful bladder syndrome (32,36,37).

The technique of pudendal nerve stimulation takes advantage of the consistent course of the pudendal nerve. The pudendal nerve passes out of the intrapiriform foramen, dorsally around the ischial spine, and then out of the lesser sciatic notch before leaving Adcock’s canal (also known as the pudendal canal). This predictable course makes it amenable to fluoroscopic techniques of localization. To ensure accurate localization with the electrode, the addition of electrophysiologic testing allows precise placement. Schmidt et al (38) first described techniques for fluoroscopic landmarks of the pudendal nerve. Subsequently, Spinelli and coworkers modified this technique to use the greater trochanter and ischial tuberosity as fluoroscopic landmarks for the pudendal nerve (39). An alternative approach was described using fluoroscopic identification of the ischial tuberosity to aid in lead placement (40). In 2010, Bock et al (41) proposed a nonfluoroscopic modification of the Spinelli technique using the gloved index finger with an attached electrode inside the rectum to allow confirm lead placement for the treatment of fecal incontinence.

Most recently, Heinze et al (42) proposed the STAR technique (S-ischial spine, T-ischial tuberosity, A-

acetabulum, R-anal rim) to localize the pudendal nerve via fixed fluoroscopic landmarks that also takes into account individual patient anatomy (Fig. 4). Patients are placed in the prone position with elevation of the ipsilateral buttock to approximately 40 degrees. Using the junction of lines drawn from the mid-acetabulum, the ischial tuberosity, and the anal rim to the ischial spine, the starting point for needle entry is determined. The needle is then advanced toward the pudendal nerve at the level of the ischial spine using intermittent fluoroscopic guidance (42).

The Peters, Spinelli, and STAR techniques all utilize electrophysiologic recording to confirm placement near the pudendal nerve. They recommend pudendal nerve terminal motor latency (PNTML) stimulation to obtain the compound motor action potential (CMAP) of the anal sphincter. A PNTML less than 2.5 ms and stimulation amplitude of greater than 5 mA are considered adequate localization of the pudendal nerve and acceptable proximity to it for stimulation (32,43,44).

Heinze et al (42) performed a comparison of the Peters, Spinelli, Bock, and STAR techniques for pudendal nerve stimulation electrode placement in 20 CPP patients with PN diagnosed by the Nantes Criteria. While all 4 techniques demonstrated appropriate placement of the electrodes, the STAR technique was notable for a fewer average number of punctures (3.5 vs. 8, 15, or 22 punctures) and a decreased mean time to place a single

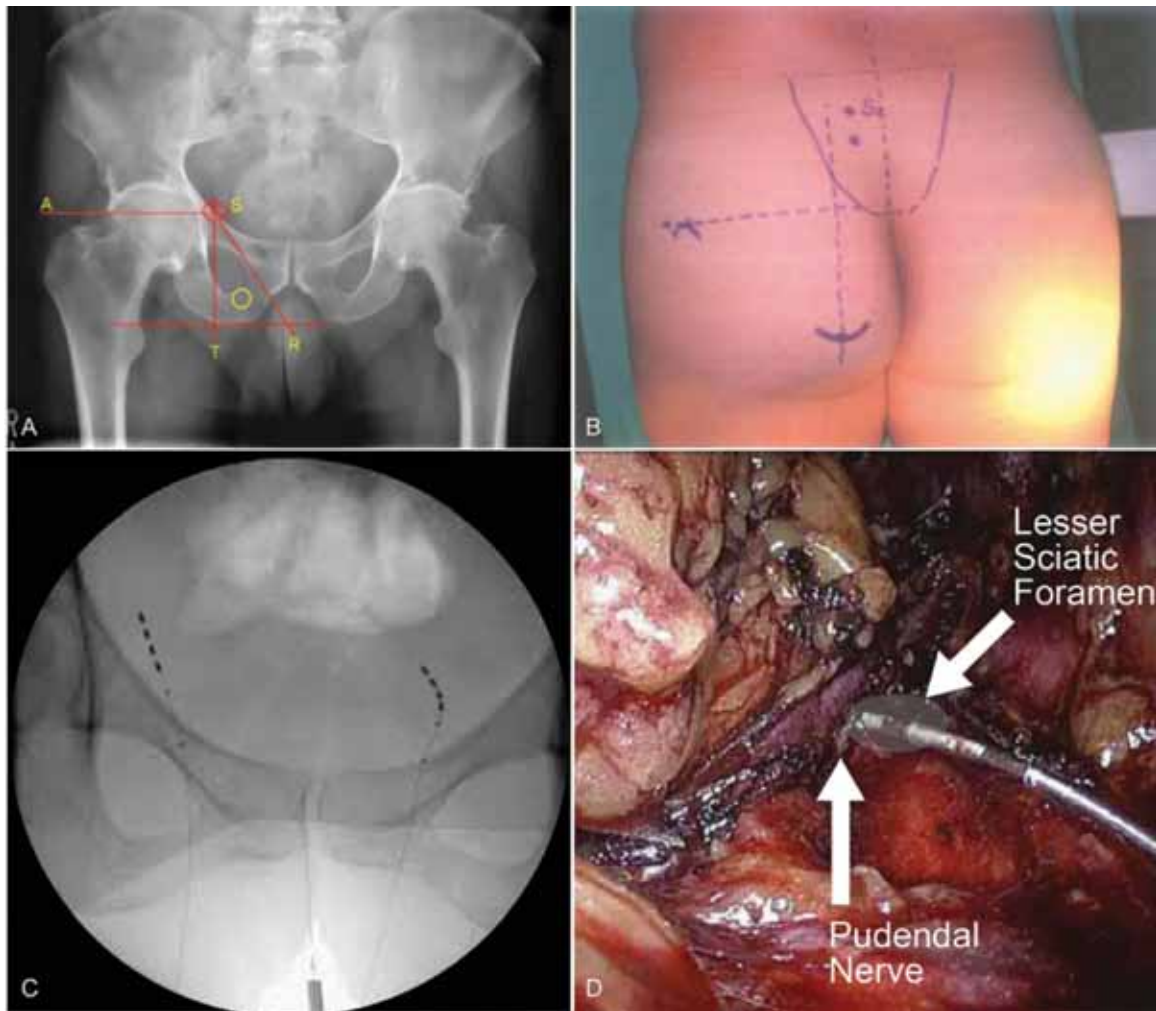


Fig. 4. STAR Technique for pudendal nerve stimulation under fluoroscopic guidance using anatomical landmarks(42): A) A=horizontal line crossing middle of acetabulum, T=vertical line crossing middle of ischial tuberosity caudally, S=junction of where A and T meet, pinpoints the ischial spine, a second horizontal line is drawn parallel to A touching bottom of ischial tuberosity, R=anal rim on the skin side, center of triangle is pudendal nerve; B) Landmarks drawn out preoperatively; C) Fluoroscopic image of leads positioned adjacent to pudendal nerves using STAR technique; D) Internal view of lead in actual position
 Pictures reproduced with permission from Heinze et al, World Journal of Urology-2015(42)

electrode (25 min vs. 31, 51, or 98 minutes). Both the Bock and STAR techniques allowed for significantly less time during implantation of the stimulation systems. While all of the techniques were successful for unilateral placement, only the STAR and Bock techniques resulted in successful bilateral electrode placements (41,42).

Sacral Nerve Stimulation

While the use of sacral stimulation for CPP is largely in its infancy, most of the earliest publications on SCS for pelvic pain focused on the sacral nerves as potential targets. It has been used predominantly for nonpain indications including overactive bladder and fecal incontinence. Uludag et al (45) and Steinberg et al (36)

described neuromodulation of the sacral nerves for fecal incontinence to be of benefit. In a multicenter study, patients with urge incontinence, urgency-frequency and retention, demonstrated 50% symptomatic relief (46). In a second multicenter study, however, Dijkema et al (47) demonstrated a high rate of patient dissatisfaction with sacral stimulation for urge incontinence.

In cases where the predominance of innervation is sacral (i.e., PN, vulvodynia, genital pain), stimulating the sacral nerve roots makes the most intuitive sense. As these fibers are present throughout the length of the spinal cord, they could theoretically be stimulated anywhere along their course. Unfortunately, they are notoriously difficult to recruit with traditional SCS due to their size and position. By the time the sacral fibers reach the thoracic spinal cord, they are smaller than the lumbar fibers which have just entered the dorsal columns. Thus, they require more energy to stimulate. As the amplitude and/or pulse width are increased to recruit these fibers, other lumbar fibers will be stimulated producing extraneous, stronger, and unwanted paresthesias. In addition, the representation of the S2 through S4 in the dorsal column is much smaller than that of the adjacent S1 nerve root, reflecting the size of the nerve roots entering the spinal cord. Thus, stimulation of an intensity sufficient to recruit the S2 through S4 fibers is likely to first recruit the S1 fibers.

Despite this, sacral neurostimulation has shown some success in treating generalized CPP, interstitial cystitis, vulvodynia, and PN, although further higher-powered studies are needed. The current evidence is primarily comprised of low-level case reports (32,48-50). Treatment of coccygodynia with sacral lead placement at the lower sacral levels has shown satisfactory results

(51,52). Treatment for refractory sacroiliac joint pain was demonstrated with up to 80% pain relief after 16 months as described by Kim and Moon in a case report showing the benefits of sacral stimulation (53). Yakovlev et al (54) described meaningful pain relief when the sacral region was stimulated for refractory axial low back pain secondary to lumbar post-laminectomy syndrome when traditional SCS had failed. Table 6 summarizes the likely sacral target(s) for stimulation based on the given pain syndromes as described in the literature.

Intraspinal Retrograde (Cephalocaudal) Technique for Sacral Stimulation

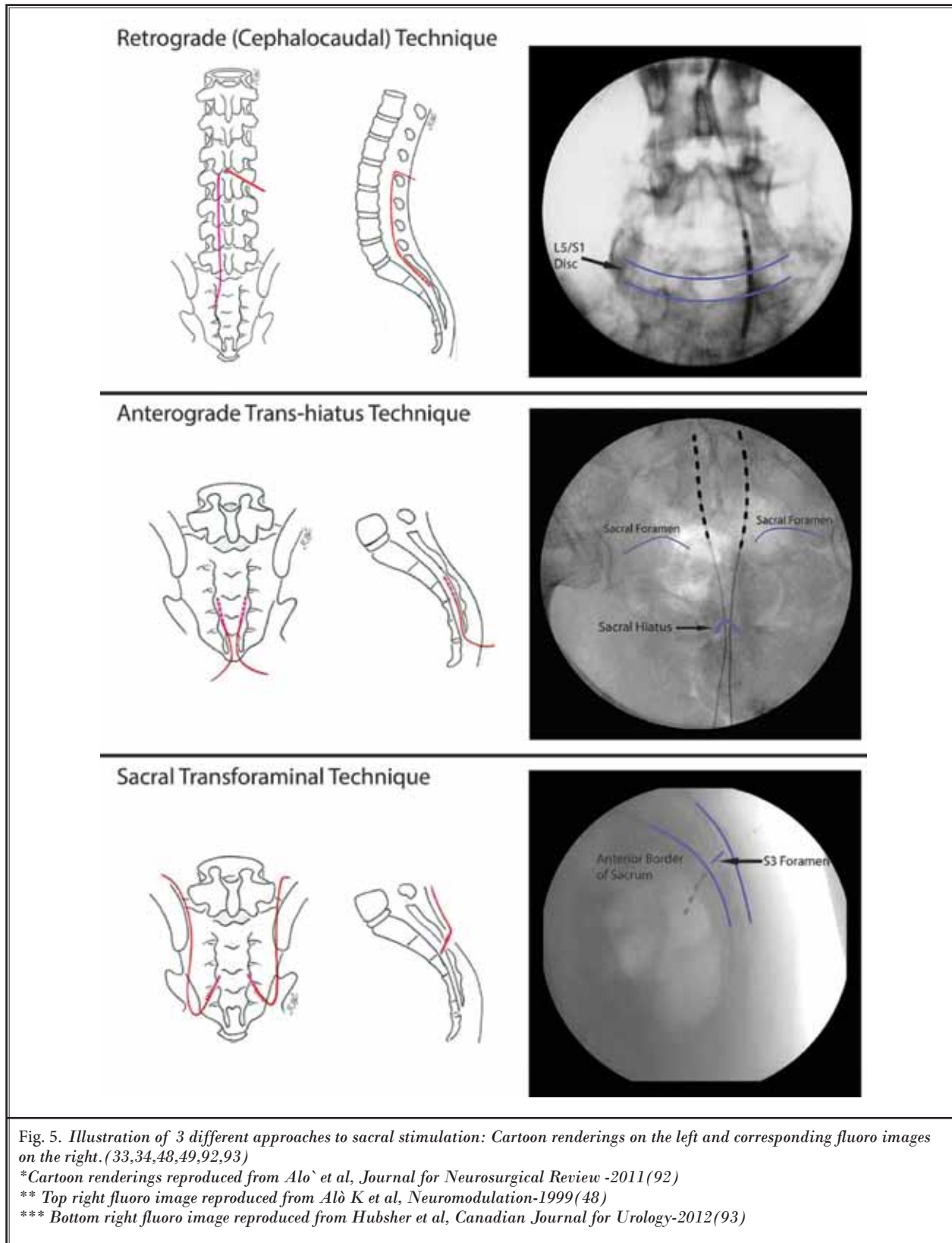
Despite its greater technical complexity and the increased risk of dural puncture and cerebrospinal fluid (CSF) leak, the retrograde approach tends to be most often used by interventional pain physicians (35). The needle angle and approach required for the lead to enter the epidural space in reverse is an obvious departure from a conventional anterograde lead. This difference carries a substantial increase incidence of dural puncture as well as the subsequent possibility of intrathecal lead placement. Aló described a novel technique for placing the needle whereby a lateral approach is taken into the epidural space to decrease the risk of dural puncture (34,40) (Figs. 5 and 6) .

Anterograde Trans-Hiatus Technique for Sacral Stimulation

The anterograde approach is fundamentally easier than the retrograde procedure as it pertains to needle placement and access to the epidural space. As with a caudal epidural injection, a needle is placed through the sacral hiatus under fluoroscopic guidance (34).

Table 6. *Condition-dependent sacral targets for SCS.*

Conditions	Sacral Targets
Sacroiliac Joint Pain (53)	S1
Post-laminectomy syndrome with failed traditional SCS (50)	S1, S2, S3, S4
Urgency-Frequency Disorders	S2/3
Interstitial Cystitis (32,34,36,48-50)	S2, S3 (S4)
PN(32,48,49,50)	S2, S3 (S4)
Vulvodynia (32,48-50)	S2, S3 (S4-S5)
Urge Incontinence (46)	S3
Fecal Incontinence (41,45)	S4
Coccydynia (51,52)	S4 & S5



With this procedure, there is little to no risk of dural puncture unless the needle is advanced several centimeters beyond the hiatus and into the spinal canal. Once the leads emerge from the needle(s) into the sacral canal, they need only to be advanced a short distance to the target (Figs. 5 and 6). Unfortunately, this technique is not without drawbacks. There is a paucity of subcutaneous tissue over the sacral hiatus, making it difficult to secure the lead and increasing the likelihood of skin erosion. Table 5 compares the retrograde to the anterograde approach.

Sacral Transforaminal Neuromodulation

Another approach to sacral nerve stimulation is via the sacral foramen (31). The only currently available method for transforaminal sacral nerve access is the InterStim Neurostimulator (Medtronic), although 2 additional companies have sacral nerve stimulation devices at different points in the approval process (Axonics, Inc., NuVectra, Inc.). The InterStim system is currently approved by the Food and Drug Administration (FDA) only for the treatment of overactive bladder, urinary retention, and chronic fecal incontinence (55). However, it has been used off label to treat refractory CPP, painful interstitial cystitis, and PN with durable success at 12 months (29,37,56).

Sacral nerve root targets may vary when using the InterStim system depending on the disease process being treated (Fig. 5). For example, in cases of PN, the bilateral S3 and S4 nerves roots may be targeted (35), whereas patients with more diffuse pain (i.e., interstitial cystitis, CPP or painful bladder syndrome), may be success-

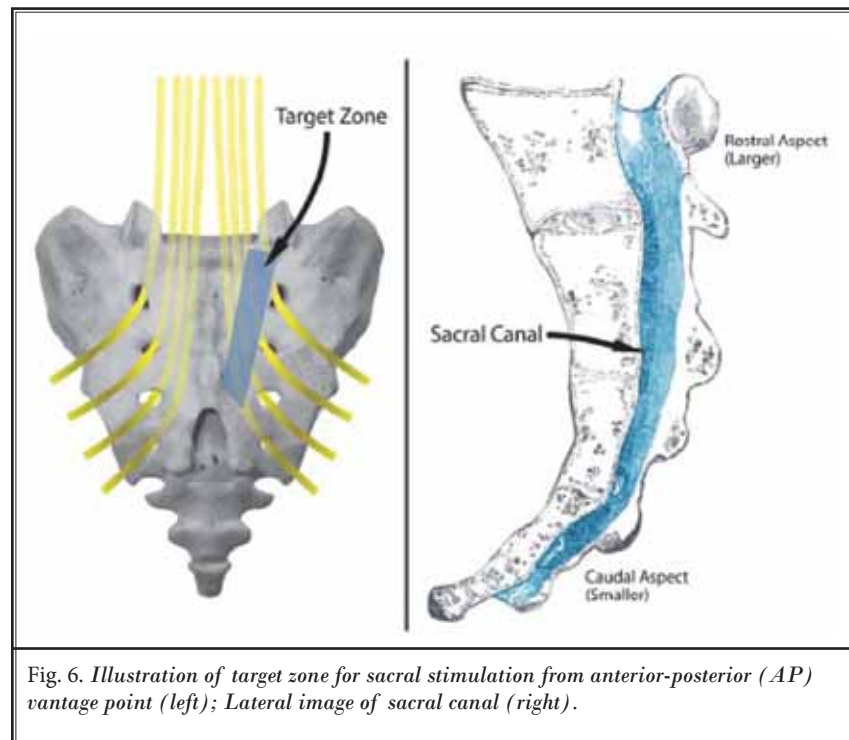


Fig. 6. Illustration of target zone for sacral stimulation from anterior-posterior (AP) vantage point (left); Lateral image of sacral canal (right).

fully treated with bilateral S3 stimulation alone (42,57). As with most uses of neurostimulation, the location of symptoms will guide the targeting for both trial and implantation, however, bilateral S3 stimulation appears to be the most consistent target for CPP (35).

The differences between methods of sacral nerve access for neuromodulation should also be noted. As described above, the retrograde approach, while effective, carries an increased risk of dural puncture (35,52). Compared to the retrograde approach, transforaminal access to the sacral nerves carries an advantage in that there is less inherent risk to the dura simply from the trajectory taken. And when compared to access via the sacral hiatus, the transforaminal approach has the added benefit of less risk of skin breakdown due to the presence of more tissue over the buttock as compared to the intergluteal cleft. The one disadvantage with the transforaminal approach, however, there is the increased potential for lead migration (32).

Tined leads have been developed to address the risk of migration with sacral nerve stimulation leads. This and the use of a permanent lead that is tunneled at the time of trial has successfully reduced lead migration and improved trial results (44,49). Prior to the development of tined leads, the lead was anchored directly to the sacrum in an attempt to decrease the high rate of trial lead. While transforaminal stimulation with the Interstim System is not FDA approved for CPP, its off label use provides another route for sacral nerve root modulation with some documented successes.

The mechanism of action for pain reduction with the stimulation of mixed sacral nerves is poorly understood, however urologic research suggests that afferent inhibition of sensory processing in the spinal cord plays a prominent role (58). The efferent action of involved motor nerves during

stimulation, however, is thought to play less of a role in the symptomatic relief of bladder dysfunction (59).

Conus Medullaris Stimulation

The conus medullaris is the tapered caudal termination of the spinal cord. In the adult population, the conus is located between the mid-T12 vertebral level to the upper third of L3 with the average location at the lower third of L1 (60). Exiting the conus is a large group of nerve roots collectively called the cauda equina. The lumbar and sacral nerves of the caudal equina innervate the pelvic organs and pelvic floor, the urinary and anal sphincters, as well as carrying sensory innervation from the pelvis. Of course, the lumbar somatic motor and sensory fibers are also included in the cauda equina. The sympathetic fibers innervating the pelvis originate from T11 to L2. This would suggest the conus and cauda equina as ideal targets for SCS/peripheral nerve stimulation in patients with CPP.

Published reports of neurostimulation of the conus date as far back as 1970 when authors first described electrode implantation in paraplegic patients which enabled self-controlled emptying of the bladder (61). In addition to induced electrical contraction of the bladder, increased autonomic activity below the level of the spinal cord transection, improved defecation, reduction of lower extremity spasticity, and penile

erection were observed. More recently, Hunter et al {Reference needed} reported on a CPP patient whose pain was reduced by over 50% with lead placement over the conus. A subsequent case series demonstrated substantially decreased pain scores and opioid requirements in 6 patients with pelvic pain following conus medullaris stimulation (62). Conus stimulation has also been effective for treating PN (63). There are further case reports of the successful treatment of CPP using dorsal root entry zone lesions at the level of the conus medullaris (64). While the DREZ procedure is a neuroablative, rather than neurostimulatory procedure, these cases demonstrate the importance of the conus as an important potential target for treating CPP.

While stimulation of the conus has been shown to be effective in the treatment of CPP, it is not without its drawbacks (Fig. 7). Compared to other locations more cephalad in the spinal column, the distance between the epidural electrode and the conus is greater due to the natural tapering of the conus. The greater this distance, and thus the more CSF between the electrode and its conus medullaris target, the more energy required to activate the dorsal column fibers (65). Even more significant is the constant movement of the conus medullaris and the cauda equina within the CSF. In their MRI {sp} study, Ranger et al (66) demonstrated that the conus could deviate, on average, by 6.3 mm

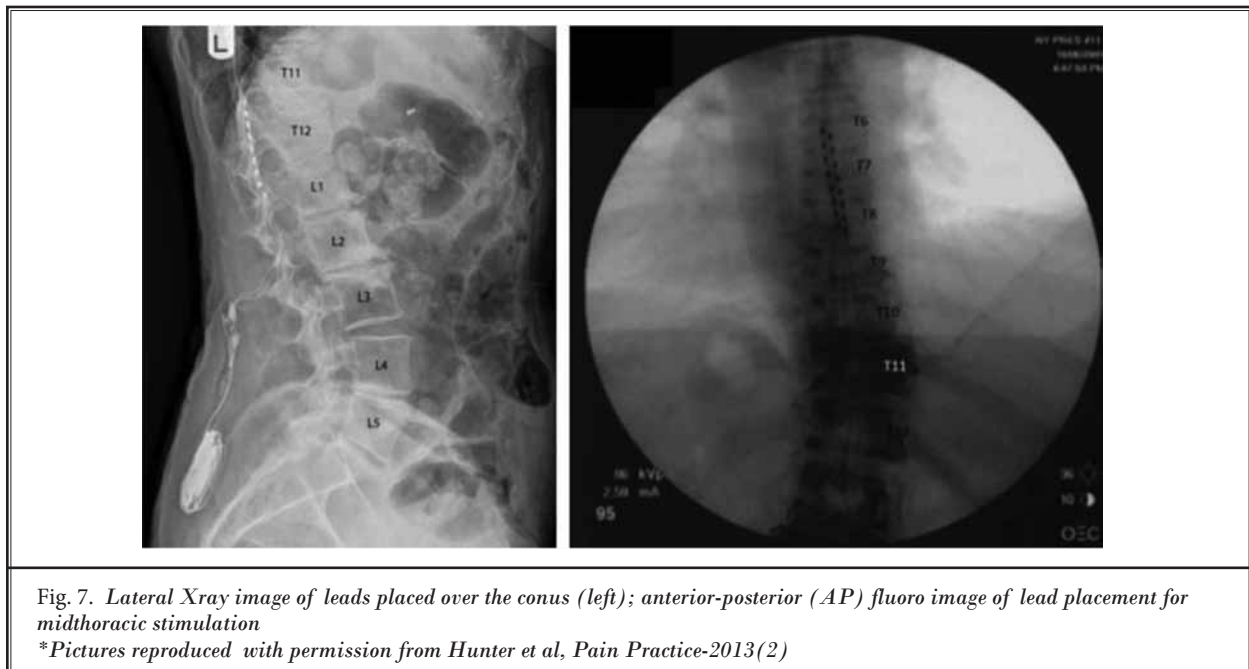


Fig. 7. Lateral Xray image of leads placed over the conus (left); anterior-posterior (AP) fluoro image of lead placement for midthoracic stimulation

*Pictures reproduced with permission from Hunter et al, Pain Practice-2013(2)

anteriorly during hip flexion and 1.6 mm when moving from the supine to the lateral position. This movement of the conus relative to the electrode creates difficulty maintaining consistent coverage and stable stimulation intensity. Fettes et al (67), however, also using MRI, determined that the range of movement for the conus was anywhere from 4 mm caudad to 1 mm cephalad with half of the patients moving cephalic and the other half moving caudad. Regardless of the degree of movement, clinical experience confirms that the unstable relationship between the stimulating electrode and the conus medullaris and cauda equina can result in both changes in paresthetic distribution and intensity.

Dorsal Root Ganglion Stimulation

In 2016, the FDA granted approval for dorsal root ganglion (DRG) stimulation via the Axiom™ System (Abbott) for the treatment of lower extremity CRPS Types I and II. The DRG presents an interesting target for the treatment of chronic pain, as evidence suggests it is directly involved in the development of NP. Following peripheral nerve injury, a cascade of injury triggered events occurs, resulting in hyperexcitability (68) and spontaneous, ectopic firing (69) of the upstream cell bodies within the DRG. This then may lead to central sensitization and the clinical phenomenon of allodynia (70).

In 2014, Liem et al (71) reported on the 1-year outcomes of 34 patients implanted with DRG stimulation; of which 8 were diagnosed with CRPS. The authors went on to report an overall reduction in pain of 56% with 60% of patients reporting greater than 50% improvement in pain. Of note, the patient reported excellent coverage of their pain that remained stable throughout. Later that year, van Bussell presented a case report of a patient with CRPS of the knee successfully treated with DRG stimulation (72). The author reported the patient had complete coverage of the painful area with a reduction in pain averaging around 77% at 3 months post-implant.

In the largest trial of its kind, DRG stimulation was demonstrated to be superior to SCS for the treatment of chronic pain associated with CRPS Types I and II. In this prospective, randomized controlled trial, 93% of DRG stimulated patients had 50% or more pain relief 3 months after device implantation; and 70% of DRG stimulated patients had greater than 80% pain relief at one year (73). As CPP is considered by some to be a form of CRPS, there is significant potential for DRG stimulation as a treatment for CPP.

The development of DRG stimulation creates an interesting option for treating CPP. DRG offers the potential geographic pain coverage and stability of the 4 other targets of spinal or peripheral nerve stimulation (pudendal nerve, sacral nerve, conus medullaris, and thoracic spinal cord) currently used for the treatment of CPP. DRG stimulation allows for directness of pudendal nerve and conus medullaris stimulation with the broad regional coverage of sacral nerve stimulation while preserving the consistent coverage and decreased migration of conventional mid-thoracic dorsal column SCS. Of additional benefit is the lack of positional changes with DRG stimulation due to the location of the DRG lead immediately over its target and the paucity of CSF over the DRG. As a further result, DRG stimulation is remarkably efficient, with power requirements of only 5% of that needed for SCS.

The recently approved DRG stimulation system allows for precise lead placement, which allows for stimulation involving the territories of pelvic nerves including the pudendal, ilioinguinal, and iliohypogastric nerves. In that there is investment of the DRG cell bodies with fibers of the sympathetic nervous system, DRG stimulation also alters sympathetic outflow and as such may be particularly effective in potentially sympathetically mediated pain syndromes such as CPP. In 2017, Hunter et al reported on the results of a large, multi-center registry researching the efficacy of DRG stimulation - 13 different diagnoses were studied, one of which was CPP. In this registry, 6 patients with CPP were treated with DRG stimulation, reporting an average of 76.7% reduction in pain and a 5.67 reduction on the Numeric Rating Scale (NRS). Additionally, the authors reported consistent success with CPP by simultaneously targeting bilateral L1 and S2 DRGs (74).

Dorsal Column SCS

Challenges of SCS for CPP

The first critical decision when attempting to use SCS for the treatment of chronic pain involves correctly identifying the appropriate region of the spinal cord to target. For most chronic pain syndromes, barring variation in regional anatomy, this is relatively straightforward (i.e., leg pain treated with T10-T11 SCS). For CPP, however, there is no consensus as to optimal SCS lead placement and, in fact, paresthetic coverage of the appropriate pelvic region is quite difficult. As discussed, regions with innervation from T12 and L1 lie immediately adjacent to those innervated by sacral nerve roots.

Therefore, one may well achieve paresthetic coverage of some of the pain area and yet leave an adjacent region untreated. In other instances, one may get complete pain coverage by increasing the intensity or pulse width of stimulation, however this may lead to uncomfortable paresthesias in unaffected areas.

Thus, the pelvic viscera draws innervation from both the lumbar and sacral regions making it difficult to capture all areas of pain simultaneously. In addition, the visceral pain fibers are thought to travel within the corresponding sympathetic nerves of the region or organ in question. The cell bodies of these pain fibers are located in the thoracolumbar ganglia with their projections into the spinal cord located between T2 and L2. This pattern of innervation could potentially explain why those with sympathetically-maintained pain in the pelvic region are inconsistently responsive to conventional blocks targeting the ganglion of impar or hypogastric plexus. Perhaps this is why a lead placed in the sacral canal could leave a significant portion of relevant fibers unstimulated. Therefore, one could create paresthesias over the appropriate area and even capture a good amount of the visceral and sympathetic fibers, but still leave enough of those still unstimulated, thus leaving the patient with incomplete relief.

Targeting of conventional SCS, as noted above, is a challenge in the setting of CPP. The dermatomal distribution of the pelvic region is problematic for neuromodulation in that there are areas within the pelvic/perineal region where T12 and L1-derived nerves are immediately adjacent to sacrally-derived nerves. Therefore, if both sacral and thoracolumbar fibers are not both targeted, the patient runs the risk of incomplete pain coverage and a failed trial. Approaches to ameliorate this problem include stimulation of multiple targets with multiple leads or, if possible, stimulation of a specific region of the spinal cord where as many as possible relevant fibers are adjacent to one another.

In 2010, Kapural et al {Need reference number} demonstrated successful treatment of abdominal pain with SCS. Thirty-five patients with diagnoses including pancreatitis, adhesions, post-gastric surgery syndrome, and mesenteric ischemia were all implanted with SCS systems (2). SCS leads were placed at T5-T6 for epigastric pain and T11-L1 for lower pelvic pain. In addition to significant pain relief with stimulation of these unconventional SCS targets, the authors reported decreased opioid consumption in these patients.

Soon thereafter, Hunter and coworkers reported similar patterns of pain relief in 4 patients using mid-thoracic SCS lead placement (Fig. 7) (2). Four CPP patients with differing pain presentations in the pelvic/perineal regions were successfully treated with SCS leads placed at T6 and T7. The authors theorized that by advancing the leads more cephalad than in the past, the stimulation provided coverage of the visceral and/or sympathetic fibers that otherwise would have been missed with traditional, more caudal placement. Given that sympathetic nerves cell bodies appear in the intermediolateral cell columns from T1 to L2 (43), this may be another reason a more cephalad placed lead appears to be more beneficial. In addition, in that sacral fibers run more medially within the dorsal column, midline stimulation of mid-thoracic cord should theoretically provide better coverage of pelvic pain than more lateral placements.

While most human studies examine the effect of SCS on somatic NP, animal studies have shown that SCS can decrease the visceromotor response to stimuli in rats. In 2003, Greenwood-Van Meerveld demonstrated that SCS could attenuate the nociceptive visceromotor reflex created by colorectal distension in rats (75). Subsequent case reports of abdominal pain modulation in humans using SCS have appeared (76-78). One case series presented 6 patients with chronic intractable visceral pelvic pain treated successfully with SCS; most leads were placed with their rostral tip at T11-T12 (62).

Novel Waveforms and Pulse Trains

In recent years, engineers introduced the concept of altering the conventional lower frequency tonic waveforms in an effort to increase efficacy with dorsal column SCS. In doing so, Burst (Abbott) (79), and High Frequency (10 kHz/Nevro) (80,81) were introduced. Both therapies were shown to be superior to traditional SCS modalities in the treatment of back and/or leg pain. As both are relatively recent innovations at time of this publication, literature on new indications is sparse. While there are none available specifically on CPP, there are several on CRPS. Burke et al (82) published the findings of a case report on a patient with CRPS successfully treated with Burst stimulation with follow-up at 2-years post implantation. Similarly, there is a case report published on the successful use of High Frequency stimulation for the treatment of CRPS (83). Both Burst and High Frequency stimulation may offer improved results with CPP, however more data is required to make an informed recommendation.

INTRATHECAL DRUG ADMINISTRATION FOR CPP

Even in straightforward cases of chronic, radicular low back pain, CRPS or failed back surgery syndrome (FBSS), neurostimulation procedures may fail. Typically, it is at this point that neuromodulators will begin to entertain intrathecal pharmacotherapy via an implantable pump and intrathecal catheter. Intrathecal therapies have been used to treat a variety of refractory painful conditions and there is now Level 1 evidence for the use of intrathecal ziconotide to treat nociceptive and neuropathic painful conditions (84). Its effect on reducing central sensitization is thought to be through presynaptic N-type voltage-gated calcium channel blockade acting to reduce primary afferent input to the dorsal horn through presynaptic inhibition of neurotransmitter release (glutamate, CGRP [sp], and substance P) (85,86). Intrathecal drug delivery (IDD) has an advantage in that delivery of drug into the CSF results in nonspecific, relatively broad distribution of the drug and its therapeutic effect as opposed to the very specific targeting that is required to get pain relief from SCS and most other neurostimulation techniques.

As previously discussed, CPP may be a form of CRPS as evidenced by findings in patients with interstitial cystitis and nerve injury (2-5,17). In 2009, Kapural et al (87) presented a case series evaluating the use of ziconotide for highly refractory CRPS. The authors reported substantial improvements in pain, highlighting the potential role of ziconotide in the setting of CRPS and potentially CPP. In light of the limited literature on the use of intrathecal ziconotide to treat CRPS or CPP, optimal catheter tip placement and dosing has not yet been established. While ziconotide has a much more favorable side effect profile as compared to intrathecal morphine (50,65,88-90), close monitoring of adverse events is paramount during dose titration of ziconotide (91).

The placement of IDD in the treatment algorithm of CPP has yet to be established. With the recent highly positive trial of DRG stimulation for lower extremity CRPS, DRG stimulation should be placed early in this treatment algorithm. With the current level of evidence supporting the use of SCS in the treatment of CRPS in the extremities, it should be considered early on as well. Given the many potential challenges of targeting CPP with SCS, however, intrathecal delivery of ziconotide presents an obvious advantage that should demand an earlier consideration for the treatment of CPP.

DISCUSSION

CPP is often difficult to diagnose and patients frequently spend a long time undergoing ineffective treatments for incorrect diagnoses by well meaning, but uninformed generalists and specialists outside the specialty of pain medicine. Until education about these conditions becomes more widespread or clear diagnostic criteria are established to identify these patients earlier, they will continue to be referred for pain management late in the course of their illness, often having received antibiotics for suspected infections, cycling through antidepressant medications due to misdiagnosed depression and/or anxiety, or having unnecessary surgeries such as hysterectomy (2). Typically, it is not until these patients are unsuccessfully treated by 2 or more specialists that they enter the purview of pain management; however, by this point, their disease is well into a more chronic stage and much more difficult to treat. With this much time having lapsed, hypersensitization and ectopic firing of the DRG cells and central sensitization have already occurred; as such most conventional treatments are rendered essentially worthless.

More often than not, CPP patients will be seeking treatment from a pain management doctor at a point where neuromodulation may be the only potentially effective therapy. While nonneuromodulatory therapies such as PT, nerve blocks, and radiofrequency lesions may be helpful early in the course of CPP, they are rarely curative, especially in patients with later stage disease.

While there is no consensus as to the optimal targeting of neurostimulation for the treatment of CPP, there are a variety of neuromodulation techniques with varying levels of evidence for efficacy in CRPS and CPP (Table 7). Historically, SCS or IDD have been reported to be minimally effective and associated with high failure and explant rates. It is important to recognize that both SCS and IDD have evolved significantly over the past decade and that novel pulse trains, such as Burst (82) and high frequency stimulation (80,81), have significantly improved the outcomes of SCS and the use of intrathecal ziconotide (91) has revolutionized IDD. Furthermore, entirely novel techniques, such as DRG stimulation (73), present a significant opportunity for helping patients afflicted with CPP.

While unlike many spinal disorders where MRI can clearly demonstrate the causative pathology, there is no diagnostic imaging that demonstrates the cause of

Table 7. Comparison of neuromodulation techniques for treating CPP.

	Pro	Con
Sacral	Retrograde approach – aside from increased challenge with needle placement, remainder of procedure is nearly identical to traditional SCS Anterograde approach – easy needle placement, decreased risk of dural puncture	Retrograde approach – high incidence of dural puncture and intrathecal lead placement Anterograde approach – difficult to anchor, high incidence of skin erosion
Pudendal	Alternative to sacral stimulation All but eliminates collateral stimulation to unwanted areas like the buttock and legs	Lacks precision, procedure based on anatomical landmarks Small margin for error Requires intraoperative EMG Close proximity to large vessels
Mid-thoracic	No different than traditional stimulation Can potentially capture lumbar as well sacral fibers of pelvic region, simultaneously More complete coverage of sympathetic innervation Good for abdomen, as well	Inconsistent Small margin for error May have stimulation of unwanted areas
Conus	Easy to target Good coverage of pelvic region	Inconsistent stimulation due to mobility of conus Large volume of CSF surrounding the target
DRG Stimulation	Theoretically would cover lumbar and sacral, simultaneously Selectively target precise regions with little-to-no unwanted collateral stimulation Level-1 evidence for CRPS	Unproven and no data to support for this indication Not approved indication in the United States
Intrathecal Ziconotide	Favorable side-effect profile with no drug-related mortalities reported to date Level-1 evidence for chronic pain	Unproven and no data to support for this indication Requires slow titration Potential incontinence

pelvic pain. Injections and blocks can, however, reveal a great deal of diagnostic information, even in the absence of therapeutic benefit, which can help to identify the target(s) for potential neuromodulation therapies. Even in severe cases of CPP, blocks should still be attempted if for no other purpose than to help map out the course of the pain from the periphery to the central nervous system.

CONCLUSION

Even if neurostimulation procedures fail, our

patients are not committed to a lifetime of opioid management as IDD remains a viable option. Ziconotide has been demonstrated successful for the treatment of multiple chronic pain syndromes in high level studies (85,91) and has a favorable side effect profile as compared to intrathecal morphine (90). Given the fragile nature of CPP patients, ziconotide may be preferable simply because of the greater degree of safety as compared to other commonly used medications.

REFERENCES

- Kothari S. Neuromodulatory approaches to chronic pelvic pain and coccygodynia. *Acta Neurochir Suppl* 2007; 97:365-371.
- Hunter C, Dave N, Diwan S, Deer T. Neuromodulation of pelvic visceral pain: Review of the literature and case series of potential novel targets for treatment. *Pain Pract* 2013; 13:3-17.
- Janicki TI. Chronic pelvic pain as a form of complex regional pain syndrome. *Clin Obstet Gynecol* 2003; 46:797-803.
- Baranowski AP. Chronic pelvic pain. *Best Pract Res Clin Gastroenterol* 2009; 23:593-610.
- Ploteau S, Labat JJ, Riant T, Levesque A, Robert R, Nizard J. New concepts on functional chronic pelvic and perineal pain: Pathophysiology and multidisciplinary management. *Discov Med* 2015; 19:185-192.
- Lee RB, Stone K, Magelssen D, Belts RP, Benson WL. Presacral neurectomy for chronic pelvic pain. *Obstet Gynecol* 1986; 68:517-521.
- Ingber MS, Peters KM, Killinger KA, Carrico DJ, Ibrahim IA, Diokno AC. Dilemmas in diagnosing pelvic pain: Multiple pelvic surgeries common in women with interstitial cystitis. *Int Urogynecol J Pelvic Floor Dysfunct* 2008; 19:341-345.
- Kumar K, Toth C, Nath RK, Laing P. Epidural spinal cord stimulation for treatment of chronic pain--some predictors of success. A 15-year experience. *Surg Neurol* 1998; 50:110-120; discussion 120-121.
- Oakley JC, Prager JP. Spinal cord stimulation: Mechanisms of action. *Spine (Phila Pa 1976)* 2002; 27:2574-2583.
- Hayek SM, Veizi E, Hanes M. Treatment-limiting complications of percutaneous spinal cord stimulator implants: A review of eight years of experience from an academic center database. *Neuromodulation* 2015; 18:603-608; discussion 608-609.
- Benzon HT, Raja SN, Fishman SM, Liu SS, Cohen SP. *Essentials of pain medicine*. 3rd ed. Elsevier/Saunders, Philadelphia, PA, 2011, [Need pages].
- Oh CS, Chung IH, Ji HJ, Yoon DM. Clinical implications of topographic anatomy on the ganglion impar. *Anesthesiology* 2004; 101:249-250.
- Agur AMR, Dalley AF. *Grant's atlas of anatomy*. 12th ed. Wolters Kluwer Health/Lippincott Williams & Wilkins, Philadelphia, PA, 2008, [Need pages].
- Moore KL, Dalley AF. *Clinically oriented anatomy*. 4th ed. Lippincott Williams & Wilkins, Philadelphia, PA, 1999, [Need pages].
- Markwell SJ. Physical therapy management of pelvi/perineal and perianal pain syndromes. *World J Urol* 2001; 19:194-199.
- Rosenbaum TY, Owens A. The role of pelvic floor physical therapy in the treatment of pelvic and genital pain-related sexual dysfunction (CME). *J Sex Med* 2008; 5:513-523; quiz 524-525.
- Nickel JC, Mullins C, Tripp DA. Development of an evidence-based cognitive behavioral treatment program for men with chronic prostatitis/chronic pelvic pain syndrome. *World J Urol* 2008; 26:167-172.
- Fall M, Baranowski AP, Elneil S, Engeler D, Hughes J, Messelink EJ, Oberpenning F, de C Williams AC; European Association of Urology. EAU guidelines on chronic pelvic pain. *Eur Urol* 2010; 57:35-48.
- Abbott JA, Jarvis SK, Lyons SD, Thomson A, Vancaille TG. Botulinum toxin type A for chronic pain and pelvic floor spasm in women: A randomized controlled trial. *Obstet Gynecol* 2006; 108:915-923.
- de Leon-Casasola OA, Kent E, Lema MJ. Neurolytic superior hypogastric plexus block for chronic pelvic pain associated with cancer. *Pain* 1993; 54:145-151.
- Rosenberg SK, Tewari R, Boswell MV, Thompson GA, Seftel AD. Superior hypogastric plexus block successfully treats severe penile pain after transurethral resection of the prostate. *Reg Anesth Pain Med* 1998; 23:618-620.
- Plancarte R, Amescua C, Patt RB, Allende S. Presacral blockade of the ganglion of Walther (ganglion impar). *Anesthesiology* 1990; 73:A751.
- Gundavarpu S, Lema MJ. Superior hypogastric nerve block for pelvic pain. *Techniques in Regional Anesthesia and Pain Management* 2001; 5:116-119.
- Plancarte R, Amescua C, Patt RB, Aldrete JA. Superior hypogastric plexus block for pelvic cancer pain. *Anesthesiology* 1990; 73:236-239.
- Williams DJ. Book review: *Grant's atlas of anatomy*. 11th ed. by Anne M.R. Agur and Arthur F. Dalley. *Clinical Anatomy* 2006; 19:575.
- Sluijter ME, van Kleef M. Characteristics and mode of action of radiofrequency lesions. *Current Review of Pain* 1998; 2:143-150.
- Malik K, Benzon HT. Pulsed radiofrequency: A critical review of its efficacy. *Anaesth Intensive Care* 2007; 35:863-873.
- Rhame EE, Levey KA, Gharibo CG. Successful treatment of refractory pudendal neuralgia with pulsed radiofrequency. *Pain Physician* 2009; 12:633-638.
- Valovska A, Peccora CD, Philip CN, Kaye AD, Urman RD. Sacral neuromodulation as a treatment for pudendal neuralgia. *Pain Physician* 2014; 17:E645-E650.
- Hong MJ, Kim YD, Park JK, Hong HJ. Management of pudendal neuralgia using ultrasound-guided pulsed radiofrequency: A report of two cases and discussion of pudendal nerve block techniques. *J Anesth* 2016; 30:356-359.
- Ozkan D, Akkaya T, Yildiz S, Comert A. Ultrasound-guided pulsed radiofrequency treatment of the pudendal nerve in chronic pelvic pain. *Anaesthesist* 2016; 65:134-136.
- Feler CA, Whitworth LA, Brookoff D, Powell R. Recent advances: Sacral nerve root stimulation using a retrograde method of lead insertion for the treatment of pelvic pain due to interstitial cystitis. *Neuromodulation* 1999; 2:211-216.
- Alo KM, Gohel R, Corey CL. Sacral nerve root stimulation for the treatment of urge incontinence and detrusor dysfunction utilizing a cephalocaudal intraspinal method of lead insertion: A case report. *Neuromodulation* 2001; 4:53-58.
- Deer TR, Pope JE (eds). *Atlas of implantable therapies for pain management*. 2nd ed. Springer, New York, NY, 2016, [Need pages].
- Bosch JL. An update on sacral neuromodulation: Where do we stand with this in the management of lower urinary tract dysfunction in 2010? *BJU Int* 2010; 106:1432-1442.
- Steinberg AC, Oyama IA, Whitmore KE. Bilateral S3 stimulator in patients with interstitial cystitis. *Urology* 2007; 69:441-443.
- Zabihi N, Mourtzinos A, Maher MG, Raz S, Rodriguez LV. Short-term results of bilateral S2-S4 sacral neuromodulation for the treatment of refractory interstitial cystitis, painful bladder syndrome, and chronic pelvic pain. *Int Urogynecol J Pelvic Floor Dysfunct* 2008; 19:553-557.

38. Schmidt RA. Technique of pudendal nerve localization for block or stimulation. *J Urol* 1989; 142:1528-1531.
39. Spinelli M, Malaguti S, Giardiello G, Lazzari M, Tarantola J, Van Den Hombergh U. A new minimally invasive procedure for pudendal nerve stimulation to treat neurogenic bladder: Description of the method and preliminary data. *Neurol Urodyn* 2005; 24:305-309.
40. Peters KM, Feber KM, Bennett RC. Sacral versus pudendal nerve stimulation for voiding dysfunction: a prospective, single-blinded, randomized, crossover trial. *Neurol Urodyn* 2005; 24:643-647.
41. Bock S, Folie P, Wolff K, Marti L, Engeler DS, Hetzer FH. First experiences with pudendal nerve stimulation in fecal incontinence: A technical report. *Tech Coloproctol* 2010; 14:41-44.
42. Heinze K, Hoermann R, Fritsch H, Dermietzel R, van Ophoven A. Comparative pilot study of implantation techniques for pudendal neuromodulation: Technical and clinical outcome in first 20 patients with chronic pelvic pain. *World J Urol* 2015; 33:289-294.
43. Pratt OG, Gwinnutt C, Bakewell S. The autonomic nervous system—basic anatomy and physiology. *Update in Anesthesia* 1995; 5:36-39.
44. Van Kerrebroeck PE, Marcelissen TA. Sacral neuromodulation for lower urinary tract dysfunction. *World J Urol* 2012; 30:445-450.
45. Uludag O, Melenhorst J, Koch SM, van Gemert WG, Dejong CH, Baeten CG. Sacral neuromodulation: Long-term outcome and quality of life in patients with faecal incontinence. *Colorectal Dis* 2011; 13:1162-1166.
46. Siegel SW, Catanzaro F, Dijkema HE, Elhilali MM, Fowler CJ, Gajewski JB, Hassouna MM, Janknegt RA, Jonas U, van Kerrebroeck PE, Lycklama a Nijeholt AA, Oleson KA, Schmidt RA. Long-term results of a multicenter study on sacral nerve stimulation for treatment of urinary urge incontinence, urgency-frequency, and retention. *Urology* 2000; 56:87-91.
47. Dijkema HE, Weil EH, Mijs PT, Janknegt RA. Neuromodulation of sacral nerves for incontinence and voiding dysfunctions. Clinical results and complications. *Eur Urol* 1993; 24:72-76.
48. Alo KM, Yland MJ, Redko V, Feler C, Naumann C. Lumbar and sacral nerve root stimulation (NRS) in the treatment of chronic pain: A novel anatomic approach and neuro stimulation technique. *Neuromodulation* 1999; 2:23-31.
49. Alo KM, McKay E. Selective nerve root stimulation (SNRS) for the treatment of intractable pelvic pain and motor dysfunction: A case report. *Neuromodulation* 2001; 4:19-23.
50. Fishman S, Ballantyne J, Rathmell JP, Bonica JJ. *Bonica's management of pain*. 4th ed. Lippincott, Williams & Wilkins, Baltimore, MD, 2010. {Need pages}.
51. Theodosiadis P, Goroszeniuk T, Grosomanidis V. Short term neuromodulation trial via stimulating catheter in coccydynia treatment: 271. *Regional Anesthesia and Pain Medicine* 2004; 29:113.
52. Richter EO, Abramova MV, Alo KM. Percutaneous cephalocaudal implantation of epidural stimulation electrodes over sacral nerve roots: A technical note on the importance of the lateral approach. *Neuromodulation* 2011; 14:62-67; discussion 67.
53. Kim YH, Moon DE. Sacral nerve stimulation for the treatment of sacroiliac joint dysfunction: A case report. *Neuromodulation* 2010; 13:306-310.
54. Yakovlev AE, Timchenko AA, Parmentier AM. Spinal cord stimulation and sacral nerve stimulation for postlaminectomy syndrome with significant low back pain. *Neuromodulation* 2014; 17:763-765.
55. van Kerrebroeck PE, van Voskuilen AC, Heesakkers JP, Lycklama a Nijeholt AA, Siegel S, Jonas U, Fowler CJ, Fall M, Gajewski JB, Hassouna MM, Cappellano F, Elhilali MM, Milam DF, Das AK, Dijkema HE, van den Hombergh U. Results of sacral neuromodulation therapy for urinary voiding dysfunction: Outcomes of a prospective, worldwide clinical study. *J Uro* 2007; 178:2029-2034.
56. Comiter CV. Sacral neuromodulation for the symptomatic treatment of refractory interstitial cystitis: A prospective study. *J Urol* 2003; 169:1369-1373.
57. Labat JJ, Riant T, Robert R, Amarenco G, Lefaucheur JP, Rigaud J. Diagnostic criteria for pudendal neuralgia by pudendal nerve entrapment (Nantes criteria). *Neurol Urodyn* 2008; 27:306-310.
58. de Groat WC. Mechanisms underlying recurrent inhibition in the sacral parasympathetic outflow to the urinary bladder. *J Physiol* 1976; 257:503-513.
59. DasGupta R, Fowler CJ. Urodynamic study of women in urinary retention treated with sacral neuromodulation. *J Urol* 2004; 171:1161-1164.
60. Saifuddin A, Burnett SJ, White J. The variation of position of the conus medullaris in an adult population. A magnetic resonance imaging study. *Spine (Phila Pa 1976)* 1998; 23:1452-1456.
61. Nashold BS Jr, Grimes J, Friedman H, Semans J, Avery R. Electrical stimulation of the conus medullaris in the paraplegic. A 5-year review. *Appl Neurophysiol* 1977-1978; 40:192-207.
62. Kapural L, Narouze SN, Janicki TI, Mezhail N. Spinal cord stimulation is an effective treatment for the chronic intractable visceral pelvic pain. *Pain Med* 2006; 7:440-443.
63. Buffenoir K, Rioult B, Hamel O, Labat JJ, Riant T, Robert R. Spinal cord stimulation of the conus medullaris for refractory pudendal neuralgia: A prospective study of 27 consecutive cases. *Neurol Urodyn* 2015; 34:177-182.
64. Gorecki JP, Burt T, Wee A. Relief from chronic pelvic pain through surgical lesions of the conus medullaris dorsal root entry zone. *Stereotact Funct Neurosurg* 1992; 59:69-75.
65. Howell B, Lad SP, Grill WM. Evaluation of intradural stimulation efficiency and selectivity in a computational model of spinal cord stimulation. *PLoS One* 2014; 9:e114938.
66. Ranger MR, Irwin GJ, Bunbury KM, Peutrell JM. Changing body position alters the location of the spinal cord within the vertebral canal: A magnetic resonance imaging study. *Br J Anaesth* 2008; 101:804-809.
67. Fettes PD, Leslie K, McNabb S, Smith PJ. Effect of spinal flexion on the conus medullaris: a case series using magnetic resonance imaging. *Anaesthesia* 2006; 61:521-523.
68. Sapunar D, Ljubkovic M, Lirk P, McCallum JB, Hogan QH. Distinct membrane effects of spinal nerve ligation on injured and adjacent dorsal root ganglion neurons in rats. *Anesthesiology* 2005; 103:360-376.
69. Krames ES. The dorsal root ganglion in chronic pain and as a target for neuromodulation: A review. *Neuromodulation* 2015; 18:24-32; discussion 32.
70. Sukhotinsky I, Ben-Dor E, Raber P, Devor M. Key role of the dorsal root ganglion in neuropathic tactile hypersensitivity. *Eur J Pain* 2004; 8:135-143.
71. Liem L, Russo M, Huygen FJ, Van Buy-

- ten JP, Smet I, Verrills P, Cousins M, Brooker C, Levy R, Deer T, Kramer J. One-year outcomes of spinal cord stimulation of the dorsal root ganglion in the treatment of chronic neuropathic pain. *Neuromodulation* 2015; 18:41-48; discussion 48-49.
72. van Bussel CM, Stronks DL, Huygen FJ. Successful treatment of intractable complex regional pain syndrome type I of the knee with dorsal root ganglion stimulation: A case report. *Neuromodulation* 2015; 18:58-60; discussion 60-61.
73. Deer TR, Levy RM, Kramer J, Poree L, Amirdelfan K, Grigsby E, Staats P, Burton AW, Burgher AH, Obray J, Scowcroft J, Golovac S, Kapural L, Paicius R, Kim C, Pope J, Yearwood T, Samuel S, McRoberts WP, Cassim H, Netherton M, Miller N, Schaufele M, Tavel E, Davis T, Davis K, Johnson L, Mekhail N. Dorsal root ganglion stimulation yielded higher treatment success rate for complex regional pain syndrome and causalgia at 3 and 12 months: A randomized comparative trial. *Pain* 2017; 158:669-681.
74. Hunter C. A physician initiated, multi-center retrospective registry on dorsal root ganglion (DRG) stimulation - An analysis on the impact of lead location compared to the presentation of pain. Oral presentation at the International Neuromodulation Society - 13th World Congress, Edinburgh, Scotland, UK, May 30, 2017.
75. Greenwood-Van Meerveld B, Johnson AC, Foreman RD, Linderoth B. Attenuation by spinal cord stimulation of a nociceptive reflex generated by colorectal distention in a rat model. *Auton Neurosci* 2003; 104:17-24.
76. Krames E, Mousad DG. Spinal cord stimulation reverses pain and diarrheal episodes of irritable bowel syndrome: A case report. *Neuromodulation* 2004; 7:82-88.
77. Khan YN, Raza SS, Khan EA. Application of spinal cord stimulation for the treatment of abdominal visceral pain syndromes: Case reports. *Neuromodulation* 2005; 8:14-27.
78. Tiede JM, Ghazi SM, Lamer TJ, Obray JB. The use of spinal cord stimulation in refractory abdominal visceral pain: Case reports and literature review. *Pain Pract* 2006; 6:197-202.
79. De Ridder D, Plazier M, Kamerling N, Menovsky T, Vanneste S. Burst spinal cord stimulation for limb and back pain. *World Neurosurg* 2013; 80:642-649.
80. Kapural L, Yu C, Doust MW, Gliner BE, Vallejo R, Sitzman BT, Amirdelfan K, Morgan DM, Brown LL, Yearwood TL, Bundschu R, Burton AW, Yang T, Benyamin R, Burgher AH. Novel 10-kHz high-frequency therapy (HF10 therapy) is superior to traditional low-frequency spinal cord stimulation for the treatment of chronic back and leg pain: The SENZA-RCT randomized controlled trial. *Anesthesiology* 2015; 123:851-860.
81. Kapural L, Yu C, Doust MW, Gliner BE, Vallejo R, Sitzman BT, Amirdelfan K, Morgan DM, Yearwood TL, Bundschu R, Yang T, Benyamin R, Burgher AH. Comparison of 10-kHz high-frequency and traditional low-frequency spinal cord stimulation for the treatment of chronic back and leg pain: 24-month results from a multicenter, randomized, controlled pivotal trial. *Neurosurgery* 2016; 79:667-677.
82. Kriek N, Groeneweg G, Huygen FJ. Burst spinal cord stimulation in a patient with complex regional pain syndrome: A 2-year follow-up. *Pain Pract* 2015; 15:E59-E64.
83. Crapanzano JT, Harrison-Bernard LM, Jones MR, Kaye AD, Richter EO, Potash MN. High frequency spinal cord stimulation for complex regional pain syndrome: A case report. *Pain Physician* 2017; 20:E177-E182.
84. Staats PS, Yearwood T, Charapata SG, Presley RW, Wallace MS, Byas-Smith M, Fisher R, Bryce DA, Mangieri EA, Luther RR, Mayo M, McGuire D, Ellis D. Intrathecal ziconotide in the treatment of refractory pain in patients with cancer or AIDS: A randomized controlled trial. *JAMA* 2004; 291:63-70.
85. Miljanich GP. Ziconotide: Neuronal calcium channel blocker for treating severe chronic pain. *Curr Med Chem* 2004; 11:3029-3040.
86. McGivern JG. Ziconotide: A review of its pharmacology and use in the treatment of pain. *Neuropsychiatr Dis Treat* 2007; 3:69-85.
87. Kapural L, Lokey K, Leong MS, Fiekowsky S, Stanton-Hicks M, Sapienza-Crawford AJ, Webster LR. Intrathecal ziconotide for complex regional pain syndrome: Seven case reports. *Pain Pract* 2009; 9:296-303.
88. Bowersox SS, Gadbois T, Singh T, Pettus M, Wang YX, Luther RR. Selective N-type neuronal voltage-sensitive calcium channel blocker, SNX-111, produces spinal antinociception in rat models of acute, persistent and neuropathic pain. *J Pharmacol Exp Ther* 1996; 279:1243-1249.
89. Deer TR, Levy R, Prager J, Buchser E, Burton A, Caraway D, Cousins M, De Andrés J, Diwan S, Erdek M, Grigsby E, Huntoon M, Jacobs MS, Kim P, Kumar K, Leong M, Liem L, McDowell GC 2nd, Panchal S, Rauck R, Saulino M, Sitzman BT, Staats P, Stanton-Hicks M, Stearns L, Wallace M, Willis KD, Witt W, Yaksh T, Mekhail N. Polyanalgesic Consensus Conference--2012: Recommendations to reduce morbidity and mortality in intrathecal drug delivery in the treatment of chronic pain. *Neuromodulation* 2012; 15:467-482; discussion 482.
90. Bottros MM, Christo PJ. Current perspectives on intrathecal drug delivery. *J Pain Res* 2014; 7:615-626.
91. Pope JE, Deer TR. Ziconotide: A clinical update and pharmacologic review. *Expert Opin Pharmacother* 2013; 14:957-966.
92. Alo KH, M.; Richter E. Technical note: Percutaneous cephalocaudal peripheral nerve stimulation for coccydynia. *Journal of Neurosurgical Review* 2011; 1:78-81. {Please recheck this reference, unable to verify.}
93. Hubsher CJ, Jansen R, Riggs DR, Jackson BJ, Zaslau S. Sacral nerve stimulation for neuromodulation of the lower urinary tract. *Can J Urol* 2012; 19:6480-6484.

