

## Observational Study



## Comparison of Intraarticular Pulsed Radiofrequency and Intraarticular Corticosteroid Injection for Management of Cervical Facet Joint Pain

Ji Woon Lim, MD, Yun Woo Cho, MD, Dong Gyu Lee, MD, and Min Cheol Chang, MD

From: Department of Physical Medicine and Rehabilitation, College of Medicine, Yeungnam University, Korea

Address Correspondence: Min Cheol Chang, MD  
Department of Physical Medicine and Rehabilitation, College of Medicine, Yeungnam University 317-1, Daemyungdong, Namku, Taegu, 705-717, Republic of Korea  
E-mail: wheel633@hanmail.net

Disclaimer: This work was supported by the 2016 Yeungnam University Research Grant (Level 2).  
Conflict of interest: Each author certifies that he or she, or a member of his or her immediate family, has no commercial association (i.e., consultancies, stock ownership, equity interest, patent/licensing arrangements, etc.) that might pose a conflict of interest in connection with the submitted manuscript.

Manuscript received: 11-29-2016  
Revised manuscript received: 01-15-2017  
Accepted for publication: 02-27-2017

Free full manuscript: [www.painphysicianjournal.com](http://www.painphysicianjournal.com)

**Background:** Disorders of the facet joints are some of the most common sources of chronic spinal pain. Facet joint pain is responsible for approximately 50% of patients with chronic neck pain. Pulsed radiofrequency (PRF) stimulation, after placing needle electrodes into the joint space, has been recently reported for the management of joint pain.

**Objective:** The aim of this study was to evaluate the effect of intraarticular (IA) PRF for the management of cervical facet joint (CFJ) pain. In addition, we compared the effect of IA PRF to IA corticosteroid injection.

**Study Design:** Prospective observational study.

**Setting:** University hospital.

**Methods:** Forty patients with CFJ pain were included in the study and randomly assigned to one of 2 groups: the IA PRF group and the IA corticosteroid (ICI) group. There were 20 patients in each group. Pain intensity was evaluated using a numeric rating scale (NRS) at pre-treatment, and one, 3, and 6 months after treatment.

**Results:** When compared to the pretreatment NRS scores, patients in both groups showed a significant decrease in NRS scores at one, 3, and 6 months after treatment ( $P = 0.000$ ). Changes in the NRS scores over time were not significantly different between the groups ( $P = 0.227$ ). Six months after treatment, 10 patients (50.0%) in the PRF group and 12 patients (60.0%) in the ICI group reported successful pain relief (pain relief of  $\geq 50\%$ ).

**Limitations:** A small number of participants.

**Conclusion:** IA PRF stimulation is as effective as IA corticosteroid injection in attenuating CFJ pain. The use of PRF could decrease CFJ pain, while avoiding the adverse effects of steroids.

**Key words:** Cervical facet joint pain, pulsed radiofrequency, intraarticular stimulation, chronic pain, corticosteroid injection, numeric rating scale

**Pain Physician 2017; 20:E961-E967**

**D**isorders of the facet joints are some of the most common sources of chronic spinal pain, accounting for approximately 50% of patients with chronic neck pain (1). In addition to causing localized neck pain, cervical facet joint (CFJ) pain can radiate to the head or shoulders (2,3). In clinical practice,

the intraarticular (IA) injection of corticosteroids is widely and conventionally used for the management of neck pain originating in the facet joint (4-7). However, the effectiveness of this treatment method has been questioned (8). Also, corticosteroids can have adverse effects, including allergic reaction, flushing,

hyperglycemia, immunosuppression, menstrual changes, and adrenal suppression (9,10). Alternative approaches, such as cervical medial branch block and radiofrequency neurolysis of the cervical medial branch, have been developed for management of CFJ pain (11-13).

Radiofrequency treatment involves continuous stimulation, and results in ablation of nerves and tissues. The ablation is the result of frictional heat from a catheter needle (14). However, pulsed radiofrequency (PRF) uses a brief stimulation, followed by a long resting phase. PRF exposes the target nerves and tissues to an electric field, without producing sufficient heat to cause structural damage (15). Although the mechanism of PRF has not been clearly elucidated, it has been suggested that the electrical field produced by PRF can alter pain signals (16). Currently, PRF is used for various types of pain, including neuralgia, joint pain, and myofascial pain (17-19). PRF stimulation of the cervical medial branch has been reported to have a positive effect in the control of CFJ pain. Also, PRF stimulation, after placement of the needle electrodes into a joint space, can effectively reduce refractory joint pain (20,21). However, little is known about the effect of IA PRF stimulation for controlling CFJ pain.

In the current study, we treated chronic CFJ pain by placing an electrode into the CFJ space and applying PRF. In addition, we compared the effect of IA PRF to that of IA corticosteroid injection.

## METHODS

### Patients

We prospectively evaluated consecutive patients who presented with spontaneous onset of chronic neck pain. After applying inclusion criteria, 40 patients

(mean age:  $52.8 \pm 13.4$ , range 20 – 75) were included in this study (Table 1). The following inclusion criteria were used: (1)  $\geq 3$ -month history of axial cervical pain without radicular symptoms; (2) age between 20 and 79 years; (3) failure to respond to physical therapy and medication (axial cervical pain of at least 4 on the numeric rating scale, [NRS]); (4)  $\geq 50\%$  temporary pain relief following a diagnostic block with IA injection of 0.3 mL of 2% lidocaine. This diagnostic block was carried out only once for each patient. Each patient underwent cervical spine magnetic resonance imaging. Exclusion criteria included disc herniation, foraminal stenosis, coagulopathy, allergy to iodinated contrast, history of head and neck trauma, rheumatic disorders, migraine, other types of primary headaches, and any uncontrolled medical or psychiatric condition. All participants provided written informed consent prior to the study. The Institutional Review Board of a university hospital approved this study. Forty patients with CFJ pain were randomly assigned to one of 2 groups. In the PRF group (PRF group), 20 patients received PRF stimulation in the intraarticular space of the CFJ. In the IA corticosteroid injection group (ICI group), 20 patients received IA corticosteroid injection. In both groups, the needle was inserted into the inferior recess of the CFJ. Randomization was performed using a random table. Treatment was carried out only one time for each patient. A putatively painful CFJ was selected on the basis of the distribution of pain (22,23) (Fig. 1).

### Procedures

In the PRF group, the treatment was performed via a posterior approach with the patient in a prone position for C-arm fluoroscopy (Siemens) (24). The patient's thorax rested on 2 pillows, the neck was maximally flexed, and the head turned 60–90° away from the side of injection. Following neck flexion, the C-arm tube was angled cephalad, until it was at a tangent to the CFJ space. A 23-gauge cannula (SMK Pole Needle, 100 mm with a 10 mm active tip, Cotop International BV) was inserted under fluoroscopy parallel to the C-arm beam. To confirm intraarticular access, an arthrogram of the CFJ was obtained by injecting 0.3 mL of contrast (Fig. 2). Intraarticular access was successful in all 20 patients. In the PRF group, an electrode was connected to the cannula, and the CFJ was stimulated (Cosman G4 Radiofrequency Generator, Cosman Medical, USA). PRF treatment was administered at 5 Hz and a 5-ms pulsed width, for 360 seconds, at 55 V, under the condition that the electrode tip temperature did not exceed 42°C.

Table 1. Demographic characteristics of patients in the PRF and ICI groups.

	PRF group	ICI group	P-value
Number (n)	20	20	
Age (years)	$52.8 \pm 12.1$	$52.7 \pm 14.8$	0.968
Male : Female	7 : 13	10 : 10	0.337
NRS (pre-treatment)	$5.6 \pm 1.3$	$5.8 \pm 1.4$	0.779
Pain duration (months)	$15.1 \pm 14.1$	$11.1 \pm 10.8$	0.547

Values are presented as number or mean  $\pm$  standard deviation. Abbreviations: PRF, pulsed radiofrequency; ICI, intraarticular corticosteroid injection; NRS, numeric rating scale

In the ICI group, the preparation steps were identical to the PRF group. Under C-arm fluoroscopy, after confirming intraarticular access by injecting 0.3 mL of contrast into CFJ space, we injected 10 mg (0.25 mL) of dexamethasone, mixed with 0.25 mL of 0.125% bupivacaine using a 26-gauge, 90 mm spinal needle. Intraarticular injection was successful in all 20 patients in ICI group.

We performed either PRF stimulation or corticosteroid injection in a total of 84 levels of the CFJ (PRF group: 46 levels, ICI group: 38 levels; Table 2). We performed PRF or corticosteroid injection bilaterally in 6 and 5 patients, respectively. We did not perform the procedure unilaterally at more than 2 levels.

### Outcome Measures

The same investigator performed all pretreatment and follow-up assessments. This investigator was blinded to the grouping of the patients, and did not participate in any treatment. Pain intensity was assessed using a NRS, with values between 0 and 10, with 0 representing "no pain" and 10 representing "the most intense pain imaginable." The NRS scores were measured before treatment, and one, 3, and 6 months after treat-

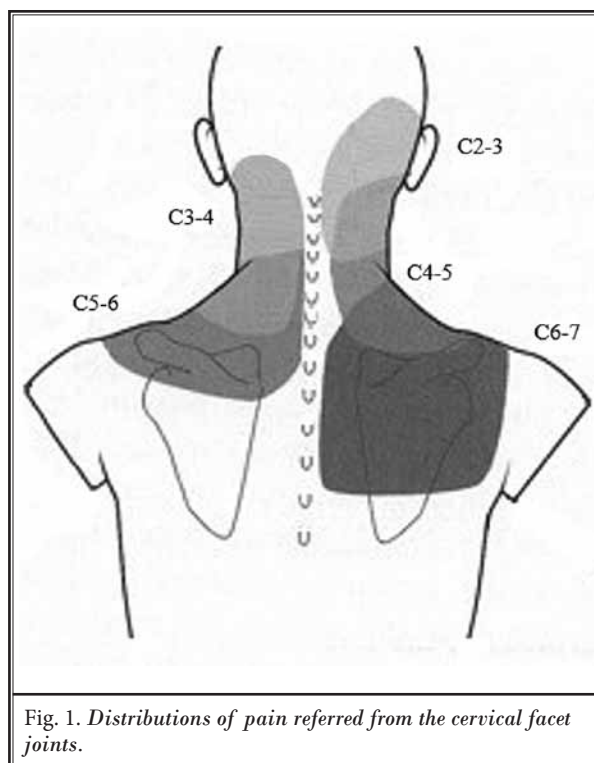


Fig. 1. Distributions of pain referred from the cervical facet joints.

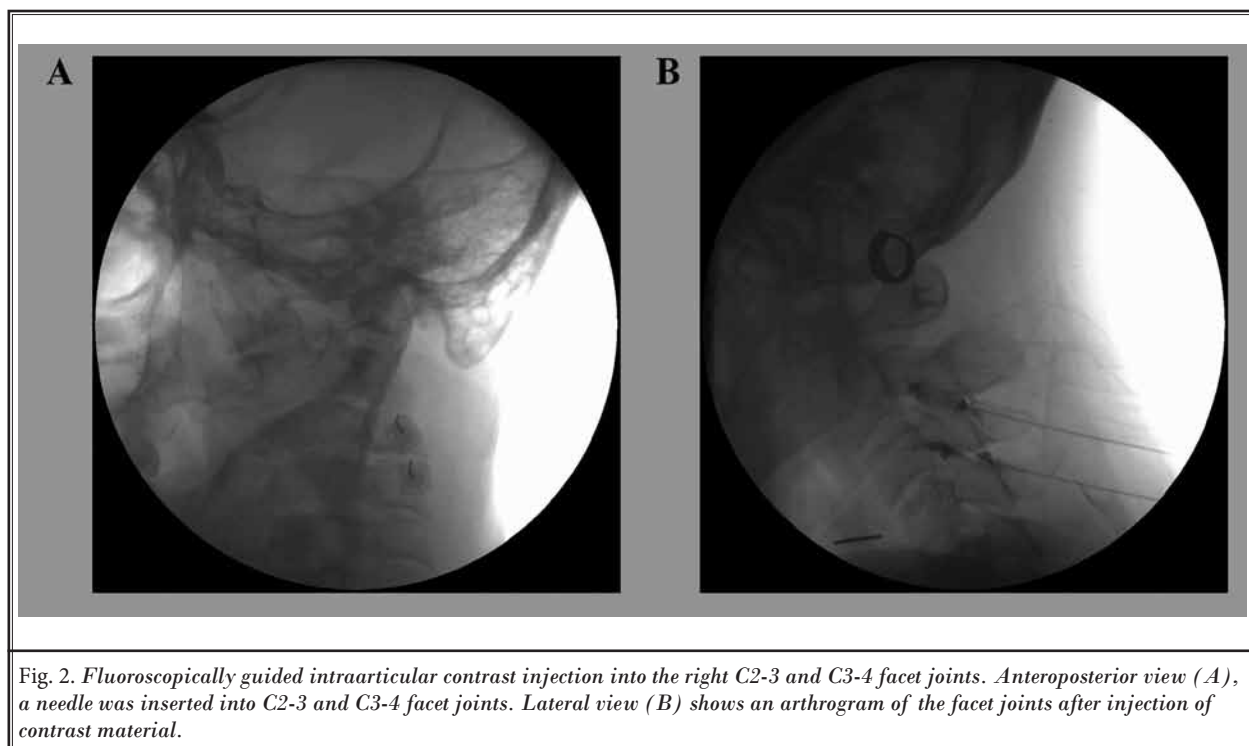


Fig. 2. Fluoroscopically guided intraarticular contrast injection into the right C2-3 and C3-4 facet joints. Anteroposterior view (A), a needle was inserted into C2-3 and C3-4 facet joints. Lateral view (B) shows an arthrogram of the facet joints after injection of contrast material.

Table 2. The treated facet joint level of each patient.

Patient number	PRF group	ICI group
1	Lt. C2-3, C3-4	Rt. C3-4, C4-5
2	Rt. C3-4	Rt. C5-6, C6-7
3	Both C4-5, C5-6	Rt. C4-5, C5-6
4	Rt. C3-4	Rt. C3-4, C4-5
5	Lt. C5-6, C6-7	Rt. C2-3, C3-4
6	Lt. C6-7	Lt. C5-6
7	Lt. C2-3, C3-4	Lt. C5-6, C6-7
8	Rt. C3-4, C4-5	Rt. C2-3, C3-4
9	Lt. C5-6, C6-7	Both C6-7
10	Both C5-6, C6-7	Both C2-3, C3-4
11	Rt. C4-5, C5-6	Both C6-7
12	Rt. C2-3, C3-4	Rt. C2-3
13	Lt. C5-6, C6-7	Both C2-3
14	Both C5-6, C6-7	Rt. C4-5, C5-6
15	Both C4-5, C5-6	Lt. C5-6, C6-7
16	Both C6-7	Rt. C3-4, C4-5
17	Rt. C2-3	Lt. C6-7
18	Lt. C3-4, C4-5	Both C4-5
19	Both C5-6, C6-7	Rt. C2-3
20	Rt. C2-3, C3-4	Rt. C3-4, C4-5

Abbreviations: PRF, pulsed radiofrequency; ICI, intraarticular corticosteroid injection

ment. Successful treatment was defined as more than 50% reduction in the NRS score at 6 months, when compared to the pre-treatment NRS score. To validate the change in pain reduction, NRS scores were evaluated by assessing the difference between the pretreatment NRS scores, and the 6-month after treatment scores (change in NRS [%] = [pretreatment score - score at 6 months after treatment] / pretreatment score × 100).

### Statistical Analysis

Data were analyzed using the Statistical Package for Social Science (SPSS, v. 22.0, IBM Corporation, Armonk, NY). Demographic data and successful pain relief rate were compared between the 2 groups using the Mann-Whitney U test and chi-square test. The changes in NRS scores in each PRF and ICI group were evaluated using repeated measure one-factor analysis. Repeated measure 2-factor analysis was used to compare changes between groups over time. Multiple comparisons were obtained following a contrast under Bonferroni correction. The level of statistical significance was set at  $P < 0.05$ .

## RESULTS

All patients completed the study. No adverse events were observed in the PRF group. Minor adverse events were observed in 2 patients in the ICI group. One patient complained of facial flushing during the 3 days after the procedure, and the other patient had hyperglycemia (blood glucose level of 300 – 400 mg/dl). There were no significant differences in the demographic data between groups (Table 1,  $P > 0.05$ ).

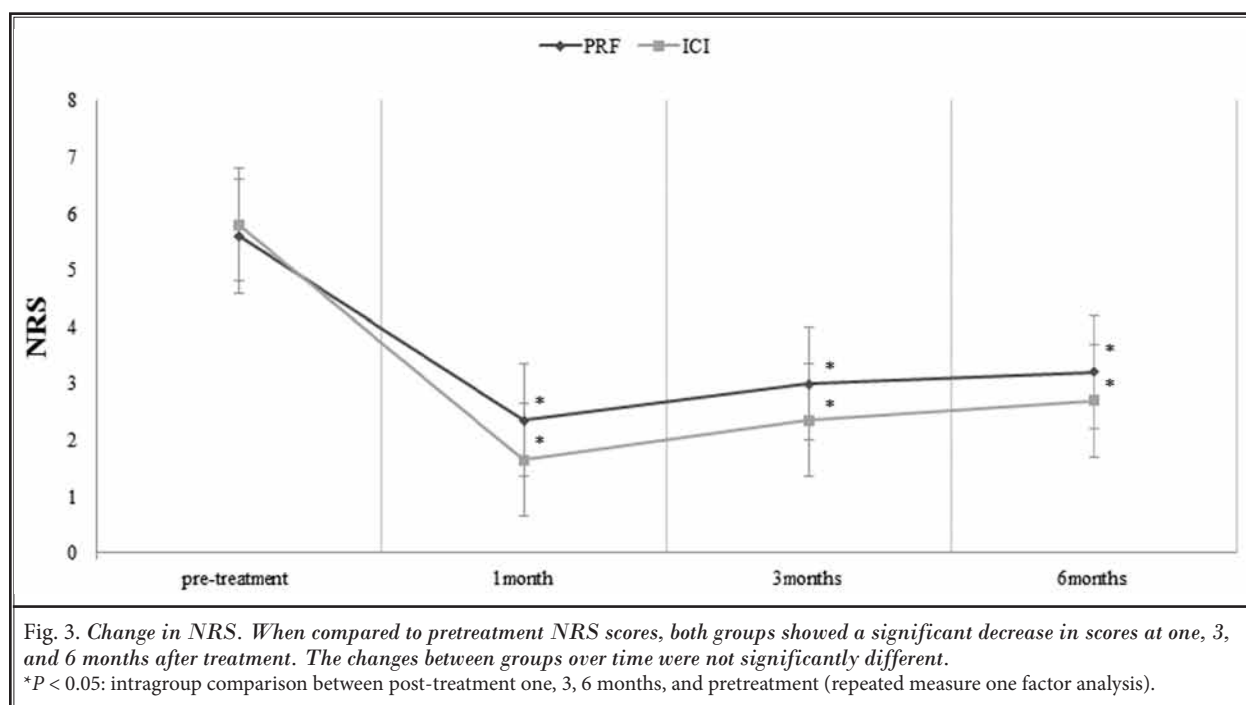
In the PRF group, the mean NRS decreased after treatment. The pretreatment NRS was  $5.6 \pm 1.3$ . At one month, the mean NRS was  $2.4 \pm 1.6$ , at 3 months,  $3.0 \pm 1.7$ , and at 6 months,  $3.2 \pm 1.7$  (Fig. 3). In the ICI group, the mean NRS decreased from  $5.8 \pm 1.4$  pretreatment, to  $1.7 \pm 0.9$  at one month,  $2.4 \pm 1.5$  at 3 months, and  $2.7 \pm 1.5$  at 6 months.

Scores on the NRS for each group were significantly different over time ( $P < 0.001$ ) (Fig. 3). In both groups, scores at one, 3, and 6 months were significantly decreased when compared to pretreatment scores ( $P < 0.001$ ). Changes in the NRS scores over time were not significantly different between groups ( $P = 0.227$ ) (Fig. 3). The decrease in scores from pre-treatment to each evaluation time point was not significantly different between the 2 groups (one month:  $P = 0.121$ , 3 months:  $P = 0.172$ , 6 months:  $P = 0.270$ ). Six months after treatment, 10 patients (50.0%) in the PRF group reported successful pain relief (pain relief of  $\geq 50\%$ ), and 12 patients (60.0%) in ICI group reported successful pain relief. There was no significant difference in rates of successful pain relief at 6 months after the procedures ( $P = 0.525$ ).

## DISCUSSION

In this study, we evaluated and compared the clinical effect of IA PRF stimulation and IA corticosteroid injection in patients with CFJ pain. Our results show that the severity of pain, measured with the NRS, was significantly reduced after each procedure, and persisted for the 6-month duration of the study. Furthermore, 50% – 60% of patients showed successful pain relief. The post-procedure effectiveness of the 2 procedures was similar over 6 months.

Inflammation of the synovium is likely to produce CFJ pain (25). There is extensive innervation of the synovial lining of the facet joint by nociceptive C-fibers (26). The neuropeptides substance P and calcitonin gene-related peptide play an important role in the development of pain, and are abundant in these nerve fibers (26-29). Excitement of these nerve fibers



by synovial inflammation is responsible for the development of the CFJ pain. The anti-inflammatory properties of corticosteroids block production and release of the inflammatory mediators (30). IA corticosteroid injection in our patients with CFJ pain could reduce the excitability of nociceptive nerve fibers and relieve pain. Previous studies reported that IA corticosteroid injection was useful to control CFJ pain (4-7). In contrast, Barnsley et al (8) reported that IA corticosteroid injection did not effectively manage CFJ pain. However, they included 41 patients with posttraumatic neck pain, suggesting that these results may not be applicable for non-traumatic CFJ pain.

Despite the effectiveness of IA corticosteroids, the potential for adverse effects must be considered, which are generally attributed to the chemistry or to the pharmacology of the corticosteroids (9,10). Adverse effects include suppression of the pituitary-adrenal axis, hyperadrenocorticism, avascular necrosis, osteoporosis, steroid myopathy, weight gain, and hyperglycemia (9,10). Minor complications, such as flushing, sweating, and nausea, can occur (9,10,30). Of the 20 patients in the ICI group, one developed facial flushing, and a second patient had hyperglycemia. PRF does not require the injection of a corticosteroid, thus eliminating these potential adverse effects. In the PRF group, no adverse events occurred.

Although the mechanism of IA PRF has not been elucidated, we are able to suggest possible mechanisms. First, IA PRF of the CFJ appears to have disrupted the synovial lining nociceptive C-fibers. Under the transmission electron microscope, Erdine et al (31) found that PRF results in ultrastructural lesions of the sensory nociceptive axons. These lesions are selectively located in the smaller, principal sensory nociceptors (C-fibers and A-delta fibers), and are infrequently identified on the larger non-pain related sensory fibers (A-beta fiber) (31). In addition, the residual current in the CFJ seems to inhibit the excitability of pain-generating afferent nerves, or free nerve endings, which richly innervate the articular capsule. The electrical field induced by a PRF electrode placed in soft tissue rapidly weakens, at increasing distances from the electrode (21). However, bone has insulating properties, and the current can be deflected by bony surfaces, and remain inside the joint space without weakening (21). Finally, PRF stimulation of CFJ is thought to reduce the inflammation. The electrical field influences the production of pro-inflammatory or inflammatory cytokines (20). After IA PRF, serum C-reactive protein and cytokines are reduced (20). Therefore, we hypothesize that IA PRF of the CFJ damages synovial lining nociceptive nerve fibers, inhibits the transfer of pain signals from nerves in the joint capsule, or reduces the inflammatory response related to CFJ pain.

Two studies have used IA PRF stimulation (20,21). In 2008, Sluijter et al (21) treated 6 patients with intracatable arthrogenic joint pain by applying IA PRF stimulation. Intraarticular stimulation was done in 6 joints (left C4-5 cervical facet; knee joint; sacroiliac joint; joint space at the intersection of the radius, scaphoid, and lunate bones; shoulder; and atlanto-axial joint). After PRF stimulation, each patient's pain was successfully reduced. In this study, the authors reported a reduction of cervical neck pain after PRF stimulation on the CFJ, but this is a single case report. In 2013, Schianchi et al (20) applied IA PRF to 89 joints, in 57 consecutive patients, with chronic joint pain. In this study, shoulder, knee, trapeziometacarpal, and metatarso-phalangeal joint pain was treated with PRF stimulation. Depending on the joint involved, decreased pain was noted in 60% – 90% of joints treated, and the effect persisted for 5 months. We report the first case-controlled study to evaluate the therapeutic effects of IA PRF in patients with chronic CFJ pain. In addition, we compared IA PRF to IA corticosteroid injection, and demonstrated that the 2 procedures have similar effectiveness in relief of CFJ pain.

## CONCLUSION

In conclusion, we found that both IA PRF stimulation and IA corticosteroid injection into the CFJ significantly relieved CFJ pain one, 3, and 6 months after the procedure. We did not detect significant differences between the 2 procedures. Successful pain relief at 6 months was greater than 50% for patients in both groups. We suggest that IA PRF can be a useful clinical option for the management of CFJ pain in patients at risk for development of complications from the use of corticosteroids. There are limitations of our study. First, the study involved a small number of participants. Second, the level of the origin of the facet joint pain was determined on the basis of distribution of pain, potentially adding a subjective component to our study. Third, the patients were not blinded to the procedure that they received. Finally, this study was conducted without a placebo group. Therefore, further studies are required to compensate for these limitations.

## REFERENCES

1. Yin W, Bogduk N. The nature of neck pain in a private pain clinic in the United States. *Pain Medicine* 2008; 9:196-203.
2. Fukui S, Ohseto K, Shiotani M, Ohno K, Karasawa H, Naganuma Y, Yuda Y. Referred pain distribution of the cervical zygapophyseal joints and cervical dorsal rami. *Pain* 1996; 68:79-83.
3. Windsor RE, Nagula D, Storm S. Electrical stimulation induced cervical medial branch referral patterns. *Pain Physician* 2003; 6:411-418.
4. Dory MA. Arthrography of the cervical facet joints. *Radiology* 1983; 148:379-382.
5. Dussault RG, Nicolet VM. Cervical facet joint arthrography. *J Can Assoc Radiol* 1985; 36:79-80.
6. Hove B, Gyldensted C. Cervical analgesic facet joint arthrography. *Neuroradiology* 1990; 32:456-459.
7. Roy DF, Fleury J, Fontaine SB, Dussault RG. Clinical evaluation of cervical facet joint infiltration. *Can Assoc Radiol J* 1988; 39:118-120.
8. Barnsley L, Lord SM, Wallis BJ, Bogduk N. Lack of effect of intraarticular corticosteroids for chronic pain in the cervical zygapophyseal joints. *N Engl J Med* 1994; 330:1047-1050.
9. Manchikanti L. Role of neuraxial steroids in interventional pain management. *Pain Physician* 2002; 5:182-199.
10. Manchikanti L, Boswell MV, Singh V, Benyamin RM, Fellows B, Abdi S, Buenaventura RM, Conn A, Datta S, Derby R, Falco FJ, Erhart S, Diwan S, Hayek SM, Helm S, Parr AT, Schultz DM, Smith HS, Wolfer LR, Hirsch JA; ASIPP-IPM. Comprehensive evidence-based guidelines for interventional techniques in the management of chronic spinal pain. *Pain Physician* 2009; 12:699-802.
11. Boswell MV. Therapeutic cervical medial branch blocks: A changing paradigm in interventional pain management. *Pain Physician* 2006; 9:279-281.
12. MacVicar J, Borowczyk JM, MacVicar AM, Loughnan BM, Bogduk N. Cervical medial branch radiofrequency neurotomy in New Zealand. *Pain Med* 2012; 13:647-654.
13. Manchikanti L, Damron K, Cash K, Manchukonda R, Pampati V. Therapeutic cervical medial branch blocks in managing chronic neck pain: A preliminary report of a randomized, double-blind, controlled trial: Clinical trial NCT0033272. *Pain Physician* 2006; 9:333-346.
14. Vatansever D, Tekin I, Tuglu I, Erbuyun K, Ok G. A comparison of the neuroablative effects of conventional and pulsed radiofrequency techniques. *Clin J Pain* 2008; 24:717-724.
15. Sluijter ME, Cosman ER, Rittmann WB, van Kleef M. The effects of pulsed radiofrequency fields applied to the dorsal root ganglion—A preliminary report. *Pain Clin* 1998; 11:109-117.
16. Van Zundert J, de Louw AJ, Joosten EA, Kessels AG, Honig W, Dederen PJ, Veening JG, Vles JS, van Kleef M. Pulsed and continuous radiofrequency current adjacent to the cervical dorsal root ganglion of the rat induces late cellular activity in the dorsal horn. *Anesthesiology* 2005; 102:125-131.
17. Choi GS, Ahn SH, Cho YW, Lee DG. Long-term effect of pulsed radiofrequency on chronic cervical radicular pain refractory to repeated transforaminal epidural steroid injections. *Pain Med*



- 2012; 13:368-375.
18. Park CH, Lee YW, Kim YC, Moon JH, Choi JB. Treatment experience of pulsed radiofrequency under ultrasound guided to the trapezius muscle at myofascial pain syndrome – a case report. *Korean J Pain* 2012; 25:52-54.
  19. Schianchi PM. A new technique to treat facet joint pain with pulsed radiofrequency. *Anesth Pain Med* 2015; 5:e21061.
  20. Schianchi PM, Sluijter ME, Balogh SE. The treatment of joint pain with intra-articular pulsed radiofrequency. *Anesth Pain Med* 2013; 3:250-255.
  21. Sluijter ME, Teixeira A, Serra V, Balogh S, Schianchi P. Intra-articular application of pulsed radiofrequency for arthrogenic pain – report of six cases. *Pain Pract* 2008; 8:57-61.
  22. Aprill C, Dwyer A, Bogduk N. Cervical zygapophyseal joint pain patterns. II: A clinical evaluation. *Spine (Phila Pa 1976)* 1990; 15:458-461.
  23. Dwyer A, Aprill C, Bogduk N. Cervical zygapophyseal joint pain patterns. I: A study in normal volunteers. *Spine (Phila Pa 1976)* 1990; 15:453-457.
  24. Dussault RG, Nicolet VM. Cervical facet joint arthrography. *J Can Assoc Radiol* 1985; 36:79-80.
  25. Lynch MC, Taylor JF. Facet joint injection for low back pain. A clinical study. *J Bone Joint Surg Br* 1986; 68:138-141.
  26. Chen C, Lu Y, Kallakuri S, Patwardhan A, Cavanaugh JM. Distribution of A-delta and C-fiber receptors in the cervical facet joint capsule and their response to stretch. *J Bone Joint Surg Am* 2006; 88:1807-1816.
  27. Cavanaugh JM, Lu Y, Chen C, Kallakuri S. Pain generation in lumbar and cervical facet joints. *J Bone Joint Surg Am* 2006; 88:63-67.
  28. Inami S, Shiga T, Tsujino A, Yabuki T, Okado N, Ochiai N. Immunohistochemical demonstration of nerve fibers in the synovial fold of the human cervical facet joint. *J Orthop Res* 2001; 19:593-596.
  29. Kallakuri S, Singh A, Chen C, Cavanaugh JM. Demonstration of substance P, calcitonin gene-related peptide, and protein gene product 9.5 containing nerve fibers in human cervical facet joint capsules. *Spine* 2004; 29:1182-1186.
  30. Lee DG, Ahn SH, Lee J. Comparative effectiveness of pulsed radiofrequency and transforaminal steroid injection for radicular pain due to disc herniation: A prospective randomized trial. *J Korean Med Sci* 2016; 31:1324-1330.
  31. Erdine S, Bilir A, Cosman ER, Cosman ER Jr. Ultrastructural changes in axons following exposure to pulsed radiofrequency fields. *Pain Pract* 2009; 9:407-417.

