

Retrospective Study

## Radiation Dose and Procedure Time for 994 CT-guided Spine Pain Control Procedures

Matthew S. Lazarus, MD, PhD<sup>1</sup>, Rebecca B. Forman, BA<sup>2</sup>, Allan L. Brook, MD<sup>1,2</sup>, and Todd S. Miller, MD<sup>1,2</sup>

From: <sup>1</sup>Montefiore Medical Center, Bronx, NY; <sup>2</sup>Albert Einstein College of Medicine, Bronx, NY

Address Correspondence: Matthew S. Lazarus, MD, PhD  
Montefiore Medical Center  
111 E. 210th St.  
Bronx, NY 10467  
Email: matthewslazarus@gmail.com

Disclaimer: There was no external funding in the preparation of this manuscript.

Conflict of interest: Dr. Brook is an advisor for Palladian and Globus.

Manuscript received: 05-01-2016  
Revised manuscript received: 10-17-2016  
Accepted for publication: 12-30-2016

Free full manuscript: [www.painphysicianjournal.com](http://www.painphysicianjournal.com)

**Background:** Image guidance for spine pain control procedures, including epidural steroid injection, nerve root block, and facet block, can be performed with either computed tomography (CT) or conventional fluoroscopy. CT has the advantage of improved anatomic localization and use of air for contrast; however, there are concerns that CT leads to higher radiation dose and longer procedure time.

**Objective:** To evaluate procedure time and radiation dose for multiple types of spine pain control procedures performed under CT guidance.

**Study Design:** Retrospective evaluation.

**Setting:** Department of radiology in single academic medical center.

**Methods:** Institutional review board approval was obtained. We reviewed CT-guided spine procedures performed over a 12-month period from January 2012 to December 2012. Procedure type, procedure time, and dose-length product were recorded. Patient age and gender were recorded for each case; additionally, demographic and medical history data were obtained for a sub-group of patients.

**Results:** Nine hundred ninety-four studies (performed in 699 patients) were reviewed, including 585 epidural steroid injections, 228 nerve root blocks, and 90 facet blocks. For all studies, procedure time averaged  $7:34 \pm 5:05$ , and dose-length product averaged  $75 \text{ mGy}\cdot\text{cm} \pm 61$ . Additional medical history (available for 483 patients) revealed high rate of obesity (body mass index [BMI] =  $30 \pm 6.8$ , with 76% of patients overweight [BMI > 25] and 42% obese [BMI > 30]), and frequent medical comorbidities (including hypertension [n = 179], diabetes [n = 101], renal failure [n = 30], and heart failure [n = 17]).

**Limitations:** This study was performed retrospectively, and limited to a single institution.

**Conclusion:** These findings add to the growing evidence that CT guidance is a safe and effective technique for epidural steroid injection. These results further demonstrate that other spine intervention procedures, including nerve root block and facet block, can also be performed under CT guidance with short procedure time and reasonable levels of radiation exposure. This approach can be effectively used in a patient population with a high rate of obesity and medical comorbidities.

**Key words:** Epidural steroid injection, nerve root block, facet block, CT-guidance, spine intervention, radiation dose

**Pain Physician 2017; 20:E585-E591**

Commonly performed procedures for patients with spine pain include epidural steroid injections (ESI) to control low back pain or radicular pain (1), nerve root blocks for diagnosis or treatment of radicular pain (1-3), or facet blocks for

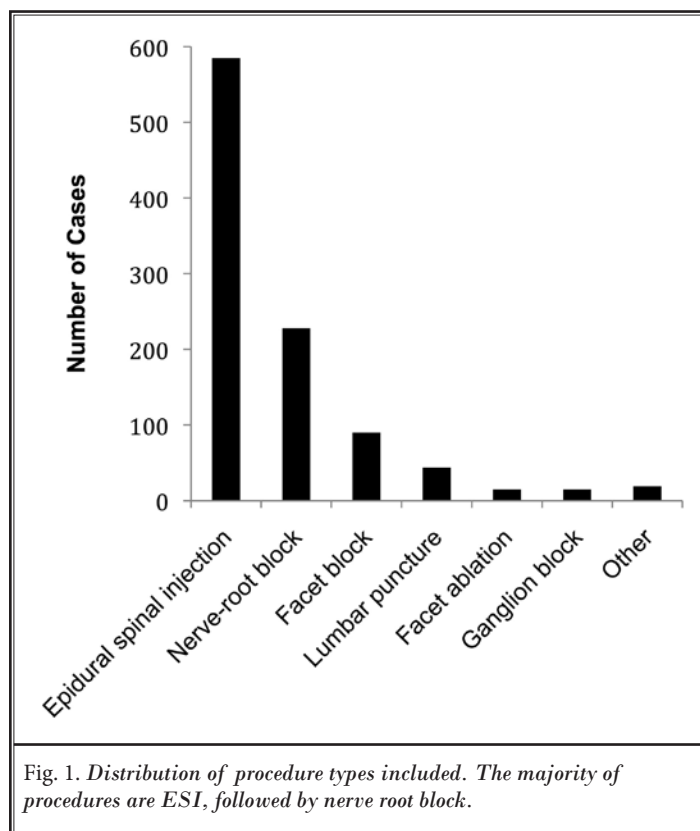
diagnosis or treatment of facet joint pain often related to degenerative disease (4).

While some spine injection procedures were previously performed using a blind technique, fluoroscopic guidance has largely replaced this approach due to

improved efficacy and reduced risk of complications related to incorrect needle localization (5,6). More recently, computed tomography (CT) guidance has been used for guiding spine injections, and offers several advantages (7,8). These include increased visualization of soft tissues, ability to use air contrast instead of iodinated contrasts (reducing both cost and risk of allergy [9]), and improved anatomic precision of needle placement (8).

Concerns regarding CT guidance versus fluoroscopy include potential for increased radiation dose and prolonged procedure time. Image guidance for ESI has been widely evaluated, and CT guidance, either with intermittent CT or with CT fluoroscopy, can be used with acceptable radiation dose and procedure time (9-11). CT guidance for nerve root blocks, either in cervical (12,13) or lumbosacral spine (12,14), has also been described.

Radiating radicular pain, in particular, has been linked to obesity (15), which is common in our patient population. Image guidance is particularly useful in obese patients due to the limited ability to palpate landmarks. However, large body habitus degrades image quality, and may require larger tube current for adequate visualization (10); therefore, a high proportion of obese patients in the sample may contribute to unacceptably high observed radiation doses.



In this retrospective review, we demonstrate that CT guidance can be employed for a wide range of procedures, with short procedure time and reasonable levels of radiation exposure. Furthermore, this can be done in a patient population with numerous medical comorbidities and a high rate of obesity.

## METHODS

Institutional review board approval was obtained for this retrospective review of all CT-guided pain management procedures performed over a 12-month period from January 2012 to December 2012. These were identified using the computerized radiology information system. Dose-length product (DLP) and procedure time were assessed for each case by reviewing data in the picture archiving and communication system. Procedure time was determined from time of first scout image to final axial image demonstrating the needle in the proper position; in practice, additional time would be required for patient positioning, drawing up and injecting medications, and post procedure patient care.

Where available, additional patient medical history and demographic data were obtained from the electronic medical record.

## Technique

Procedures were performed under intermittent CT guidance, with baseline settings 120 kVp, 50 mA; these were adjusted in some cases depending on body habitus. Technique for ESI has been described previously (9,10). Cases were monitored for complications in accordance with Society of Interventional Radiology guidelines (16).

## RESULTS

In total, 994 studies were reviewed, performed on 699 patients, consisting primarily of interlaminar ESI (n = 585), nerve root block (n = 228), and facet block (n = 90; Fig. 1). The majority of patients were women, 64%, and the average age was 62 years  $\pm$  16. Average procedure time for all studies was 7:34  $\pm$  5:05. Fifty percent of all cases were done

Table 1. Results by individual study type. Sample size is indicated for categories in which analyzed samples are less than total for that study type.

Procedure Type (n)	Age (yrs)	Gender	Procedure Time (Minutes:Seconds)	DLP (mGy•cm)
All (994)	62 ± 16	641 f, 353 m	7:34 ± 5:05	75 ± 61 (n=944)
Epidural spinal injection (585)	61 ± 16	357 f, 228 m	7:46 ± 4:57	75 ± 57 (n=557)
Nerve root block (228)	63 ± 16	163 f, 65 m	5:51 ± 3:36	67 ± 75 (n=217)
Facet block (90)	66 ± 13	58 f, 32 m	7:12 ± 3:17	72 ± 37 (n=86)
Lumbar puncture (44)	48 ± 22	30 f, 14 m	11:26 ± 8:37	95 ± 36 (n=41)
Facet ablation (15)	71 ± 11	10 f, 5 m	11:23 ± 5:34	82 ± 47
Ganglion block (15)	47 ± 15	12 f, 3 m	11:16 ± 7:24	158 ± 99 (n=13)
Other (17)	60 ± 15	10 f, 7 m	8:41 ± 8:42	82 ± 97 (n=15)

with a procedure time of less than 6:11, and 90% less than 12:35. Average DLP for all cases was 75 mGy•cm ± 61. Fifty percent of all cases were done with DLP less than 62.5 mGy•cm, and 90% less than 125.2 mGy•cm. Using a conversion factor of  $k = 15 \mu\text{Sv}/\text{mGy cm}$  (based on previously described methods [10]), average effective dose for all procedures was  $1.13 \pm 0.92 \text{ mSv}$ .

Procedure time and DLP for individual study types are displayed in Table 1. Both procedure time and DLP demonstrated a positive skew (Fig. 2); Table 2 lists outliers exceeding mean + 3SD for procedure time or DLP, and gives likely explanations for the elevated procedure time or DLP. Procedure time was elevated in some cases involving trainees (all cases were performed with attending supervision). In the most substantial procedure time outlier cases, use of conscious sedation or altered consciousness of the patient were likely contributing factors. Some cases combined multiple procedures or involved treatment at multiple levels, leading to increased procedure time. DLP was elevated in some cases due to technical error (for example, improperly using diagnostic rather than biopsy settings). High patient BMI, involvement of trainee in the procedure, or combination of multiple procedures also contributed to elevated DLP in some outlier cases.

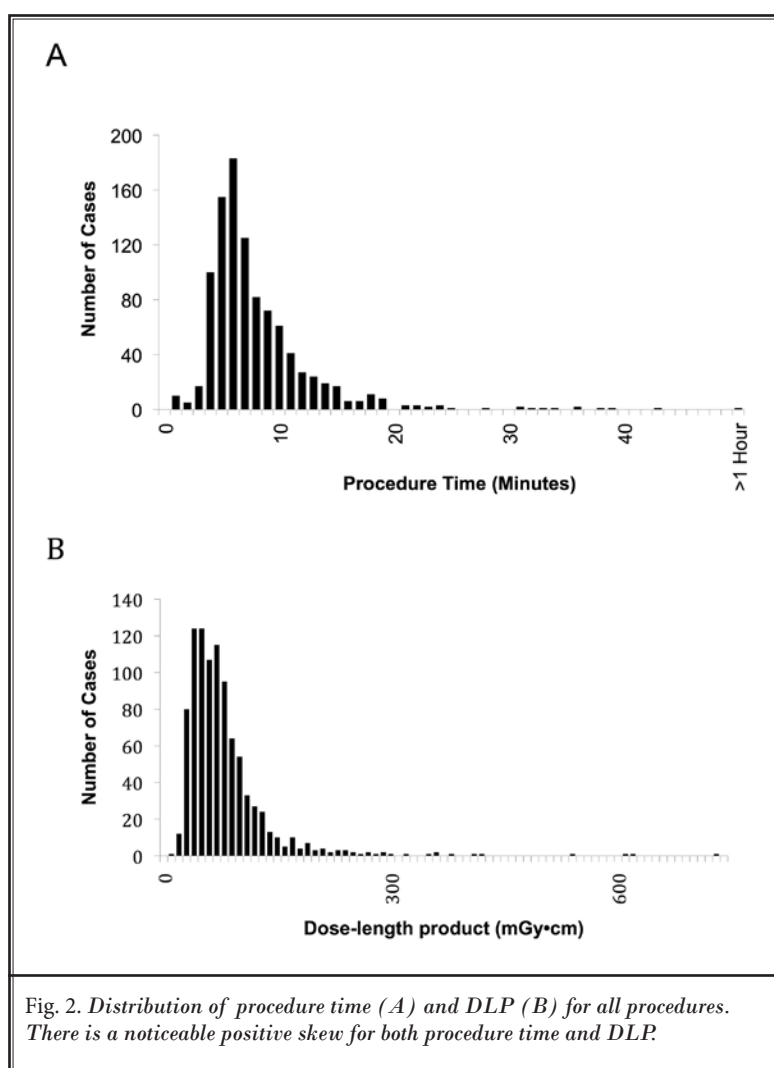


Table 2. Outlier cases for procedure time or DLP. Outliers are determined as exceeding mean + 3SD (procedure time > 22:48, DLP > 260 mGy·cm). Potential causes for elevated procedure time or DLP are listed.

Procedure Time Outliers (Min:Sec)	Likely Cause
71:12	Conscious sedation; fellow case with attending supervision
42:10	Altered consciousness patient; fellow case with attending supervision
38:25	Fellow case with attending supervision; high BMI
37:01	Bilateral sympathetic plexus injection
35:31	Fellow case with attending supervision; lumbar puncture in setting of degenerative disease
35:27	Bilateral sympathetic plexus injection
33:36	Combined epidural steroid injection and synovial cyst rupture
32:51	Fellow case with attending supervision; intrathecal chemotherapy injection; lumbar puncture
31:20	Fellow case with attending supervision; two levels injected
30:06	Diagnostic CT performed first; fellow case with attending supervision
30:02	Epidural steroid injection and biopsy of vertebral body lesion; fellow case with attending supervision
27:00	Combined epidural steroid injection and synovial cyst rupture
24:46	Fellow case with attending supervision
23:59	Intubated patient for lumbar puncture
23:40	Multiple, bilateral levels treated
23:25	High BMI
DLP Outliers (mGy·cm)	Likely cause
728	Technical error (settings)
613	Technical error (settings)
610	High BMI
533	Technical error (settings)
412	High BMI
407	Synovial cyst rupture
373	High BMI
356	Celiac block
356	Fellow case with attending supervision; high BMI
349	Epidural steroid injection and biopsy of vertebral body lesion; fellow case with attending supervision
313	Fellow case with attending supervision
294	High BMI
289	Combined nerve root block and epidural steroid injection
287	High BMI
274	Fellow case with attending supervision
269	Impar block
268	Combined epidural steroid injection and synovial cyst rupture

Medical history was available for 483 patients. Medical comorbidities were common in this study population, with hypertension (n = 179) and diabetes (n = 101) most common (Fig. 3 A). Average body mass index (BMI) was borderline obese,  $30 \pm 6.8$ , with 76% of patients above the cutoff for overweight (> 25), and 42% of patients in the obese range (> 30; Fig. 3 B).

There were no immediate or delayed complications related to these procedures.

## DISCUSSION

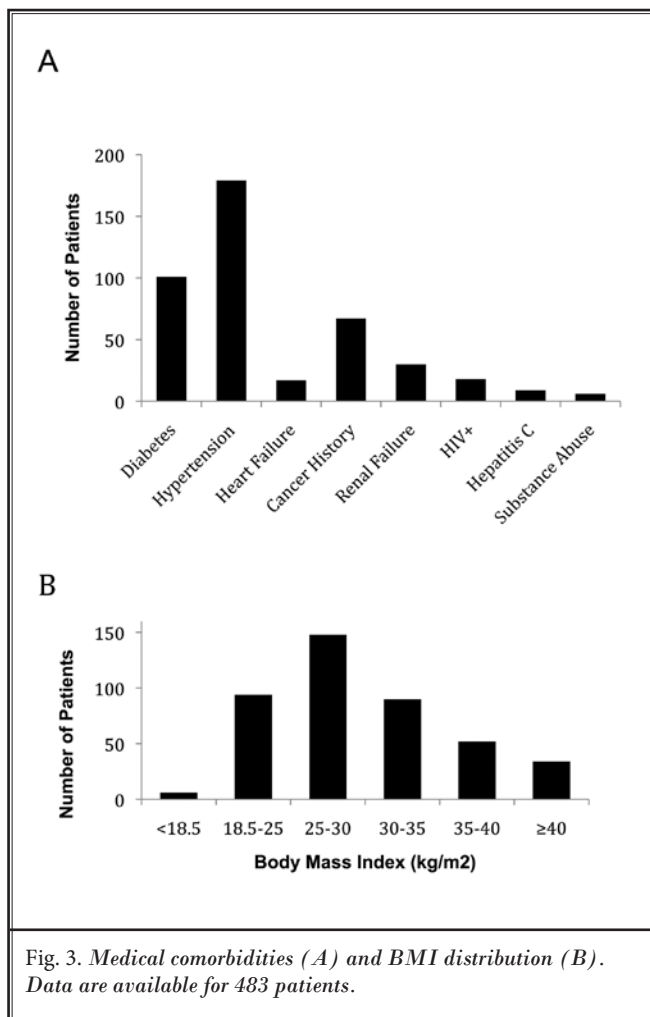
It is well established that use of image guidance is preferred to improve safety and efficacy in spine pain management injections. Use of CT guidance offers

several potential advantages over fluoroscopy. The need for iodinated contrast media is limited, as air contrast can be used instead, and is clearly visible under CT (9).

For ESI, use of CT guidance has been demonstrated to have acceptable procedure time and radiation dose (10). Our findings for procedure time and radiation dose are very similar to those described previously. We have further demonstrated that CT guidance can be used for nerve root blocks or facet blocks with similar, or somewhat lower, procedure times and radiation dose. Our smaller sample sizes for lumbar puncture, facet ablation, and ganglion block, demonstrate higher, but still acceptable, procedure times and radiation dose. Our overall effective dose of 1.13 mSv for all procedures, as well as for ESIs (which was also 1.13 mSv), are similar to prior reports for ESI using CT (9,10). Radiation dose using CT guidance is comparable to other techniques—in a study by Hoang et al (11), lumbar ESI using conventional fluoroscopy had an effective dose of 0.85 mSv, whereas CT fluoroscopy had an effective dose of 0.45 mSv without a planning CT and 3.35 mSv with a planning scan. A separate study found an effective dose of 0.93 mSv for conventional fluoroscopically guided lumbar ESI (17). Of note, using the CT dose index to estimate radiation exposure is likely to overestimate the dose in interventional procedures, by as much as 2-fold (10,18,19); actual radiation dose for this series may therefore be considerably lower than calculated.

Procedure time for a CT-guided technique was comparable to prior studies using CT fluoroscopy. One series for nerve root blocks found procedure time of 7 minutes (including injection time; [20]), compared to 5 minutes 51 seconds (not including injection time) in our series. Ultrasound guidance has been demonstrated for spinal procedures, including ESIs (21) and facet blocks (22), and has the benefit of not using ionizing radiation. Procedure time for ultrasound-guided ESI is comparable to conventional fluoroscopy, and to our experience with CT guidance. Evans et al (21) found procedure times (including injection) of 6 minutes 10 seconds for conventional fluoroscopy and 5 minutes 23 seconds for ultrasound guidance. Ultrasound-guided technique has the advantage over conventional fluoroscopy of identifying most vessels; ultrasound use is limited by the lack of precise needle localization (when obscured by bony structures) and operator dependence.

Outlier cases were identified and evaluated. Combination of multiple procedures, treatment at



multiple sites, or involvement of a neuroradiology fellow likely contributed to increased procedure time or radiation dose in some cases. Improper CT scanner settings may have led to increased radiation dose in some cases. Some of these factors may be modifiable in future cases to limit long procedure time or high exposure cases.

High BMI was seen in some outlier cases for both procedure time and DLP. However, the majority of the patient population was at least overweight, with greater than 40% in the obese category. Therefore, short procedure time and low radiation dose is achievable in a patient population with a high rate of obesity.

CT-guided ESI has been demonstrated to be safe, with a very low risk of complications. Rarely, patients may develop infection or hematoma associated with the injection site, but these are usually mild (23,24). There is also risk of additional complications, including intravascular or intrathecal injection, nerve injury, or air embolus

(23). These risks are very small when procedures are performed with image guidance.

Other procedure types included in this series, in particular nerve root blocks and facet blocks, are less widely studied, but are also considered to have a low risk of complications. However, neurologic damage following image-guided cervical (25) or lumbosacral (26) nerve root block has been reported. While minor side effects may be seen with facet blocks (related to intravascular penetration or local bleeding), significant complications are extremely rare (27). No clinically significant complications were observed in our current series. The prior 2 series by Chang et al (1000 cases and 345 cases) also demonstrated no complications (9,10).

One disadvantage of CT guidance may be added cost. CT guidance is approximately 0.9 relative value units higher than fluoroscopy (3.32 for CT scan for

therapy guide, versus 2.41 for fluoroscopic guidance for spine injection). In European cost-analysis studies, CT was demonstrated to be cheaper than magnetic resonance (MR) guidance for lumbosacral nerve root injection (28), and in between the cost of ultrasound and MR guidance for cervical nerve root injection (29). As cost and resources vary by health care facility and geographic location, the scale and potential impact of these differences should be considered in the individualized setting.

The primary limitation in this study is that the results are from a single institution. Our findings add to the growing evidence that CT guidance is a safe and effective technique for ESI. These data further demonstrate that other spine intervention procedures can be performed with acceptable procedure time and radiation dose under CT guidance.

## REFERENCES

- Boswell MV, Trescot AM, Datta S, Schultz DM, Hansen HC, Abdi S, Sehgal N, Shah RV, Singh V, Benyamin RM, Patel VB, Buenaventura RM, Colson JD, Cordero HJ, Epter RS, Jasper JF, Dunbar EE, Atluri SL, Bowman RC, Deer TR, Swicegood JR, Staats PS, Smith HS, Burton AW, Kloth DS, Giordano J, Manchikanti L, American Society of Interventional Pain P. Interventional techniques: Evidence-based practice guidelines in the management of chronic spinal pain. *Pain Physician* 2007; 10:7-111.
- Huston CW, Slipman CW. Diagnostic selective nerve root blocks: Indications and usefulness. *Physical Medicine and Rehabilitation Clinics of North America* 2002; 13:545-565.
- Quraishi NA. Transforaminal injection of corticosteroids for lumbar radiculopathy: Systematic review and meta-analysis. *European Spine Journal* 2012; 21:214-219.
- Boswell MV, Colson JD, Sehgal N, Dunbar EE, Epter R. A systematic review of therapeutic facet joint interventions in chronic spinal pain. *Pain Physician* 2007; 10:229-253.
- White AH, Derby R, Wynne G. Epidural injections for the diagnosis and treatment of low-back pain. *Spine* 1980; 5:78-86.
- Johnson BA. Image-guided epidural injections. *Neuroimaging Clinics of North America* 2000; 10:479-491.
- Paulson EK, Sheafor DH, Enterline DS, McAdams HP, Yoshizumi TT. CT fluoroscopy-guided interventional procedures: Techniques and radiation dose to radiologists. *Radiology* 2001; 220:161-167.
- Kranz PG, Raduazo P, Gray L, Kilani RK, Hoang JK. CT fluoroscopy-guided cervical interlaminar steroid injections: Safety, technique, and radiation dose parameters. *American Journal of Neuroradiology* 2012; 33:1221-1224.
- Chang A, Pochert S, Romano C, Brook A, Miller T. Safety of 1000 CT-guided steroid injections with air used to localize the epidural space. *American Journal of Neuroradiology* 2011; 32:E175-177.
- Chang AL, Schoenfeld AH, Brook AL, Miller TS. Radiation dose for 345 CT-guided interlaminar lumbar epidural steroid injections. *American Journal of Neuroradiology* 2013; 34:1882-1886.
- Hoang JK, Yoshizumi TT, Toncheva G, Gray L, Gafton AR, Huh BK, Eastwood JD, Lascola CD, Hurwitz LM. Radiation dose exposure for lumbar spine epidural steroid injections: A comparison of conventional fluoroscopy data and CT fluoroscopy techniques. *American Journal of Roentgenology* 2011; 197:778-782.
- Quinn SF, Murtagh FR, Chatfield R, Kori SH. CT-guided nerve root block and ablation. *American Journal of Roentgenology* 1988; 151:1213-1216.
- Wagner AL. CT fluoroscopic-guided cervical nerve root blocks. *American journal of Neuroradiology* 2005; 26:43-44.
- Schauburger JS, Kranz PG, Choudhury KR, Eastwood JD, Gray L, Hoang JK. CT-guided lumbar nerve root injections: Are we using the correct radiation dose settings? *American Journal of Neuroradiology* 2012; 33:1855-1859.
- Frilander H, Solovieva S, Mutanen P, Pihlajamaki H, Heliövaara M, Viikari-Juntura E. Role of overweight and obesity in low back disorders among men: A longitudinal study with a life course approach. *BMJ Open* 2015; 5:e007805.
- Sacks D, McClenny TE, Cardella JF, Lewis CA. Society of Interventional Radiology clinical practice guidelines. *Journal of Vascular and Interventional Radiology* 2003; 14:S199-S202.
- Kim S, Toncheva G, Anderson-Evans C, Huh BK, Gray L, Yoshizumi T. Kerma area product method for effective dose estimation during lumbar epidural steroid injection procedures: Phantom study. *American Journal of Roentgenology* 2009; 192:1726-1730.
- Bauhs JA, Vrieze TJ, Primak AN, Bruesewitz MR, McCollough CH. CT dosimetry: Comparison of measurement techniques and devices. *Radiographics* 2008; 28:245-253.
- Leng S, Christner JA, Carlson SK, Jacobsen M, Vrieze TJ, Atwell TD, McCollough CH. Radiation dose levels for interventional CT procedures. *American Journal of Roentgenology* 2011; 197:W97-W103.

20. Wagner AL. Selective lumbar nerve root blocks with CT fluoroscopic guidance: Technique, results, procedure time, and radiation dose. *American Journal of Neuroradiology* 2004; 25:1592-1594.
21. Evans I, Logina I, Vanags I, Borgeat A. Ultrasound versus fluoroscopic-guided epidural steroid injections in patients with degenerative spinal diseases: A randomised study. *European Journal of Anaesthesiology* 2015; 32:262-268.
22. Jung H, Jeon S, Ahn S, Kim M, Choi Y. The validation of ultrasound-guided lumbar facet nerve blocks as confirmed by fluoroscopy. *Asian Spine Journal* 2012; 6:163-167.
23. Goodman BS, Posecion LW, Mallemapati S, Bayazitoglu M. Complications and pitfalls of lumbar interlaminar and transforaminal epidural injections. *Current Reviews in Musculoskeletal Medicine* 2008; 1:212-222.
24. Windsor RE, Storm S, Sugar R. Prevention and management of complications resulting from common spinal injections. *Pain Physician* 2003; 6:473-483.
25. Hodler J, Boos N, Schubert M. Must we discontinue selective cervical nerve root blocks? Report of two cases and review of the literature. *European Spine Journal* 2013;22:S466-S470.
26. Houten JK, Errico TJ. Paraplegia after lumbosacral nerve root block: Report of three cases. *The Spine Journal* 2002; 2:70-75.
27. Manchikanti L, Malla Y, Wargo BW, Cash KA, Pampati V, Fellows B. Complications of fluoroscopically directed facet joint nerve blocks: A prospective evaluation of 7,500 episodes with 43,000 nerve blocks. *Pain Physician* 2012; 15:E143-E150.
28. Maurer MH, Schreiter N, de Bucourt M, Grieser C, Renz DM, Hartwig T, Hamm B, Streitparth F. Cost comparison of nerve root infiltration of the lumbar spine under MRI and CT guidance. *European Radiology* 2013; 23:1487-1494.
29. Maurer MH, Froeling V, Rottgen R, Bretschneider T, Hartwig T, Disch AC, de Bucourt M, Hamm B, Streitparth F. MRI-guided and CT-guided cervical nerve root infiltration therapy: A cost comparison. *RoFo : Fortschritte auf dem Gebiete der Rontgenstrahlen und der Nuklearmedizin* 2014; 186:559-566.

