

Literature Review

Transforaminal Endoscopic Decompression for a Giant Epidural Gas-Containing Pseudocyst: A Case Report and Literature Review

Bin Zhu, MD, Liang Jiang, MD, and Xiao Guang Liu, MD

From: Peking University Third Hospital, Beijing, China

Address Correspondence:
Xiao Guang Liu, MD
Peking University Third Hospital
Orthopedics department
No 49. N. Garden St
Haidian District
Beijing, China 100191
E-mail:
zhubin_ortho@163.com

Disclaimer: There was no external funding in the preparation of this manuscript.
Conflict of interest: Each author certifies that he or she, or a member of his or her immediate family, has no commercial association (i.e., consultancies, stock ownership, equity interest, patent/licensing arrangements, etc.) that might pose a conflict of interest in connection with the submitted manuscript.

Manuscript received:
03-15-2016
Accepted for publication:
03-29-2016

Free full manuscript:
www.painphysicianjournal.com

The isolated epidural gas-containing pseudocyst is an uncommon pathogenic factor for severe pain of the lower limb as a result of nerve root compression. After reviewing these rare cases reported in the literature, we found that the name, pathogenesis, and treatment strategy of this pathology remained controversial. The most common treatment is conservative treatment or percutaneous aspiration which might result in poor pain relief and high recurrence rates. Moreover, the patient who received open surgery had good clinical outcome; however, he or she might experience a significant soft tissue injury.

In this study, we report the first case of a patient who had a giant epidural gas-containing pseudocyst and received percutaneous endoscopic surgery. This 57-year-old man had been complaining of severe radicular pain in his right ankle for one year. According to computed tomography (CT) and magnetic resonance imaging (MRI) prior to the surgery, the results showed an isolated epidural gas-containing pseudocyst was located in the right lateral recess of S1. At the last follow-up period, postoperative CT scan showed the gas-contained pseudocyst was completely resected and this patient was free from the pain.

Due to the great advances in endoscopic techniques and equipment, it is easier to perform lumbar surgery through the endoscope. With this first case of percutaneous endoscopic treatment for the symptomatic epidural gas-containing pseudocyst reported in this study, we believe that this surgical method provides an option to treat this rare condition because it provides sufficient decompression, has a low recurrence rate, and is minimally invasive.

Key words: Endoscopic surgery, pseudocyst, epidural gas, intraspinal gas, radiulopathy

Pain Physician 2017; 20:E445-E449

Nerve root compressed by gas-collection in the epidural space is rare and only limited cases have been reported. Different names have been used to describe this phenomenon, such as gas-containing prolapsed intervertebral disc, epidural gas cyst, gas bubble, and pneumatic nerve root compression, etc. (1-4). Most cases have asymptomatic nerve root compression. Here we report a case of severe radicular pain caused by giant gas-containing pseudocyst

in the epidural space treated with percutaneous transforaminal endoscopic surgery.

Case Report

History and Clinical Manifestations

This 57-year-old man presented with severe right radicular pain to the ankle for one year. It intermittently attacked, and standing and walking would ex-

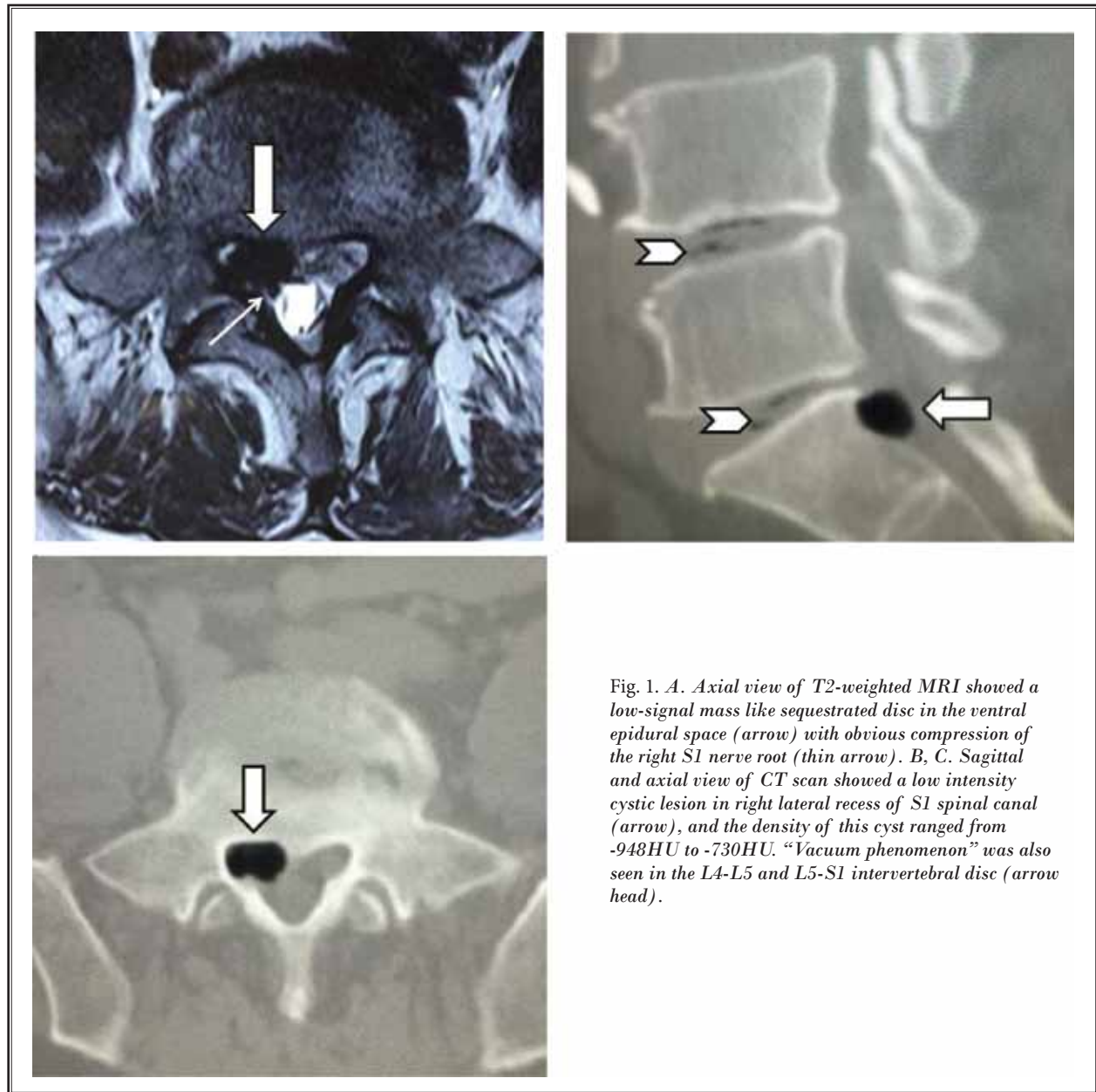


Fig. 1. A. Axial view of T2-weighted MRI showed a low-signal mass like sequestered disc in the ventral epidural space (arrow) with obvious compression of the right S1 nerve root (thin arrow). B, C. Sagittal and axial view of CT scan showed a low intensity cystic lesion in right lateral recess of S1 spinal canal (arrow), and the density of this cyst ranged from -948HU to -730HU. “Vacuum phenomenon” was also seen in the L4-L5 and L5-S1 intervertebral disc (arrow head).

acerbate the radicular pain while bed rest could partially alleviate it. Oxycodone, 10 mg, was taken orally per 12 hours to control the symptom. He denied any history of open surgery or intervention procedures to the spinal canal.

The straight leg raising test was positive at 45° on the right side and negative on the left side. The muscle strength and sensation of the bilateral legs were normal.

Imaging Manifestations

Before admission, this patient underwent magnetic resonance imaging (MRI) in another hospital. The T2WI MRIs showed a low-signal mass like a sequestered disc in the ventral epidural space with obvious compression of the right S1 nerve root (Fig. 1A).

The computed tomography (CT) scan showed a homogeneous epidural cyst with clear boundary, and the density of this cyst ranged from -948HU to -730HU.

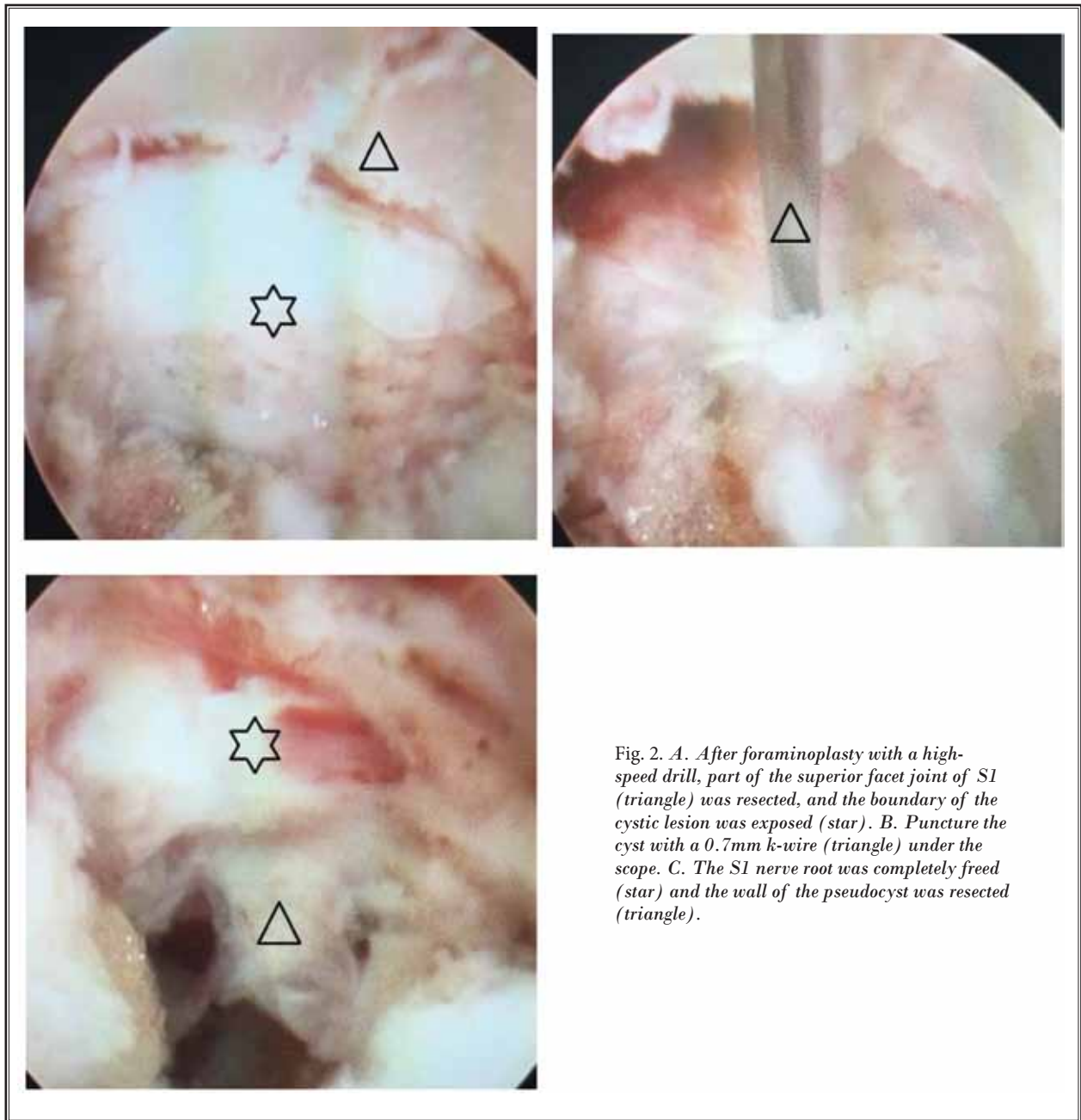


Fig. 2. A. After foraminoplasty with a high-speed drill, part of the superior facet joint of S1 (triangle) was resected, and the boundary of the cystic lesion was exposed (star). B. Puncture the cyst with a 0.7mm k-wire (triangle) under the scope. C. The S1 nerve root was completely freed (star) and the wall of the pseudocyst was resected (triangle).

“Vacuum phenomenon” was also seen in the L4-L5 and L5-S1 intervertebral disc (Fig. 1B, C).

Treatment

Percutaneous transforaminal endoscopic surgery was applied to this patient. The patient was placed in the lateral position. The Maxmore spine endoscopic system was used for the procedure. After insertion of

the working tube, we removed part of the superior facet joint and pedicle of S1 to expose the cyst with a high-speed drill (NSK, Japan). The intraoperative image showed a tension cyst in the right lateral recess (Fig. 2A). We then punctured the wall of the cyst with a 0.7 mm K-wire through the working channel of the endoscope (Fig. 2B). A large amount of gas bubbled up through the crevasse. The wall of the cyst was re-

sected by straight and bendable graspers. The ventral space of the right S1 nerve root was completely decompressed, and no disc-like tissue was found in the cyst (Fig. 2C).

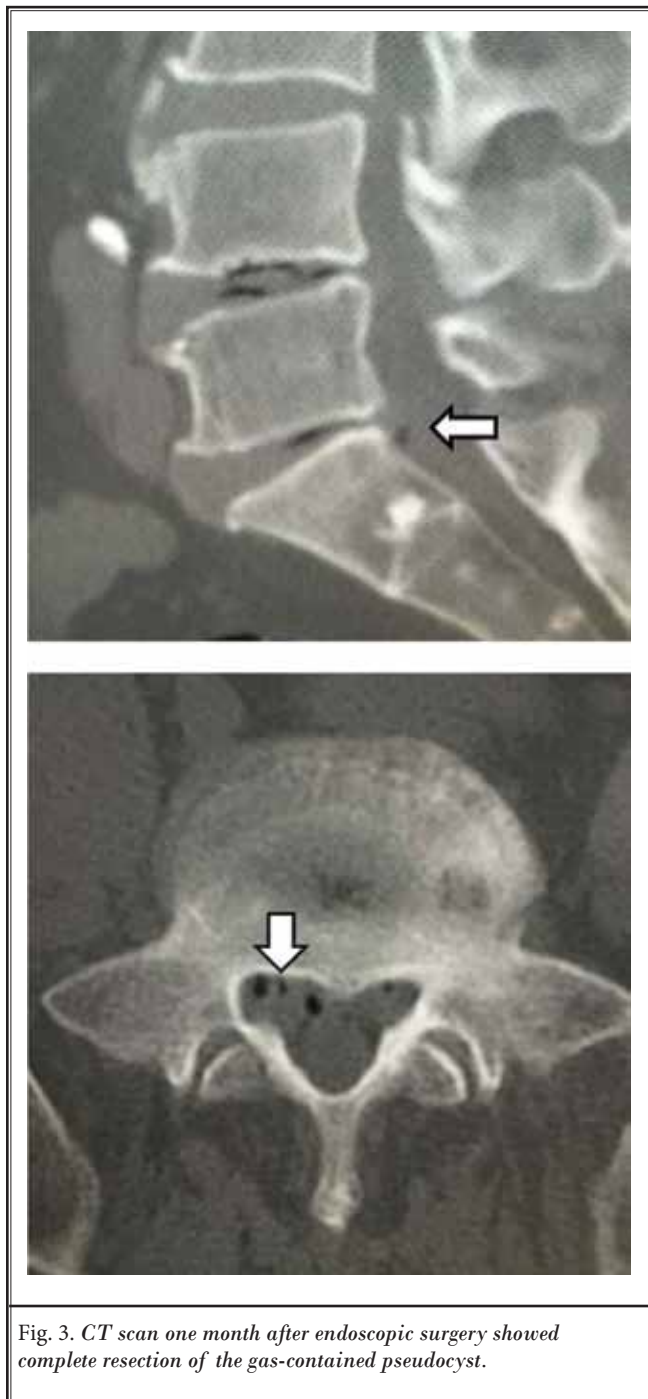


Fig. 3. CT scan one month after endoscopic surgery showed complete resection of the gas-contained pseudocyst.

Postoperative Course

The radicular pain immediately remitted when the cyst was punctured. Postoperative CT scan showed complete resection of the gas-contained pseudocyst (Fig. 3). The patient remained pain-free at the last follow-up.

Discussion

Air in the intervertebral disc, which is called the "vacuum phenomenon," is common in elderly patients with degenerative disc diseases (5). It was first described in 1942 by Knutsson et al. Since then, many authors tried to verify the pathogenesis, prognosis, and treatment strategy of this disease. Ford et al (6) confirmed that the main composition of intervertebral gas was nitrogen.

Compared with intervertebral gas, epidural gas is much rarer, and some authors believe that epidural gas is migrated from the intervertebral disc (vacuum phenomenon) following the motion of the spine and disc prolapse (7). Besides, other uncommon inducing factors such as previous open surgery, epidural intervention treatment, and infection in the intervertebral space were also reported (3). Most epidural gas-containing cysts reported were asymptomatic and coexisted with sequestered disc fragment. Severe radicular pain caused by isolated epidural gas cyst (so called gas-containing pseudocyst) was extremely rarely reported in the literature.

Treatment strategy for the symptomatic epidural gas-containing pseudocyst remained controversial. Lee et al reviewed 8 cases of symptomatic postoperative epidural gas in the literature and found that conservative treatment or percutaneous aspiration was the most common treatment, but it had poor pain relief and a high recurrence rate, while open surgery had good clinical outcomes and significant soft tissue injury (3).

Considering the interests of sufficient decompression, the low recurrence rate, and minimally invasive surgery, we performed percutaneous endoscopic surgery on the present patient. The advantages of the endoscopic procedure for the present patient were as follows: 1) local anesthesia, small skin incision (1 cm), and minimal soft tissue dissection; 2) targeted resection of the wall of the pseudocyst to avoid recurrence; 3) intraoperative straight leg raising test to confirm satisfied pain relief; and 4) faster postoperative recovery and shorter hospital stay.

CONCLUSION

Advances in endoscopic techniques and equipment have made more and more lumbar pathology surgically accessible. Indications for this minimally invasive procedure have expanded from prolapsed disc to foraminal stenosis, unilateral lateral recess ste-

nosis, and intradiscal infection (8-11). We report the first case of percutaneous endoscopic treatment for a symptomatic epidural gas-containing pseudocyst and look forward to more application of this technique on epidural cystic lesions.

REFERENCES

1. Tsitouridis I, Sayegh FE, Papapostolou P, Chondromatidou S, Goutsaridou F, Emmanouilidou M, Sidiropoulou MS, Kapetanios GA. Disc-like herniation in association with gas collection in the spinal canal: CT evaluation. *Eur J Radiol* 2005; 56:1-4.
2. Righini A, Lucchi S, Reganati P, Zavanone M, Bettinelli A. Percutaneous treatment of gas-containing lumbar disc herniation. Report of two cases. *J Neurosurg* 1999; 91:133-136.
3. Lee CW, Yoon KJ, Ha SS, Kang JK. Radicular compression by intraspinal epidural gas bubble occurred in distant two levels after lumbar microdiscectomy. *J Korean Neurosurg Soc* 2014; 56:521-526.
4. Salpietro FM, Alafaci C, Collufio D, Pas-salacqua M, Puglisi E, Tripodo E, Di PG, Tomasello F. Radicular compression by lumbar intraspinal epidural gas pseudo-cyst in association with lateral disc herniation. Role of the posterior longitudinal ligament. *J Neurosurg Sci* 2002; 46:93-95; discussion 95.
5. Gulati AN, Weinstein ZR. Gas in the spinal canal in association with the lumbosacral vacuum phenomenon: CT findings. *Neuroradiology* 1980; 20:191-192.
6. Ford LT, Gilula LA, Murphy WA, Gado M. Analysis of gas in vacuum lumbar disc. *AJR* 1977; 128:1056-1057.
7. Sasani M, Ozer AF, Oktenoglu T, Cosar M, Karaarslan E, Sarioglu AC. Recurrent radiculopathy caused by epidural gas after spinal surgery: Report of four cases and literature review. *Spine (Phila Pa 1976)* 2007; 32:E320-E325.
8. Choi KC, Kim JS, Ryu KS, Kang BU, Ahn Y, Lee SH. Percutaneous endoscopic lumbar discectomy for L5-S1 disc herniation: Transforaminal versus interlaminar approach. *Pain Physician* 2013; 16:547-556.
9. Lee S, Kim SK, Lee SH, Kim WJ, Choi WC, Choi G, Shin SW. Percutaneous endoscopic lumbar discectomy for migrated disc herniation: Classification of disc migration and surgical approaches. *Eur Spine J* 2007; 16:431-437.
10. Hoogland T, Schubert M, Miklitz B, Ramirez A. Transforaminal posterolateral endoscopic discectomy with or without the combination of a low-dose chymopapain: A prospective randomized study in 280 consecutive cases. *Spine (Phila Pa 1976)* 2006; 31:E890-E897.
11. Kim HS, Park JY. Comparative assessment of different percutaneous endoscopic interlaminar lumbar discectomy (PEID) techniques. *Pain Physician* 2013; 16:359-367.

