

## Original Contribution

### Percutaneous Disc Decompression Using Nucleoplasty®

Lewis S. Sharps, MD, FACS\* and Zacharia Isaac, MD\*\*

The objective of this study was to evaluate the effectiveness of Nucleoplasty for decompression of contained herniated discs, in a prospective, single site study that evaluated 49 consecutive patients with complaints of back with or without leg pain secondary to a contained focal protrusion.

Access to the disc was obtained via the posterolateral discography approach, with a 17-gauge introducer needle inserted through the annulus and into the nucleus. The introducer remained in place within the outer annulus during the entire procedure, providing access for the SpineWand into the nucleus. The procedure was performed on an outpatient basis. One month, three month, six-month and twelve month outcomes were assessed by the treating physician and support staff. Success was defined as a minimum 2-point reduction on a Visual Analog Scale (VAS), patient satisfaction, absence of narcotic use, and return to work if

not working secondary to back pain.

The pre-procedure and post-procedure VAS differences were 4.28 ( $p<0.001$ ), 4.66 ( $p<0.001$ ), 4.75 ( $p<0.001$ ), and 3.3 ( $p=0.002$ ) at the one month, 3 month, 6 month, and 12 month intervals respectively. Overall, there was a 79% success rate, with 67% success in the group of patients that had previous surgery and 82% success in the group that had no prior surgical intervention.

Results indicate that Nucleoplasty may be a promising and efficacious minimally invasive procedure for the treatment of symptoms associated with contained herniated discs. Randomized, controlled studies with subgroup analysis are required to further delineate the role for this procedure.

**Keywords:** Minimally invasive, percutaneous, decompression, nucleoplasty, herniated disc

Discogenic pain continues to represent a diagnostic dilemma for spine specialists secondary to the difficulty of accurately verifying the pain generator. In addition, there is uncertainty as to whether discogenic pain is mediated via chemical, mechanical, neural, or a combination of the above mechanisms. Although the majority of patients improve with conservative, non-invasive therapy, numerous patients continue to experience functionally limiting pain. Open surgical procedures are available for treatment of discogenic disease, however these procedures represent a small but palpable perioperative risk. It therefore, becomes increasingly important that spine surgeons consider minimally invasive procedures for these patients, and allow for the progression to more invasive interventions should they become necessary.

Nucleoplasty has the theoretical advantages of prior percutaneous techniques for disc decompression such as chemonucleolysis (chymopapain), automated percutaneous lumbar discectomy and laser discectomy. Simultaneously, it may not have the associated complications and side effects of these previously performed techniques.

It was less than 70 years ago that the landmark paper by Mixter and Barr (1) clearly established the relationship between herniated discs and sciatica. This paper provided evidence that laminectomy and disc excision could successfully relieve pain associated with radiculopathy. Through evolution of surgical technique, present day microdiscectomy is now performed through a 2-3cm incision. During discectomy, surgeons rarely remove more than 30% of disc material. It was in 1987 that Williams reported on his series of microdiscectomy patients and reinforced the clinical perception that successful outcome of disc surgery was independent of the amount of disc material excised (2).

The desire for minimally invasive options for treatment of spine pain lead to numerous percutaneous techniques for disc decompression. Hijikata (2) in Tokyo first performed percutaneous discectomy in 1975. He reported in 1978

From the Department of Orthopedic Surgery and Sports Medicine Group; Hospital of University of Pennsylvania.  
\*Director of Orthopedic Surgery and Sports Medicine Group and \*\*fellow at Penn Spine Center at the University of Pennsylvania. Address correspondence: Lewis S. Sharps, MD, FACS, 100 First Avenue, Phoenixville, PA 19460.

Disclaimer: There was no outside financial support for this project.

that good to excellent results had been achieved in 68% of 80 patients treated with a posterolateral percutaneous approach. Intradiscal chymopapain injection, chemonucleolysis, rapidly became popular after its FDA approval in 1981. Within 6 months of chymopapain receiving FDA approval, 75,000 cases were performed in the USA with a 70% success rate. Unfortunately, chymopapain had the potential risk of paralysis secondary to transverse myelitis and an anaphylaxis rate estimated at 0.3-0.5%. These risks far outweighed the potential benefit of this procedure (3).

In 1984 Onik and Maroon (4) sought an alternative method for percutaneous disc removal. This automated percutaneous lumbar discectomy technique utilized a 20.3 cm needle inserted through a 3 mm canula. The first large series of percutaneous discectomy patients were reviewed and a success rate of 75% good to excellent outcomes was reported (4). Automated percutaneous lumbar discectomy further supported the previous conclusions that the outcome of disc excision was independent of the quantity of disc material removed. At approximately the same time Choy's (5) work on YAG laser discectomy yielded comparable results. Choy's (5) concept was based upon the hydraulic model of disc function. He put forth the theory that a small change in disc volume could result in a large change in disc pressure. The first author's experience with KTP laser discectomy and APLD correlated with the above studies yielding approximately 70% good to excellent outcomes. However, disadvantages of this technique included moderate to severe intraoperative pain secondary to the thermal effect of the laser, postoperative low back pain and spasm, and inability to visualize the tip of the laser beam under fluoroscopy.

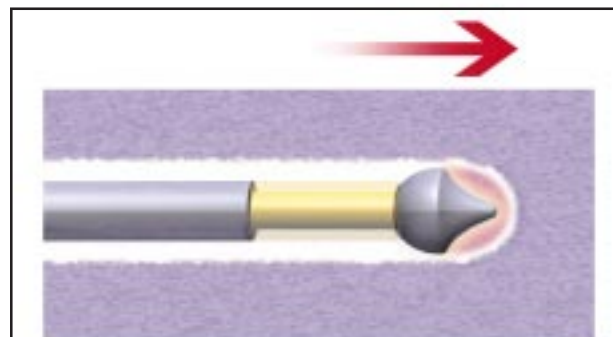
Intradiscal electrothermal annuloplasty (IDET) began to be performed in 1998 and represented a deviation from the focus on disc decompression. Saal and Saal (6) put forth a new theory of "annuloplasty." The concept was that thermal heating of the annulus could seal annular tears and denervate the annulus by destroying the Type C afferent nerve fibers that innervate the outer one third of the annulus (6). Collagen fibers are typically arranged in a triple helix. At 70C the collagen fibers denature and form random coils with intermittent cross-links with contraction of collagen fibers. The literature demonstrates that temperatures above 45° C are required to destroy the Type C afferent nerve fibers (6). The IDET technique requires threading a curved resistive heating wire around the posterolateral annulus under fluoroscopic guidance. The wire is then heated to 90° C, in theory accomplishing an

annuloplasty.

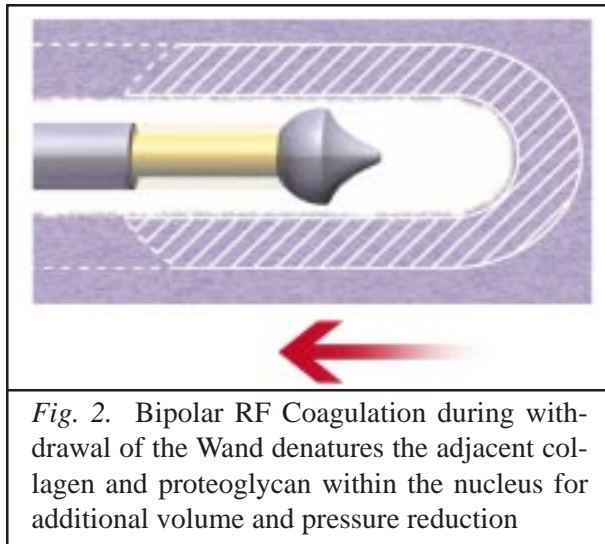
Several reasons exist for skepticism regarding the IDET procedures' mechanism of action, efficacy, and potential side effects (7). The concept of annular sealing had no historical precedent of therapeutic efficacy in the spine literature. Kleinstueck et al (7) demonstrated that during the IDET procedure, annular temperatures never reached the necessary 70° C necessary for collagen contraction. Thermocouples also demonstrated only sporadic annular temperatures of 45° C, insufficient to destroy afferent nerve fibers (7). Additionally, the technical difficulties involved in threading a curved 30 cm wire around the annulus may represent a potential for annular perforation.

The major drawbacks with IDET to date have been its' questionable efficacy, the amount of time necessary to thread the wire, and the amount of intraoperative pain experienced by patients during the procedure when the annulus is heated. Patients have also complained of significant postoperative back spasm necessitating the use of back braces and subsequent delay in the implementation of postoperative rehabilitation.

Nucleoplasty utilizes the Perc-D SpineWand, which is a 1mm diameter bipolar instrument designed for decompression of the disc nucleus utilizing both energy and heat. The tip of the wand has a slight C curve to allow for channeling. The wand is connected to the standard Arthrocare power generator. Nucleoplasty utilizes Coblation® technology which has found applications in other areas of medical care (8, 9). This process generates a unique low temperature plasma field, for precise, controlled ablation with minimal risk of thermal injury. Ablation generates approximately 120 Volts of energy at the tip of the wand with resultant tip temperatures of 50-70 degrees C. A plasma field is generated at the tip, which is a millimicron thick field of



*Fig. 1. Ablation – Advancing the Wand creates a small, controlled channel in the nucleus*



*Fig. 2.* Bipolar RF Coagulation during withdrawal of the Wand denatures the adjacent collagen and proteoglycan within the nucleus for additional volume and pressure reduction

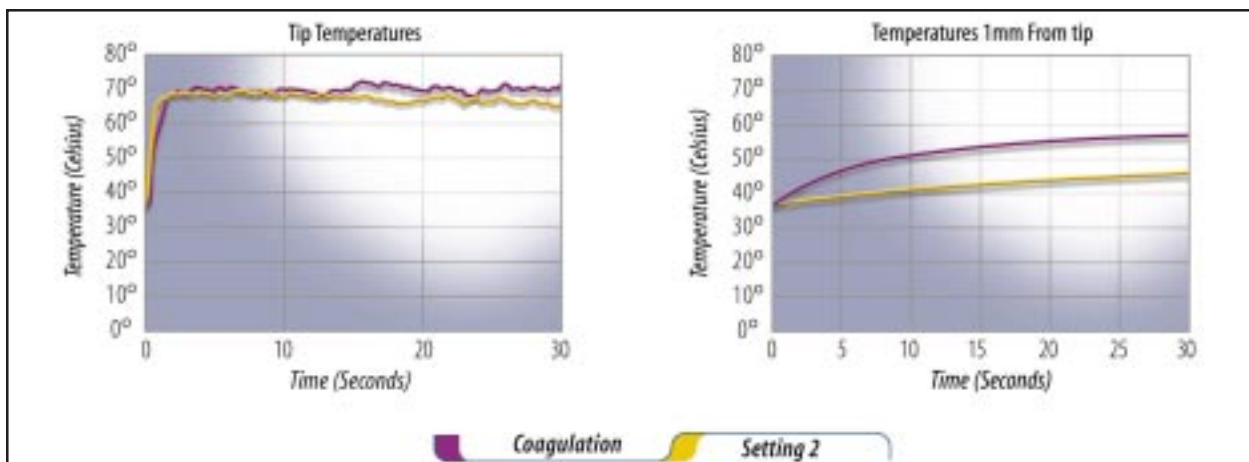
highly energized particles that result in molecular dissociation of the disc material directly in front of the tip (10). This creates a channel from the posterolateral annulus to the anteromedial annulus (Fig. 1). On the withdrawal, the coagulation mode is used (Fig. 2). The coagulation mode is 60V of energy and a tip temperature of 70 degrees C. On exit the thermal effect results in denaturation of the Type II collagen with resultant shrinkage of the surrounding collagen and widening of the channel (Fig. 3).

**METHODOLOGY**

Patients were recruited and data was collected on a prospective basis. Patients had to satisfy specific inclusion and exclusion criteria to be enrolled. Inclusion criteria

were complaints of back with or without radicular pain, and failure six weeks of conservative care. Conservative care was comprised of the use of posture and activity modifications, physical therapy focusing on lumbar stabilization exercises, and oral NSAIDs. If patients had low back pain without radicular symptoms, conservative care also included the use of epidural steroid injections. Patients must have undergone 6 weeks of conservative care prior to undergoing Nucleoplasty. The exceptions to this rule were instances where the pain was functionally incapacitating and refractory to the use of oral narcotics. Exclusion criteria were the presence of a sequestered herniation, a contained herniation that was larger than 1/3 the sagittal diameter of the spinal canal, spinal stenosis, the presence of progressive neurological deficits, tumor, infection, spinal fracture, or participation in any other drug or device study.

All patients with axial low back pain without radicular symptoms underwent provocative discography to confirm concordant pain prior to Nucleoplasty. Nucleoplasty was performed on an outpatient basis with fluoroscopic guidance and local anesthesia. Patients were positioned in a prone or decubitus position. The involved disc space was localized under fluoroscopic guidance and the soft tissues are infiltrated with local anesthetic approximately 8-10 cm from the midline. A 17-gauge needle was then introduced into the posterolateral corner of the disc using a posterolateral extrapedicular approach. The AP projection was checked to determine that the needle had not transgressed the transpedicular line. The 17-gauge needle was then introduced through the annulus and the spine wand was inserted through the needle (Fig. 4). A total of 6 channels were created at the 2, 4, 6, 8, 10 and 12 o'clock positions.



*Fig. 3.* Temperature curves measuring from the tip of the Perc-D wand demonstrate a steep drop which minimizes the risk of inadvertent heating of the annulus or vertebral endplates

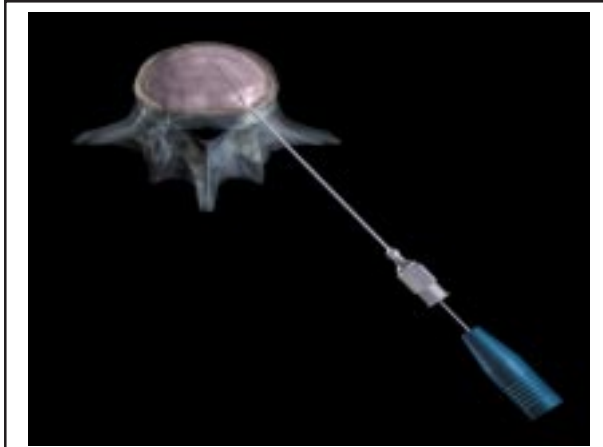


Fig. 4. Device at the anterior annulus of the disc

Because of the C shaped curve at the tip of the wand these six channels decompress a cone shaped area of nucleus (Fig. 5). The 1mm skin incision was then closed with Steri-Strips and patients were discharged to home within one hour of the procedure. Patients received periprocedural antibiotic prophylaxis. 1 gm of intravenous Cefazolin was infused prior to the procedure, and patients received 500 mg of oral Cephalexin every 6 hours for 48 hours. Patients with penicillin or cephalosporin allergy received 400 mg of intravenous ciprofloxacin prior to the procedure and 500 mg orally twice a day for 48 hours.

Postoperatively patients were allowed unlimited walking, standing and sitting. Patients were instructed not to perform any lifting, bending or stooping. Return to sedentary or light work was permitted at 3-4 days following the surgery. The patient was instructed in gentle flexion and extension home exercises at the first postoperative office visit. Formal physical therapy with an emphasis on lumbar stabilization exercises started at 3-weeks post procedure.

Questionnaires were filled out by the patient pre-procedure, and at one month, three months, six months and one year post-procedure. The treating physician and clinical support staff performed assessments at the above intervals. Demographics, along with information regarding occupational status, prior surgery and narcotic usage were collected at the time of study enrollment. A Visual Analog Pain Scale (VAS) was administered at all visits. The procedure was considered a success if all of the following criteria were met: a 2-point reduction on the VAS scale, patient satisfaction, absence of narcotic use, and return to work if the patient was not working secondary to back pain complaints. Patient satisfaction was measured on a scale

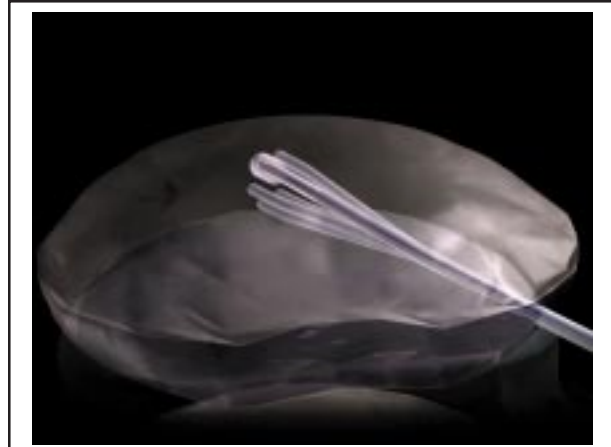

Fig. 5. Six channels decompress a cone shaped area of the nucleus

from 0 to 4 with 0=unsatisfactory, 1=satisfactory, 2=good, 3=very good, 4=excellent. Satisfaction score greater or equal to a 1 was considered a success for this parameter. Patients were considered a failure if they did not meet all 4 of these criteria or went on to surgery. Patients who went to surgery were included in the analysis of outcomes.

## RESULTS

Our preliminary results are presented below. Data collection is ongoing. A total of forty-nine patients underwent the Nucleoplasty procedure. Nine of these patients had prior surgeries. Four patients had prior fusions, four had prior percutaneous disc procedures, and one patient had undergone a prior lumbar laminectomy. Forty-nine out of forty-nine patients have been followed for one month, with forty-one followed for three months, twenty-four followed for six months and thirteen patients followed at twelve months. The twenty-six men and twenty-three women had a mean age of 38 years old, with ages ranging between 30-61 years old. The average duration of symptoms prior to Nucleoplasty ranged from 1 month to 252 months with a mean of 38 months. One patient was lost to follow up.

VAS score data was analyzed using a two-tailed paired student-t test, with a p-value of <0.05 being considered statistically significant. VAS scores demonstrated statistically significant improvement at the one, three, six, and twelve-month follow-up visits when compared with baseline values. The pre-procedure mean VAS scores was 7.9 +/- 1.3 (range 3-10). At one month, the mean VAS score was 3.6 +/- 2.6 (range 0-9). At 3 months the mean VAS score was 3.1 +/- 2.7 (range 0-9). At 6 months, the mean VAS score

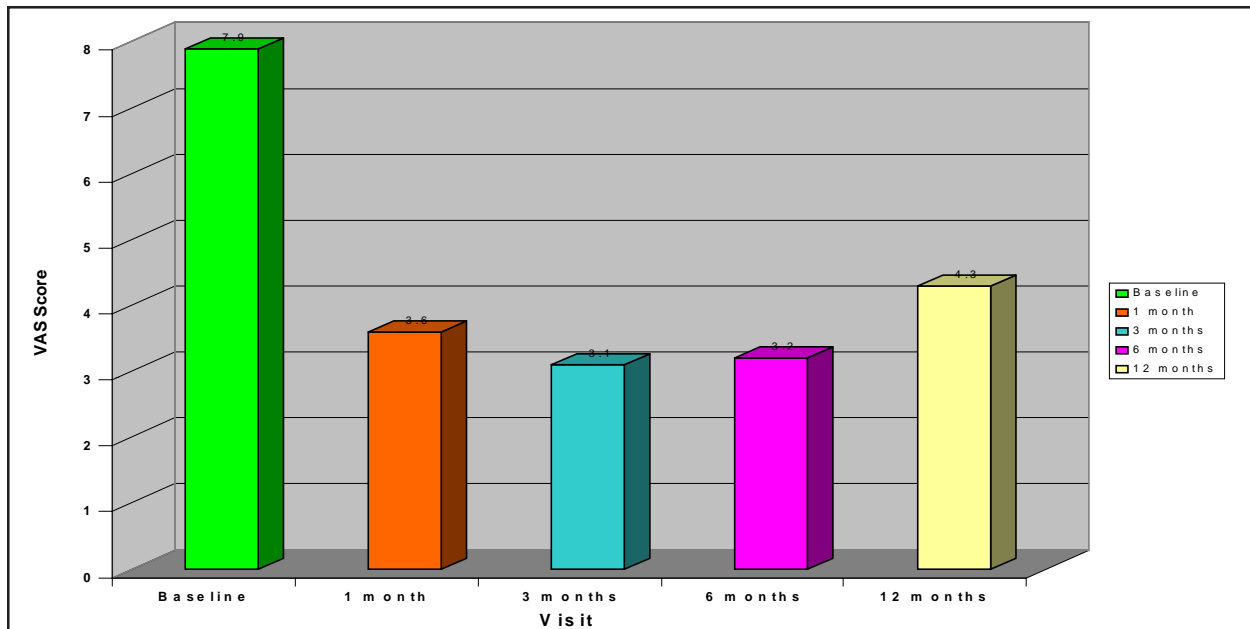


Fig. 6. Mean VAS scores at follow-up visits

was 3.2 +/- 2.8 (range 0 to 9). At 12 months, the mean VAS score was 4.3 +/- 2.8 (range 0 to 9) (Figure 6). The pre-procedure and post-procedure VAS differences were 4.28 (p<0.001), 4.66 (p<0.001), 4.75 (p<0.001), and 3.3 (p=0.002) at the one-month, 3-month, 6-month, and 12-month intervals respectively. Pre-procedure and the most recent post procedure VAS scores are illustrated in figure 7. Patient satisfaction was measured at the 3 month inter-

val on a scale from 0 to 4 with 0= unsatisfactory, 1= satisfactory, 2=good, 3= very good, 4= excellent. The mean post-procedural satisfaction score was =2.14. Overall, there was a 79% success rate. In the group that had previous surgery, the success rate was 67%, versus 82% in the group that had no previous surgical intervention. No post-procedural complications were observed.

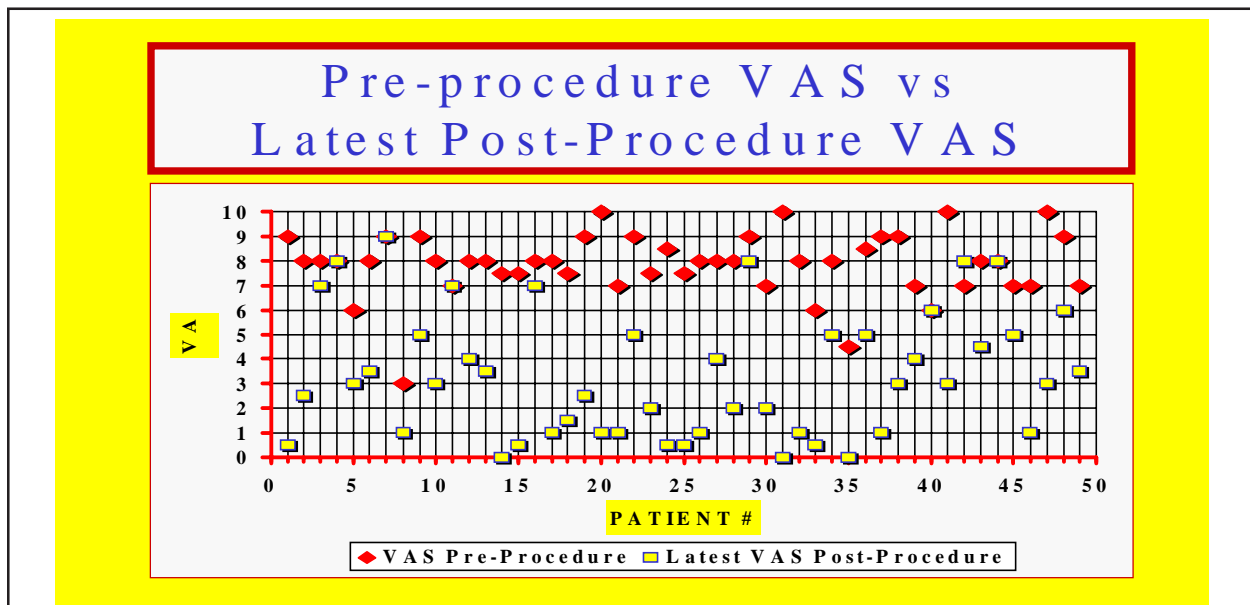


Fig. 7. Comparison of pre and latest post procedure VAS

**Table 1.** Suggested selection criteria for Nucleoplasty**Radicular/Axial Pain**

Leg pain > back pain  
 MRI evidence of contained herniated disc protrusion  
 Discography, if indicated  
 Failure of 6 weeks of conservative therapy

**Axial Back Pain**

MRI evidence of contained disc protrusion  
 Discography positive for concordant pain  
 Failure of 6 weeks of conservative therapy

**Contraindications**

Severe degenerative disc with greater than 33% loss of disc height  
 Herniation larger than 1/3 the sagittal diameter of the spinal canal  
 Disc extrusion or sequestration  
 Moderate/severe spinal stenosis  
 Tumor, infection, fracture

**CONCLUSION**

Although long-term data are not available, our initial data indicates that Nucleoplasty is a promising option for symptomatic patients with contained herniated discs. As well, there were no adverse events in patients enrolled in this study. Based on this experience with the Nucleoplasty procedure, our recommendations for selection criteria for the Nucleoplasty procedure are listed in the Table 1. Prospective, randomized, controlled studies investigating long-term

outcomes of this procedure with subgroup analysis would help delineate for whom this procedure is helpful.

**REFERENCES**

1. Mixer WJ, Barr JS. Rupture of the intervertebral disc with involvement of the spinal canal. *New Engl J Med* 1934; 211:210-215.
2. Hijikata S. Percutaneous nucleotomy. A new concept technique and 12 years' experience. *Clin Orthop* 1989; 238:9-23.
3. Brown MD. Update on Chemonucleolysis. *Spine* 1996; 21:62S-68S.
4. Onik G, Maroon J, Helms C et al. Automated percutaneous discectomy: initial patient experience. Work in progress. *Radiology* 1987; 162:129-132.
5. Choy DS, Altman P. Fall of intradiscal pressure with laser ablation. *J Clin Laser Med Surg* 1995; 13:149-151.
6. Saal JS, Saal JA. Management of chronic discogenic low back pain with a thermal intradiscal catheter. *Spine* 2000; 25:382-389.
7. Kleinstueck FS, Diederich CJ, Nau WH et al. Acute biomechanical and histological effects of intradiscal electrothermal therapy on human lumbar discs. *Spine* 2001; 26: 2198-2207.
8. Yetkinler D, Bessette A, Wolozko J. A novel radiofrequency technology (coblation) for dermatologic surgery applications. *Proceedings of BIOS/SPIE Annual Meeting*, San Jose, CA January 2002.
9. Yetkinler D, Lee K, Brandt L et al. A novel radiofrequency technology (coblation) for ear, nose and throat surgery applications. *Proceedings of BIOS/SPIE Annual Meeting*, San Jose, CA January 2002.
10. Stalder KR, Wolozko J, Brown IG et al. Repetitive plasma discharges in saline solutions. *Appl Physics Lett* 2001; 79:1-3.