

Retrospective Analysis

Musculoskeletal Ultrasonography in CRPS: Assessment of Muscles Before and After Motor Function Recovery with Dry Needling as the Sole Treatment

Lakshmi Champak Vas, MD, Renuka Pai, Dipl Anesth, and Manorama Pattnaik, MD

From: Ashirvad Institute for Pain Management and Research, Mumbai, India

Address Correspondence:
Dr. Lakshmi Vas
M.D Anesthesia
Ashirvad Institute of Pain Management and Research
Plot.No.117, Shubh Ashirvad,
Road No. 5
Hindu Colony, Dadar East,
Mumbai – 400 014
E-mail:
lakshmi@paincareindia.com

Disclaimer: There was no external funding in the preparation of this manuscript.
Conflict of interest: Each author certifies that he or she, or a member of his or her immediate family, has no commercial association (i.e., consultancies, stock ownership, equity interest, patent/licensing arrangements, etc.) that might pose a conflict of interest in connection with the submitted manuscript.

Manuscript received: 02-26-2015
Revised manuscript received: 07-03-2015
Accepted for publication: 07-10-2015

Free full manuscript:
www.painphysicianjournal.com

Background: Motor impairment is an important criterion in the Clinical Diagnostic Criteria (CDC) of Complex Regional Pain Syndrome type-1 (CRPS-1) as defined by International Association for Study of Pain (IASP).

Objective: To describe the changes in musculoskeletal ultrasonography (MSKUSG) in CRPS-1 before and after treatment with ultrasound-guided dry needling (USGDN) in retrospective data from 44 patients.

Study Design: Patients irrespective of age, gender, or cause of CRPS were included in this retrospective data analysis; the Budapest criteria for the diagnosis of CRPS were stringently adhered to.

Setting: The analysis was done at Ashirvad Institute for Pain Management and Research with the database of CRPS patients who were treated between December 2005 and December 2014.

Methods: The CDC, range of motion at upper extremity joints, dynamometry, Disability of arm, shoulder and hand score (DASH) and ultrasonography were documented on days one, 15, and 45. MSKUSG demonstrated loss of myoarchitecture and reduced bulk.

Results: All 44 patients received USGDN as the sole intervention with medications and physiotherapy. MSKUSG at 15 and 45 days after starting USGDN showed a return of normalcy to the myoarchitecture and muscle bulk increase that coincided with the disappearance of CDC and a progressive and predictable improvement of the DASH scores in all the 44 patients.

Limitation: The analysis focuses on only 2 parameters: the musculoskeletal changes of the forearm flexors and extensors on ultrasound guidance and the efficacy of the dry needling treatment. It is not a comparative study with another accepted form of treatment or intervention. We have not looked into the age and gender predilection of the condition owing to the small sample size of the study. Analysis of long term maintenance of relief and rehabilitation of the disability were limited to one year.

Conclusion: Myofascial pathology of co-contraction appears to cause CDC of CRPS and probable ischemic loss of myoarchitecture. Relief of co-contraction with USGDN allowed resolution of tenosynovitis causing the CDC and return of normal myoarchitecture.

Key words: CRPS-1, co-contraction, motor impairment, disability, dry needling, musculoskeletal ultrasonography

Pain Physician 2016; 19:E163-E179

Motor impairment is an important criterion in the Clinical Diagnostic Criteria (CDC) of Complex Regional Pain Syndrome type-1 (CRPS-1) as defined by the International Association for Study of Pain (IASP) (1,2). We have reported in 2 separate publications the concept of using dry needling as a specific modality to address the motor impairment which we believe is the primary problem with CRPS, responsible for the severe disability, and is a constant feature of CRPS (3-7). We believe that motor impairment is the primary pathology of CRPS, more important than alterations in blood flow, temperature disparity, trophic signs, tactile allodynia, and hyperalgesia/hyperesthesias. We further believe that vasomotor, sudomotor, and edema abnormalities that form the CDC of CRPS are secondary to myofascial abnormality. Musculoskeletal ultrasonography (MSKUSG) has shown great potential in providing objective evidence of motor impairment. We have reported the diagnostic utility of MSKUSG in 18 CRPS-1 patients as well as its efficacy in differentiating between neuropathic pain and CRPS (3,4). We have been using ultrasound guided dry needling (USGDN) of upper extremity muscles as a specific treatment modality to treat the myofascial issues in CRPS. The logic of using USGDN was that there was a constant co-contraction of digital flexors and extensor muscles which impedes all hand movements. Attempted movements of the tethered muscles lead to friction at the digital tendinous sheaths resulting in a de Quervain stenosing tenosynovitis (DQST) like inflammation in all the tendons of the hand. This global tenosynovitis (tendinosis is a better description, as there is no infection) gives rise to a clinical picture of hot, swollen, red hand of early CRPS. The temperature disparity, vasomotor, and sudomotor abnormalities that form the CDC of CRPS are actually signs of inflammation from the mechanical tendinosis. USGDN of the co-contracted muscles in the forearm would relax the muscles to replace the abnormal co-contraction with normal coordination between the agonist and antagonist muscles of hand movements. Relaxation of digital tendons and return of agonist and antagonist coordination would automatically reduce the friction and resolve the inflammatory tendinosis in the hand, thereby reversing the pain, vasomotor, sudomotor, as well as sensory features that comprise the CDC. We have reported the case of a young woman whose CRPS was mistaken for DQST (5). One of our reports details the successful reversal of bilateral CRPS in 5 patients with dry needling (DN) as the main component of a novel

multi-modality treatment regimen (6). In this report we showed bilateral CRPS (one limb was more affected than the other) in different phases of the disease. In another report we resolved the initial CRPS 2 and then the patient required corrective surgery for a residual ulnar claw 2 years later. We anticipated a probable recurrence of CRPS and hence provided a continuous brachial plexus block (CBPB) in an attempt to pre-empt the development of repeat CRPS. This patient did develop CRPS in spite of the CBPB but USGDN could reverse it. This kind of predictable reversal of CRPS is unheard of in CRPS literature (7). In the present article, we have highlighted the utility of MSKUSG in ascertaining and assessing the initial loss of myoarchitecture as well as in documenting the restoration of its normalcy by treatment with DN. The reversal of muscle abnormality on MSKUSG in 44 patients was associated with a demonstrable objective clinical improvement of all the CDC as well as of disability which is the most recalcitrant problem of CRPS. The complete and lasting resolution of all the CDC strongly suggested that the myofascial contribution to CRPS was the primary pathology giving rise to a mechanical tendinosis-like picture in the hand with pain, sensory, vasomotor, and sudomotor manifestations that dominate the clinical presentation of CRPS.

METHODS

Pre-treatment MSKUSG of the affected forearm muscles was performed in 60 patients who presented with CRPS-1 of the upper extremity (Budapest criteria) (Table 1). Fifty patients agreed to our treatment protocol but 6 stopped treatment before the 45 day assessment by MSKUSG. Hence this retrospective analysis includes MSKUSG data from 44 patients.

MSKUSG (Sonosite TM S-MSK, USA, linear 6 – 13 MHz transducer) was performed in the axial view in the flexor and extensor compartments of the normal and CRPS-affected forearm. The axial view was preferred because the qualitative features of muscle sonoanatomy are better appreciated in this view. The probe was positioned parallel to the elbow joint over the maximal bulk of flexor muscles ensuring that it was perpendicular to the skin to have a similar consistency in echogenicity (Fig. 1). The probe was moved medially and distally until all the flexor muscles were visualized with the pronator teres towards the pointer dot. The depth was adjusted so that the dense hyperechogenic outlines of the radius and ulna were visible in every reading. In the extensor compartment, the edge of the brachioradialis,

Table 1. Patient demographics and CRPS details.

There were 44 patients in total. DN was the sole interventional modality along with medications and physiotherapy.	
Age	24 – 80 years, mean (51 + 18.8)
Gender	20 men and 24 women
CRPS duration at 1st visit	12 presented in the first 3 months with florid CRPS- 8-10NRS pain and sleep disturbances. The motor features were present but were attributed by patients to the pain and sudomotor, vasomotor features that dominated the clinical presentation. 15 presented between 3-6 months with 4-5 NRS rest pain, sleep disturbances, sudomotor, vasomotor and motor features. 11 presented at 6-9 months with 0-5 NRS pain at rest, insignificant sleep disturbances, intermittent sudomotor, vasomotor asymmetry but very dominant motor features like severe stiffness with various degrees of flexion deformity at the MPJ and IPJ. 6 presented after more than 9 months of CRPS 0-5, NRS pain at rest, insignificant sleep disturbances, intermittent sudomotor, and vasomotor asymmetry. Variable degrees of ankyloses and flexion deformities at the MPJ and IPJ were present.
Etiological factors	24 patients had trauma + fracture + surgery + immobilization. 10 patients had trauma + fracture + immobilization. 4 patients had soft tissue trauma+ immobilization. 4 patients had spontaneous shoulder hand syndrome. 1 patient had cervical spine TB 8 months prior. 1 patient had herpes zoster involving C6-7.

radius, and ulna were kept in view. The normal forearm muscles were first documented and corresponding locations were considered to represent the same muscles on the CRPS-affected forearm. This helped us identify the CRPS affected muscles which are characterized by a loss of normal myoarchitecture in some or all muscles (4). The specific USG features considered for comparison were the general appearance, outline, the muscle bulk measured with the in-built calipers, any smudged or hazy appearance indicative of edema, and anechoic areas indicative of fluid collection in the muscles or around the tendons. The muscle echogenicity was specifically documented.

The protocol for assessing the clinical features included the following:

1. Rest and movement pain were separately rated on a Numerical Rating Scale (NRS) from “no pain” (0 NRS) to “worst imaginable pain” (10 NRS).
2. Range of motion (ROM) at the shoulder, elbow, wrist, metacarpophalangeal (MPJs), proximal, and distal interphalangeal joints (PIPJs and DIPJs, respectively) were documented using a goniometer (Fig. 2).
3. Grip strength of each hand and individual fingers was measured using a dynamometer and pinch gauge (Fig. 2).

Patients were also assessed for the presence or absence of the CDC, like weakness, stiffness, tremors, coord-

ination deficits, dystonic movements (motor); edema, sweating (sudomotor); and redness and temperature changes measured using skin thermometer (vasomotor). The Disability of the Arm, Shoulder, and Hand (DASH) score (8) was used to assess the patient's ability to perform the simple and complex daily activities of life that require considerable hand dexterity, coordination, and power. CDC parameters were again assessed along with MSKUSG on days 15 and 45 (Figs. 1, 3-7).

Medications included daily 75 – 150 mg of pregabalin (Lyrica, Pfizer India) and a combination of tramadol (37.5 mg) and paracetamol (375 mg) (Dolonat, Pfizer India) twice daily. Patients were allowed to take the extended release preparation of diclofenac if pain exceeded 4 – 5 on the NRS at any time.

All patients received uniform physiotherapy (PT) protocol supervised by a certified physiotherapist and included initially electrical modalities, myofascial release, and muscle stretching. Strengthening exercises were started only after the complete disappearance of rest pain and the movement pain had reduced by 50% that usually occurred after the first 7 – 10 days.

The DN protocol involved thrice weekly needling of the neck and the extremity for up to 45 – 60 days (details in Table 2). USGDN included all the muscles of the upper extremity including the neck and shoulder girdle. The extensor aspect of the extremity and the neck was needled in a single sitting, while the flexor aspect of the limb and the pectoral muscles were addressed in the next session. The needles were introduced at 1 – 2

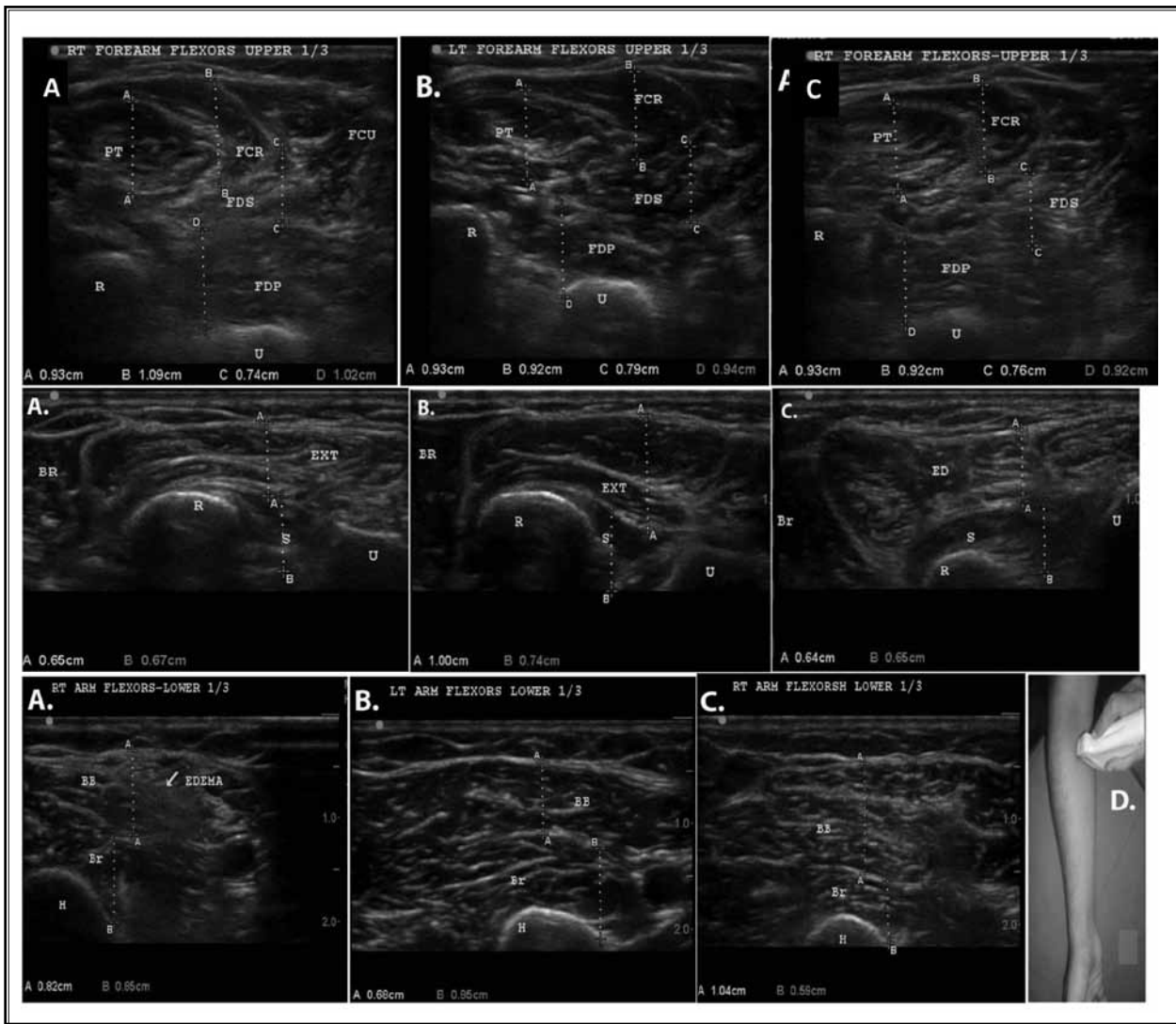


Fig. 1. First row: Digital flexors of the CRPS affected right extremity. The images in each row in this and in the following figures are referred to as A B, C, D, E and F from left to right.

1st row A: The muscle architecture of the CRPS affected flexor digitorum superficialis and profundus is completely lost. Muscle edema is seen in flexor digitorum superficialis and profundus which makes the size 1.76 cm appear a little more than the normal left forearm size of 1.74 cm. The characteristic sonographic signature of hypoechoic muscle fibers with streaks of hyperechoic fascial framework is unclear. Instead, the muscles are ill defined with no distinct outline. Image C shows that after 45 days there is no edema in digital flexors, which have the same size as the normal left forearm.

Row 2: Shows the extensors of right hand thinner than those of left hand (B). The right corner image shows that after 45 days digital extensors show a clearer outline but a persistent hyperechogenicity.

Row 3: Muscle edema is seen in biceps, brachialis that has made the muscles appear thicker compared to normal left arm. 0.82 cm compared to 0.68 cm of left biceps. Image C shows the CRPS affected biceps at 45 days. Note the return of muscle architecture with well-defined outline and disappearance of muscle edema. The biceps and brachialis without any edema at 45 days have acquired more bulk 1.04 cm as compared to the 0.82 cm. Image D: The right corner image shows the positioning of the USG probe. The depth was adjusted to include the dense hyperechogenic outlines of both radius and ulna with a hypoechoic/anechoic shadow beneath, in all the USG assessments.

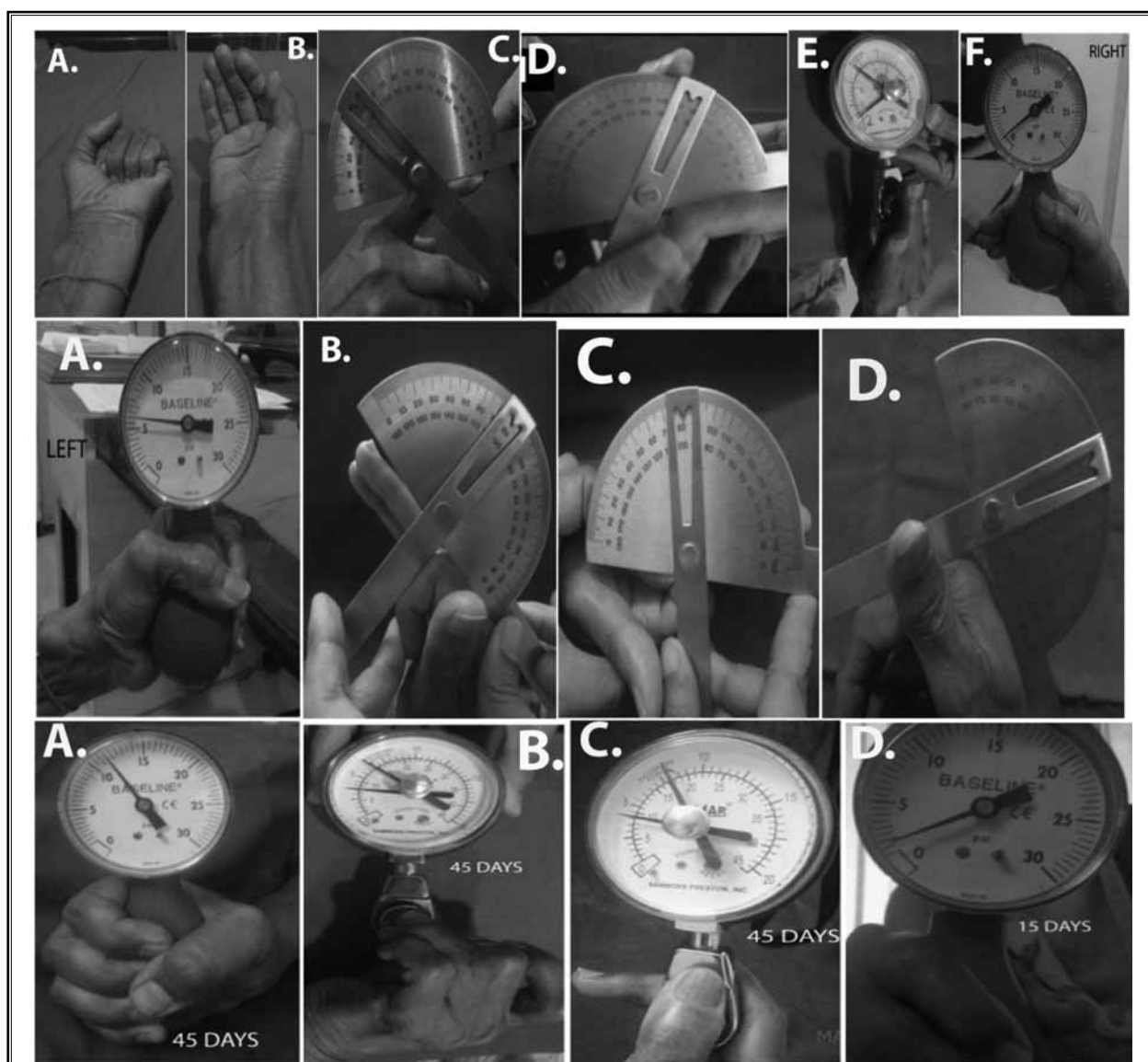


Fig. 2. A 72-year-old lady developed CRPS-type 1 of the right upper extremity 6 months after Colle's fracture. Initiation of hand movements after plaster cast removal (immobilization for 6 weeks) had led to pain (5–6 NRS), swelling, redness, weakness, and stiffness associated with dystonic movements, along with positive objective examination findings which fulfilled the clinical diagnostic criteria of CRPS. Physiotherapy, analgesics (NSAIDs and tramadol), Ibuprofen, vitamin D3, and calcium had proved ineffective in relieving stiffness or pain.

First row (R1): Shows right hand in mild fixed flexion deformity at MPJ and IPJ with total inability to make a fist. ROM was restricted to 30–40° at metacarpophalangeal joint, 40–45° at proximal and distal interphalangeal joints, and 15° of wrist extension. The goniometric readings at the distal and middle interphalangeal joints of the index finger of right hand are 50° instead of the normal 80°. Recorded temperature was 36°C in both hands. Her finger tips were unable to purposefully exert the requisite pressure on the pinch gauge. She was unable to wrap the right hand around the dynamometer bulb to press it effectively. Hence the reading was zero.

Second row: In contrast, the normal left hand shows 7 psi grip strength. At 45 days the ROM has improved in the metacarpophalangeal and interphalangeal joints to > 90° from the original 40–45° on the goniometer.

Third row: The pinch gauge and dynamometer measurements in the same patient. There are 2 dynamometer measurements at 15 and 45 days. Initial inability to grasp the bulb progressed to 2 psi at 15 days and 11 psi at 45 days. The pinch gauge readings also show a distinct improvement.

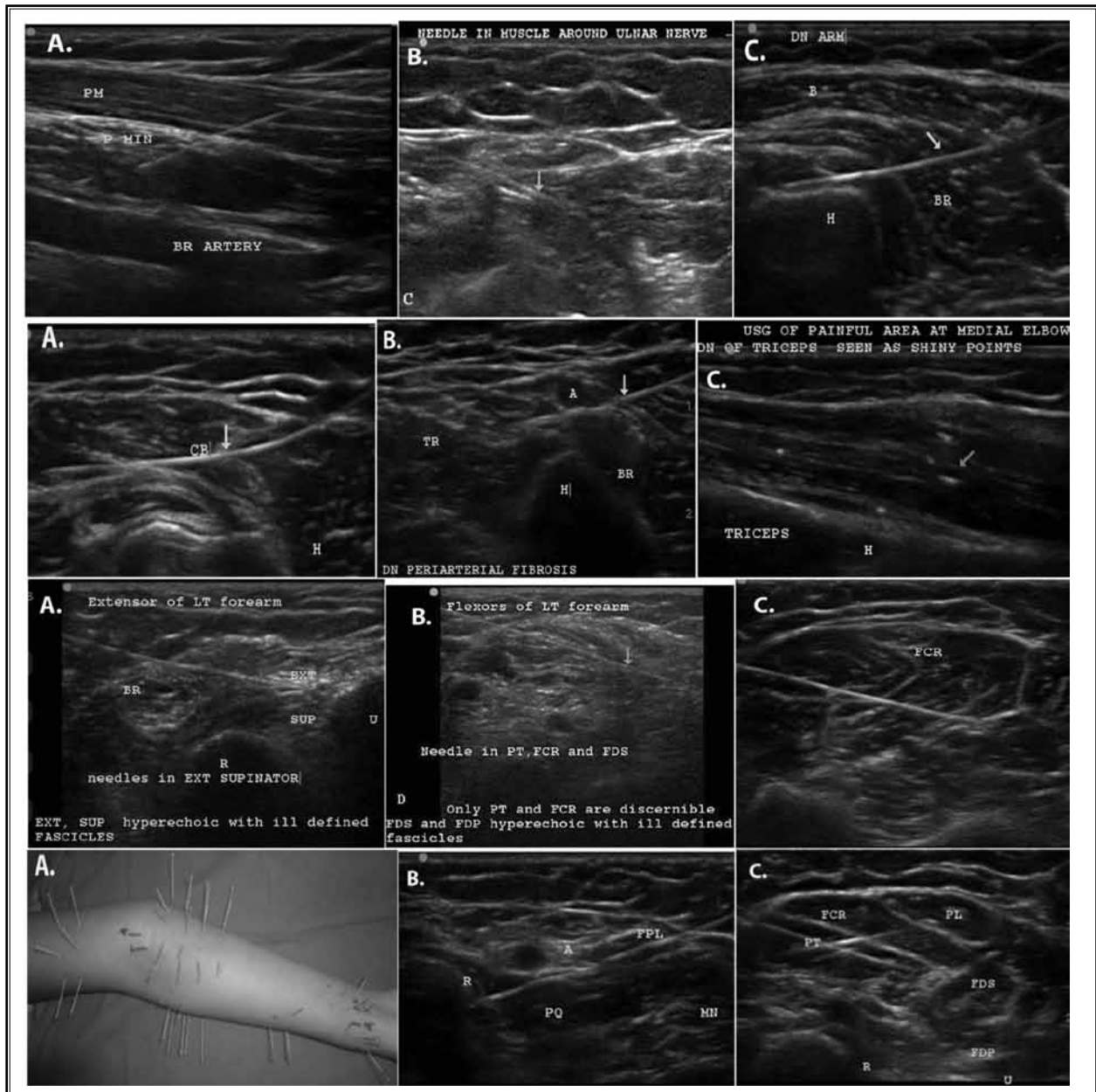


Fig. 3. USG visualization of DN targeting the flexor and extensor muscles of the affected extremity in various patients. Note the hyperechogenicity of muscles with loss of muscle architecture in some of the severely affected muscles of forearm – a distinctive diagnostic feature of CRPS on USG. The arm muscles were affected only in those with shoulder involvement. Special emphasis was given to needling the muscles involved in shoulder movements, arm and forearm flexion, pronation/supination (pronator teres [PT], pronator quadratus [PQ]/supinator [Sup]); wrist movements (flexor carpi radialis [FCR], palmaris longus [PL], flexor carpi ulnaris [FCU]); digital movements (flexor digitorum superficialis [FDS] and profundus [FDP], extensor digitorum [EXT], extensor indicis, extensor digiti minimi). USG also helped in avoiding vital structures and nerves. Row 1 A: Shows the needling of pectoralis major (PM) and minor (P.Min). Note the hyper echogenicity of P.Min in this patient with shoulder and hand involvement. B. shows the needling around the ulnar nerve just beneath the arrow. C. needle in biceps (B) and brachialis (BR). Row 2 A: Needle in coracobrachialis (CB) B. Needle just beneath the brachial artery on the medial side of lower arm C. shows the needles in triceps in cross section as bright dots pointed by arrow. Row 3 A: Needles in the extensors of the forearm. B. needles in the amorphous muscle mass of flexors in the forearm. Row 4: Shows the clinical picture of the needles introduced at 1 cm distance at the thickest part of muscles. Shows the needling of flexor pollicis longus, pronator quadratus, pronator teres, flexor carpi radialis and palmaris longus in a young woman of 24 years with CRPS for 3 years with regular physiotherapy. Abbreviations in addition to the ones given above: H: Humerus R: radius U: ulna, A: artery, MN: median nerve.

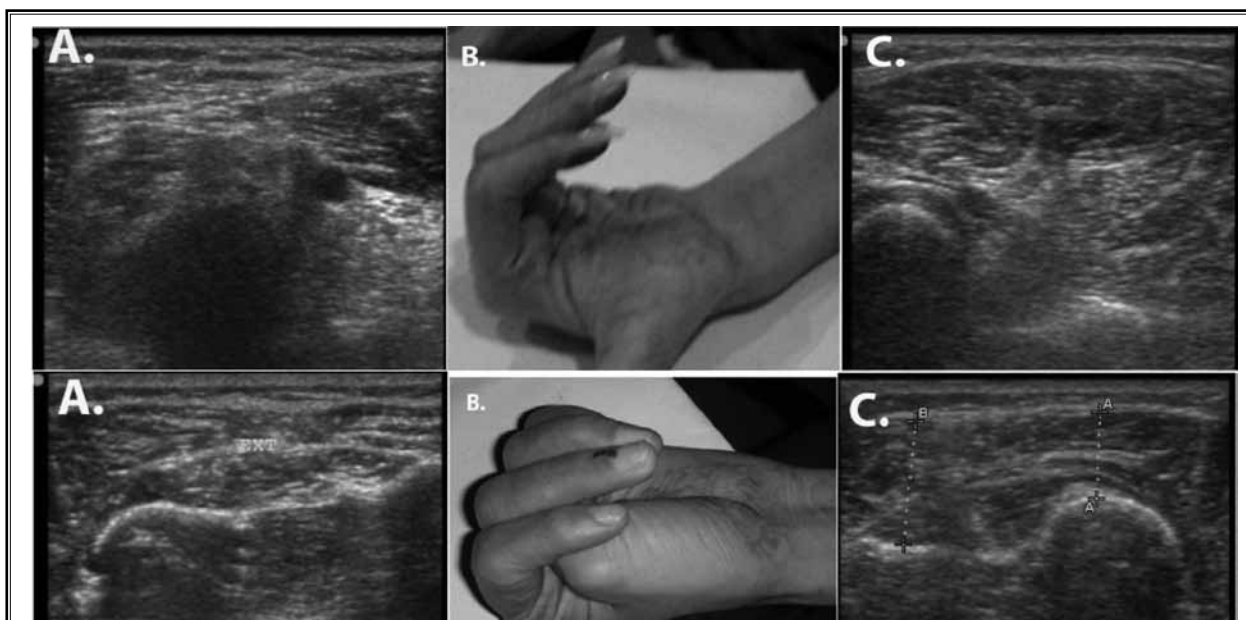


Fig. 4. The MSKUSG of the forearm of a 26-year-old woman who had a metacarpal fracture 18 months prior. She reported that she had the warm swollen hand typical of CRPS for less than a month after the fracture but thereafter developed a severe stiffness with inability to flex beyond 90° at the metacarpal and interphalangeal joints. The distal interphalangeal joints had become completely stiff within 6 to 8 months of the fracture. A. Note the extreme destruction of muscle in the flexor compartment associated with severe wasting. This is a patient who probably had extremely severe contraction with the contractures overtaking the inflammatory stage very rapidly. The CRPS would appear to have skipped passage through sequential stages. But careful history taking revealed that she had gone through the sequential stages but so rapidly that they seemed to have been skipped altogether. C. After one month of dry needling the muscle outlines are clearly discernible and the bulk has increased. There is an associated improvement in hand movements with an ability to make a fist.

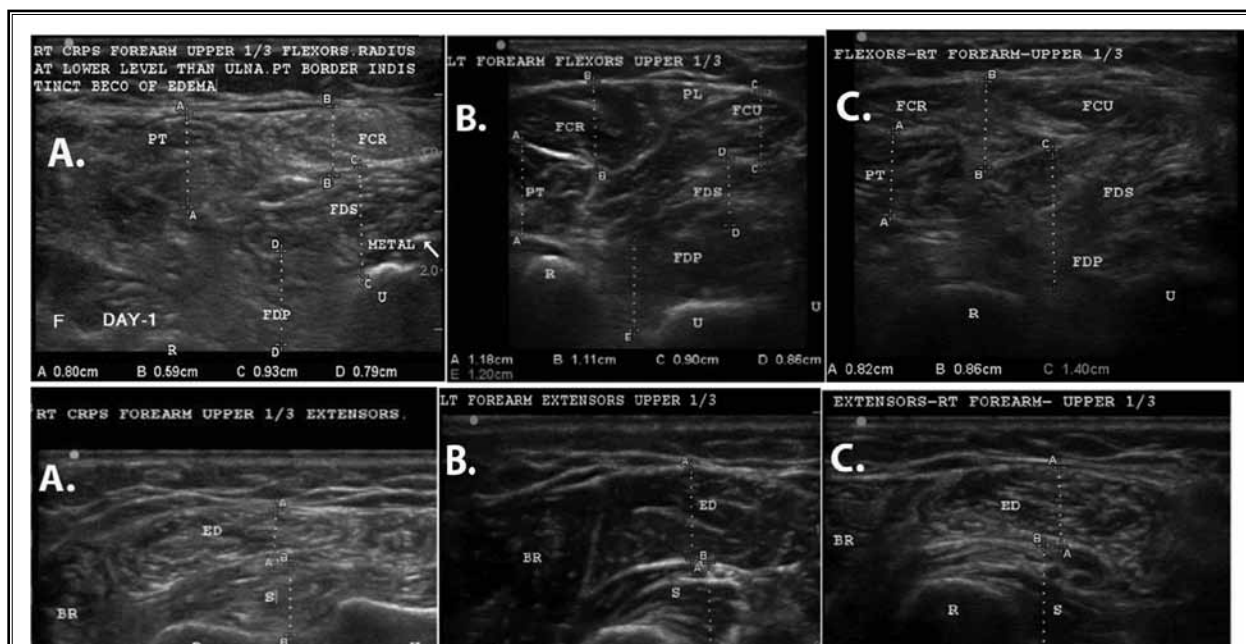


Fig. 5. Shows the extreme destruction of muscle structure in right forearm compared with the normal muscles in the left forearm and the improvement at 45 days with reappearance of boundaries though the hyperechogenicity still persists.

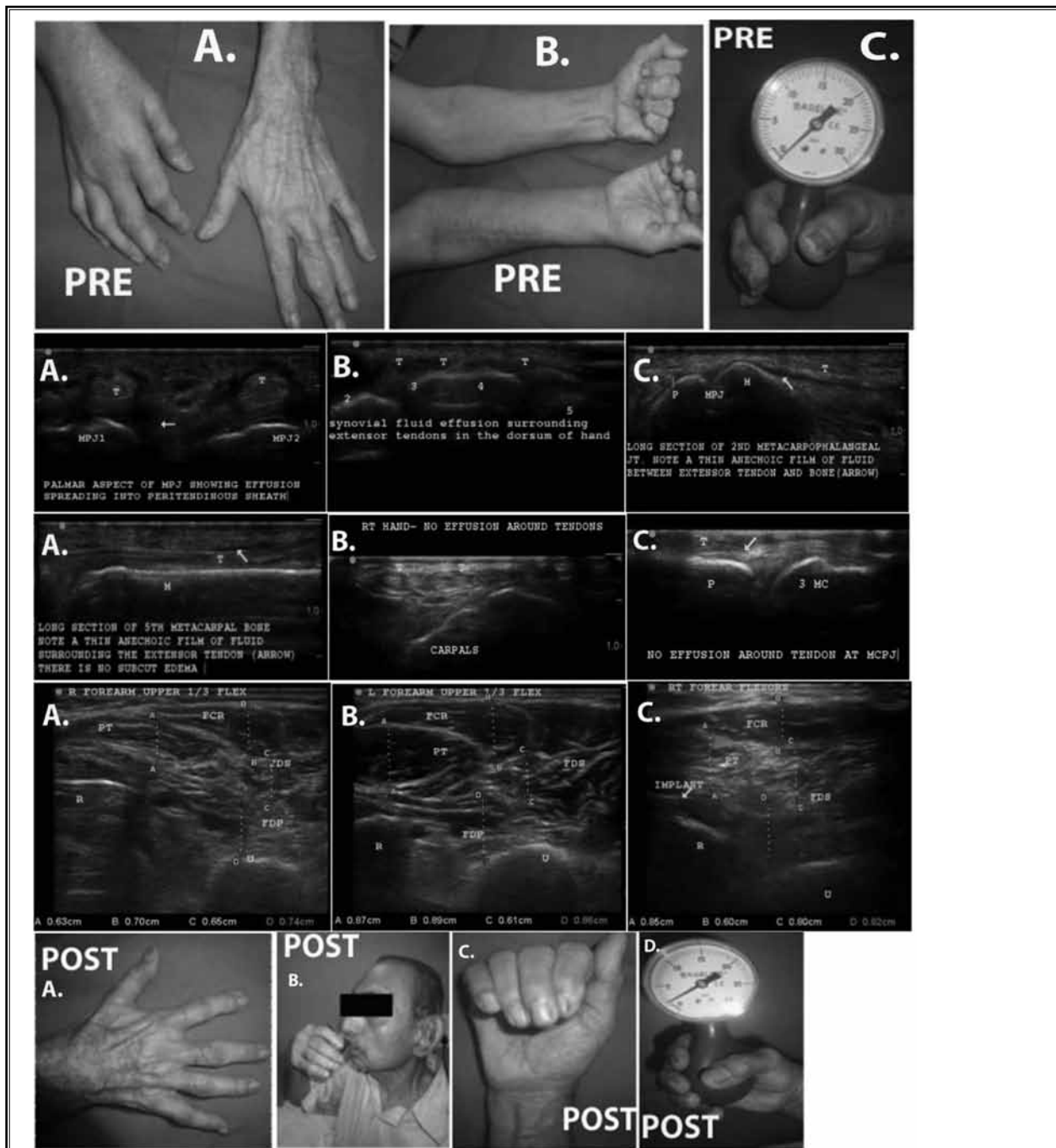
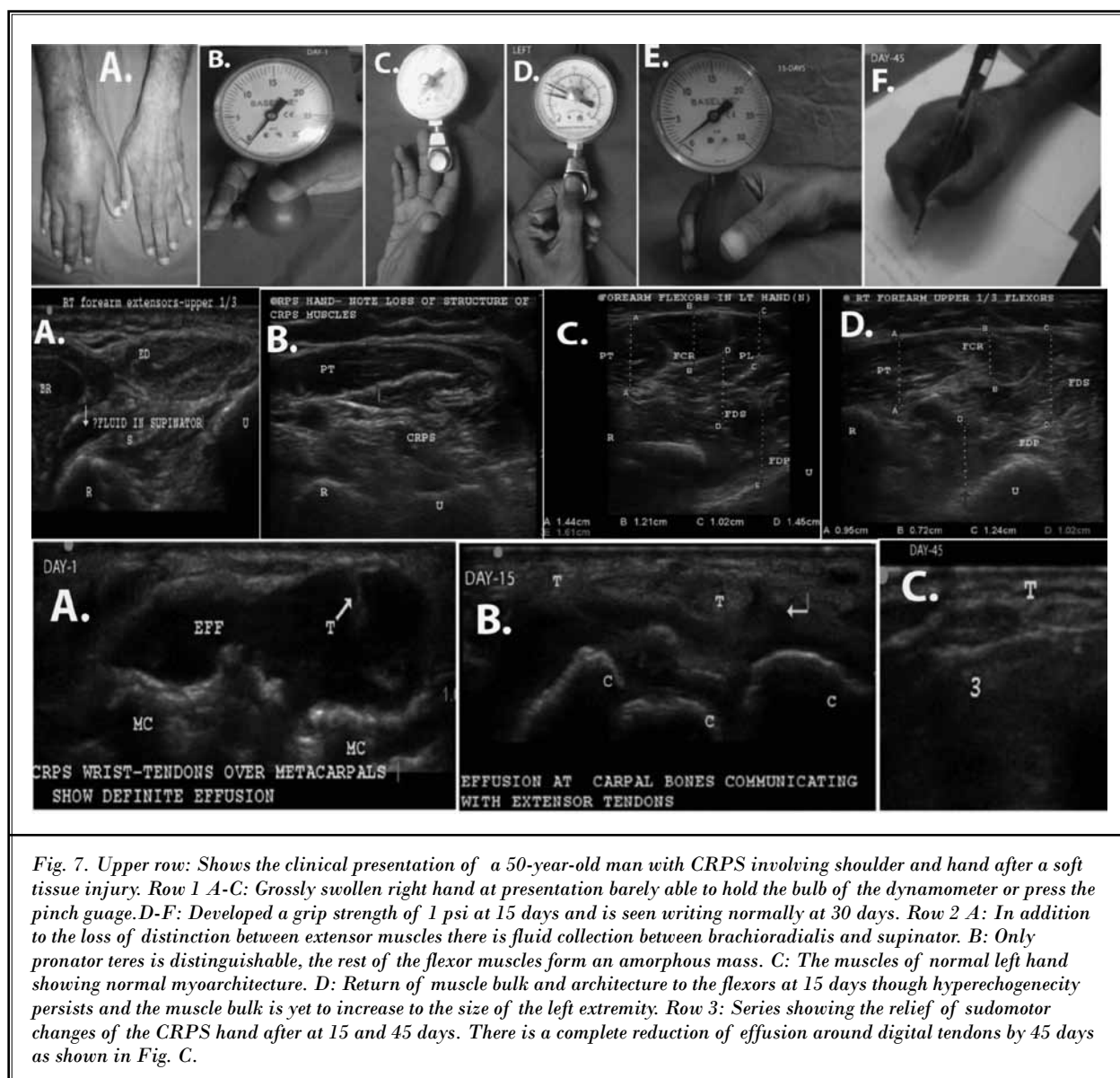


Fig. 6. Row 1 (A-C): Typical stiff, swollen hand that developed 4 months after surgical reduction of fracture radius. The swelling at the middle interphalangeal joint of the normal left hand is because of an asymptomatic lipoma present for many decades. He is unable to make a fist and the grip strength is 0 PSI. Row 2 A-C and 3A: Show the fluid collection in the synovial sheaths surrounding the flexor and extensor tendons at the wrist as well as in the fingers. There is no subcutaneous edema to account for the swollen hand which is primarily because of the synovial effusion. 3B and C: At 15 days after 7 sessions of USGDN there is a complete resolution of effusion around the extensor tendons at the carpal and metacarpophalangeal joints. Row 4 A and B: The flexors show unclear muscle outlines as well as marked hyperechogenicity compared to the normal left forearm muscles. C: Shows an increase in muscle size at 45 days. Hyperechogenicity is still present. Row 5 A-D: The clinical picture after 15 days of DN. The dynamometer shows readings of 2 PSI. He has also improved his elbow flexion enabling him to perform a daily act of living like drinking from a glass which was impossible at the time of first visit because of an apparently fixed deformity at the elbow at 85° flexion.



cm intervals along the length and at 0.5 – 1 cm intervals along the breadth of the muscle to the full depth of the muscle, as seen on USG (Fig. 3). The spacing of needles was less important than the confirmation on USG that needles were placed in all the concerned muscles. For example, if a needle meant to enter the flexor digitorum superficialis and profundus (FDS and FDP) entered the flexor carpi radialis (FCR) and FDS, we would insert an extra needle to target FDP. Sometimes the muscle destruction could be such that necessitated anatomic guesswork. If the needle was visualized on USG to be near a vessel or the median nerve, we would redirect

the needle or leave that needle and insert another instead. Thus the above description of needle spacing is a generalized description of our procedure. In the first few sessions of DN, the needle introduction provoked pain, especially in patients with allodynia and hyperalgesia. But if the needle was left in situ for a minute or 2, the pain would subside and the needle could be advanced another 1 – 2 cm. Thus it had to be an incremental introduction to make it comfortable for the patient. MSKUSG showed that there were active twitches in the muscles when the patient reported pain and it was only after these twitches subsided that we could advance

Table 2. Details of dry needling.

Muscles needled	Day 1 of DN	15 days post DN	45 days post DN
Neck: trapezius, levator scapulae, splenius, semispinalis, scalenes, longissimus and iliocostalis cervicis and capitis	Significant resistance to passage of needle for DN in all the muscles	Perceptible reduction to resistance	Resistance to DN absent
Shoulder: Supra/infraspinatus, latissimus dorsi, teres major/minor, subscapularis, pectoralis major/minor, deltoid, coracobrachialis.	Significant resistance to DN in all the muscles	No resistance to DN	Resistance to DN absent
Arm: biceps, brachialis & brachioradialis-anteriorly; triceps- posteriorly	Significant resistance to DN in all muscles. Biceps & brachialis felt bone-like during needle insertion in many patients.	Resistance to DN much reduced	Resistance to DN absent
Forearm: Flexor carpi radialis & ulnaris, flexor digitorum superficialis & profundus, pronator teres & quadratus- anteriorly; brachioradialis, extensors of the wrist & fingers, supinator & anconeus, posteriorly.	Significant bone-like resistance to needle insertion in most muscles. Brachioradialis, pronator teres & quadratus were better in a few patients. Resting twitches seen on USG in flexors and extensors in 10 patients. Twitches on DN of same muscles seen in 24 patients	Resistance to DN much reduced but needle encountered a grating sensation. No resting twitches in any patient Twitches seen on DN in 8 patients	Minimal but perceptible resistance to DN. No twitches at rest or on DN.

the needles. The muscle would be grasping these needles and it would be difficult to withdraw them even by a centimeter to redirect it around a vessel or a nerve. The needles were removed 30 – 40 minutes after all the twitches had completely subsided and the removal was smooth and painless.

The needles were solid needles of 32 gauge used commonly for acupuncture. The length could be 2.5 to 4 – 5 cm in the forearm depending on the muscle thickness as the needles would go right down to the bones. Around the shoulder we used 6 – 7.5 cm needles to go through the bulk of shoulder muscles.

RESULTS

The sonographic signature of muscle in the normal extremity was distinct as a predominantly dark hypoechoic background of muscle fibers with contrasting streaks of bright hyperechoic septae. The nerves and vessels were located within sharply defined hyperechoic fascial intermuscular compartments. The bones formed dense hyperechoic lines with dark uniform shadow. In contrast, the hallmark of MSKUSG findings in CRPS-1 was a loss of normal myoarchitecture with loss of the distinction of endo-, peri-, and epimysium to various degrees in all the involved muscles. There was a predominance of hyperechoic fibrous tissue (3-7). The wasting and hyperechoic fibrous tissue within a muscle correlated significantly with difficulty in initiating and sustaining movements by that muscle. The greatest damage was seen as a uniform hyperechoic fibrous

mass replacing the distinct individual muscles associated clinically with an extreme difficulty with any purposeful movement, dystonia, and tremors (Figs. 4, 5). This type of damage was seen in 10 patients (22.72%). However in 34 patients (77.27%) there was mainly an involvement of FDS and FDP, while other muscles like pronator, FCR, and palmaris longus discernible though the caliper measurement showed wasting (Figs. 1, 7). In patients with marked difficulty with supination, the supinator and pronator showed fibrosis (seen as hyperechoic fibrous tissue) as early as 7 days of onset of CRPS) as well as reduction in size compared to the normal limb. Ten patients showed muscle edema in various muscles like the biceps (Figs. 1, 7), FDS, and FDP (22.72%) along with unequivocal muscle atrophy. Fig. 7 shows intramuscular fluid collection in the supinator muscle. The same patient also showed marked effusion around the digital extensor tendons. The MSKUSG changes were very constant either prominently or subtly with specific changes only in muscles like FDS and FDP involved in digital flexion.

All 44 patients showed a disappearance of pain, sleep disturbances, and reduction of warmth and swelling after 2 – 3 DN sessions (a week) (Table 3). A new distinction between rest pain and movement pain was introduced because all our patients became remarkably pain free at rest and within their active movement range but experienced pain with passive guided movements by the physiotherapist to achieve better ROMs. As DN continued, active ROMs kept increasing until it was possible to achieve pain-free full ROM.

Table 3. Response to treatment at 15 and 45 days.

First visit	15 days	45 days
Rest pain: 38 patients had rest pain; 12 patients presenting with 3 months of CRPS had constant 7-9 NRS pain; 15 patients presenting between 3-6 months had intermittent 4-6 NRS pain; 11 patients presenting after 6 months had intermittent 2-3 NRS pain. 6 presented with > 9 months of CRPS with no pain at rest	Rest pain and sleep disturbance was absent after 2-3 DN sessions in all patients. No rest pain at subsequent assessments.	No rest pain
Movement pain: All had 5-10 NRS pain on movement with the pain increasing with attempts to increase the range of movement	No movement pain in 18 patients. 12 reported 4-5 NRS at extreme ROM	No movement pains even at extreme ROM
Allodynia/hyperesthesia/hyperalgesia: 10 patients had allodynia, hyperaesthesia; 26 had mechanical hyperalgesia; 8 had no sensory symptoms.	Sensory symptoms started to abate after 2nd session; No sensory symptoms reported after that.	No sensory symptoms
Sudomotor: 28 had constant swelling; 16 had intermittent swelling	No swelling	No swelling
Vasomotor: All had color asymmetry, 24 patients had constant temperature asymmetry; 10 had intermittent temperature asymmetry; 10 had none	Color asymmetry present. No temperature asymmetry	Color asymmetry reduced No temperature asymmetry
Motor symptoms: All had stiffness and weakness. 32 had tremors and 12 patients had dystonia	Stiffness, weakness reduced with obvious increase ROM and power, tremors, dystonia absent.	Stiffness, weakness negligible. Activities of daily life possible. No tremors, dystonia
Movement restrictions: Hand- all had severe movement restrictions at fingers and wrist. 34 patients could not even flex the fingers around the dynamometer bulb; shoulder- 26 patients had movement restrictions with abduction & internal rotation being the worst affected; elbow- 2 had restriction of flexion and 8 had restriction of supination. The ROM on goniometry at various joints of upper extremity, dynamometry, and pinch gauge readings were much lower than the 25th percentile compared to normal extremity.	75% improvement at IPJ but MPJ movement still at 50% of normal. 30 patients could generate between 1-3 psi grip strength on dynamometer. Pinch gauge readings were 60% of normal. Elbow & shoulder-26 patients showed 80-90% improvement of ROM. 4 patients with surgery and implants improved by 60-70%.	IPJ and MPJ improved by 80-90% ROM improvement in 24 patients, but MPJ still 70-80% in 8 patients. Grip strength on dynamometer was between 3-5psi. Pinch gauge readings 80% of normal. Elbow, shoulder ROM normal in 26 patients. 4 patients with elbow & shoulder surgery had about 10-20% residual restriction.
DASH scores: 83-87 (85 +1.5)	Range: 30-35 (32.5 +1.8)	Range: 9-12 (10.5 + 1.2)

psi: pounds per square inch.

Dystonia and tremors were replaced by purposeful movements within the first 10 – 15 days. By 15 days, all patients could flex their fingers around the dynamometer bulb to grasp it (Figs. 2, 6, 7). Within 30 days, 29 patients (65.94%) could make a tight fist. Activities of daily life (ADL) like using door handles, lifting objects, and the fine hand movements necessary to write, dress, etc. were also achieved, as indicated by improved DASH scores (Fig. 8). Twenty-six patients (59%) achieved full functionality by 30 days and 14 patients (31.81%) by 45 days. At 45 days, 43 patients acquired the grip strength to generate dynamometer reading 3 – 4 pounds per square inch (psi). This included 23 patients (57.5%) who had presented with apparently fixed flexion deformities at IPJ and MPJ. This global motor improvement coincided with a return of discernible muscle outline and increase in muscle size and islands of normal hypoechoic muscle tissue on USG (Figs. 1, 4, 7). Five patients (11%) with traumatic and/or surgical injuries involving multiple joints reported a few residual compromises

mainly because of movement impedance by the surgical implant. Patients were followed up for a year after treatment completion with quarterly phone calls by our clinic secretary who was unaware of the treatment. They were asked whether they had any pain, stiffness, or disability that hindered their personal or professional life. They were also asked if they were happy with their activities and whether they were performing all activities as they were doing prior to CRPS onset. Thirty nine patients (88.6%) maintained their improvement for one year after successful completion of treatment, 3 patients (6.8%) were lost to follow-up after 6 months, and 2 others (4.5%) after 3 months.

Complications of DN

Pain with needle advancement necessitated incremental advancement in certain muscles in all 44 patients. Dramatic reduction of allodynia, rest pain, and stiffness after the first session of DN ensured their cooperation for further DN. Twelve patients with allodynia

ia reported bearable pain on skin penetration which disappeared after 3 – 4 sessions of DN. Ecchymoses under the skin after needle removal were observed fairly commonly in all patients, but would fade uneventfully within 7 – 10 days.

Discussion

Motor impairment has been reported as a constant feature of CRPS-1 (9-20). We propose a correlation between the objective information of muscle structure and digital synovial sheaths effusion from MSKUSG findings (Figs. 1, 6, 7), with the movement difficulty, weakness, and stiffness of CRPS as documented by dynamometry, goniometry, and disability scores such as DASH.

It follows that resolution of MSKUSG findings would be associated with a similar clinical improvement of motor findings. The MSKUSG at 15 days showed a reduction of edema in the muscle and synovial sheath (Figs. 1, 6, 7). This was associated clinically with a striking pain relief, improvement of CDC, improved ROMs, and sleep. The MSKUSG at 30 days showed a definite reappearance of hypoechoic muscle fibers, increased muscle bulk, and absence of muscle and peritendinous edema (Figs. 1, 4-7). Clinically there was an absence of CDC, improved functionality with resumption of activi-

ties of daily life, and improved outcome parameters like goniometry, dynamometry, and DASH scores.

The parallel improvement of clinical and MSKUSG findings have led us to surmise that pain, warmth, and swelling in CRPS were actually a local inflammatory phenomena in the hand from a mechanical tenosynovitis developing as a consequence of movement difficulties. Actually the term tenosynovitis denotes an infection but there is no infection here as the inflammatory phenomena result from a mechanical issue. A better term is “tendinosis” as has been suggested in DQST (21).

To link the inflammatory phenomena with myofascial destruction documented on MSKUSG, we surmised that the actual myofascial pathology leading to CRPS-1 was a co-contraction of digital and wrist flexors and extensors. The constant co-contraction causes the movement difficulties like stiffness, weakness, tremors, and dystonia of CRPS.

Co-contraction is defined as “the simultaneous contraction of agonist and antagonist muscles across a joint to hold a position” (22). Muscles are classified as agonist, antagonist, fixator, or synergist. At the initiation of any normal movement, both agonists and antagonists come into action. The agonist continues to contract throughout the movement, while the an-

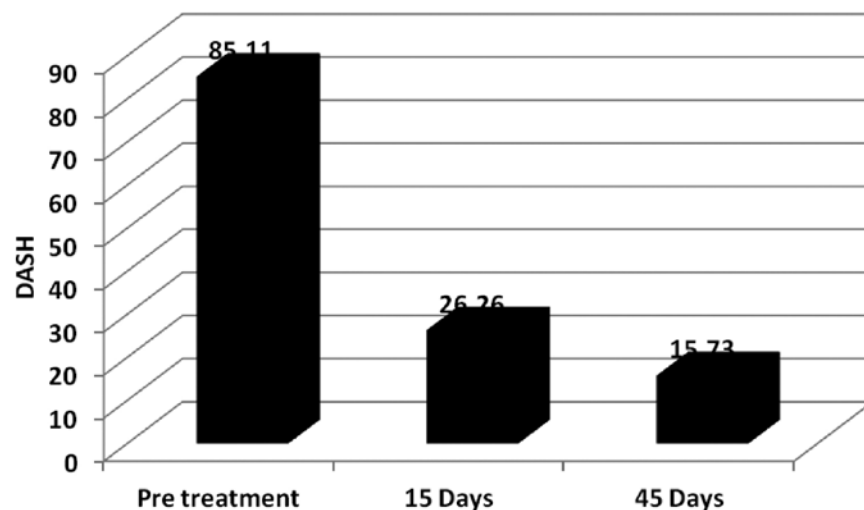


Fig. 8. DASH values before and after treatment with DN. Disability of arm shoulder and hand (DASH) scale is a composite scale that assesses the functionality of the whole upper extremity. The complex functions performed by the extremity require coordination between various parts of the limb and invariably involves proper functioning at various joints of the limb. The very high pretreatment values prior to DN indicate the severe disability prevalent amongst CRPS patients. At 15 days of DN there was a more than 50% improvement in DASH values and by 45 days the values showed a 75% improvement. The residual disability was reflective of permanent fixed deformities because of implants remaining in situ rather than a persistence of the CRPS pathology.

tagonist remains quiescent during the movement until the deceleration phase. This transient activity at the beginning and end of movement and constant passive resistance during the movement by the antagonist is essential for guiding the movement and making it smooth, especially for fine digital movements (23,24). When agonists and antagonists contract together actively throughout movement, they behave as fixators and stabilizers. The co-contraction in CRPS-1 appears to have this fixator-like action at all the IPJs, MPJs, and wrist which precludes any functional activity. The classical resting posture of the CRPS hand reflects this with abnormal wrist flexion and extension of all fingers. We have observed that the tremors and dystonic movements start when patients try to overcome this fixator action at these joints. Electromyographic (EMG) abnormality of antagonist co-activation has also been previously reported in CRPS (25).

The Budapest criteria stipulates that CRPS patients should have one symptom each from the 4 categories of sensory, motor/trophic, vasomotor (color/temperature), and sudomotor/edema, and at least 2 signs from the same 4 categories. Co-contraction and its sequelae explain the varied clinical presentations encompassed by the diagnostic criteria of CRPS. It accounts for the hot red hand of early CRPS to the cold limbs of late CRPS with several other variants in between, as follows.

When the patients start developing co-contraction they are still able to move their fingers at the DIPJ, PIPJ, and MPJs, but with considerable difficulty. This is because of the extreme effort needed by the constantly stiff agonists to overcome the resistance offered by equally stiff antagonists. This causes strain and friction between the tendons and the synovial sheaths as well as within the snug osteo-fibrous tunnels of the fingers (24). After movement, the friction at the digital synovial sheaths leads to synovial effusion characterized by very marked pain, redness, warmth, and swelling. This situation is akin to DQST. However, DQST is restricted to only the thumb while the global tendinoses of CRPS manifests as inflammation of all the flexor and extensor tendons. We have proposed in previous papers that the loss of contractile muscle tissue from within the connective tissue framework deprives the muscle of elasticity in CRPS-1, whereas the non-contractile supportive tough septae that remains leads to stiffness and motor impairment (3,4). MSKUSG has demonstrated repeatedly that hypoechoic muscle fibers disappear with a relative increase in hyperechoic connective tissue framework as early as one week of onset of CRPS

with mobilization after plaster cast removal. MSKUSG also shows that as CRPS progresses there are hardly any hypoechoic fibers left.

Severe constant pain from tendinoses leads to sequelae such as central sensitization and recruitment of the sympathetic system resulting in the sympathetic maintenance of pain (26,27) Thus in the early CRPS, the movements are limited both by the severe pain from the tendinoses and the stiffness of co-contraction. This cycle of movement – mechanical inflammatory tendinoses – movement avoidance continues until the patients learn to avoid movements altogether.

With complete movement avoidance, the tendinoses subside with the limb having a normal temperature or even becoming cold due to lack of muscular activity. Simultaneously, the oxidative stress from increased demand for oxygen and nutrients in the constantly co-contracted muscles leads to exhaustion of the available oxygen and nutrient supply, ischemia, and fibrosis. The oxidative load in CRPS is apparently so high that ischemia appears to set in very early and runs such a rapid course that ischemia and fibrosis appear to happen almost simultaneously. In some patients who delayed their treatment even by a few weeks after first consultation, we have observed that MSKUSG shows a very obvious escalation of hyperechogenicity in the forearm muscles implying an actual fibrosis of muscle fibers.

From the perspective of initial co-contraction and later ischemic fibrosis, Bonica's descriptions of hypertrophic, dystrophic, and atrophic stages appear very relevant though Bruehl et al have shown with cluster analysis that changes in CRPS argued against sequential staging of CRPS (28,29) as there was no association with CRPS duration. The 3 distinct clusters that emerged suggested 3 subtypes of CRPS instead. One was a relatively limited subtype with predominantly vasomotor symptoms. The second was also relatively limited subtype with predominantly neuropathic and pain symptoms. The third was a florid CRPS syndrome similar to classic reflex sympathetic dystrophy (RSD) descriptions. Co-contraction explains both the sequential staging of Bonica and the subtyping of Bruehl et al (28,29). In some patients with severe co-contraction and inflammatory tendinoses, the sequential stages telescope into one another and reach the contracture stage within a few months (Fig. 4). This will be very different from the majority of CRPS patients where the co-contraction and inflammatory tendinoses are less severe and CRPS follows more sequential progress over years. The complex interplay between co-contraction, tendinoses, and

the consequent events of sympathetic recruitment and spinal sensitization determines which symptoms will be predominant in the clinical presentation.

In the stages described above, there could be any number of permutations and combinations of clinical manifestations. The determinants of these manifestations could be the intensity of co-contraction, the gentleness of physiotherapist in coaxing just enough increase of ROM while avoiding a triggering of further tendinoses, the quality of analgesia, anti-inflammatory and neuromodulatory medications, and finally the forbearance of the patient to persevere with PT in spite of the pain. Intervention with DN of course, has the ability to reverse tendinoses, co-contraction, and even fibrosis.

The quality of analgesia differs between oral medications, sympathetic blocks (SGB), and a somatic block like continuous brachial plexus block (CBPB). At co-contraction stage (Bonica's hypertrophic stage), we have found that SGB could help in relieving pain and swelling but has the limitation that its effects are temporary. We later understood that for SGB to be effective, the co-contraction had to be mild enough to make PT possible without pushing them over the edge of repeated inflammatory tendinoses every time they had PT. However in most patients who received SGB, the stiffness did not improve in spite of an increase in the temperature of the already warm CRPS hand after SGB. We believe SGB only reduces the sympathetic response to the severe pain from tendinoses and that its vasodilatory effect has little benefit in CRPS (6,7).

CBPB would be a more logical treatment because it provides an ongoing analgesia that helps with PT. We have found that the persistent stiffness in spite of CBPB made PT difficult as it had to avoid recurrence of swelling, warmth, and pain in the hand unless DN was added to CBPB (5-7). Without DN to address the co-contraction, CBPB had to last over several weeks (4 – 6 weeks) with all the attendant problems of an indwelling brachial plexus catheter (our unpublished data).

All these problems with PT disappeared once we introduced DN into our treatment regime with the assumption that there had to be a myofascial problem for the motor impairment of CRPS. In the co-contraction phase, USGDN could reverse the inflammation from tendinoses within a few days (2 – 3 DN sessions). This action of DN was independent of the quality of PT because any exacerbation of tendinoses by PT could be reversed by the next DN session to reinstate the patient onto the path of recovery. In fact the patients could achieve significant improvement with each session of

PT without any yo-yo effects. Thus DN could reverse not only the CDC but also the disability of CRPS very quickly, within 3 – 4 weeks in early CRPS.

We later derived the mechanism of co-contraction in the CRPS pathogenesis by studying the effects of DN repeatedly in various patients in different phases of CRPS. The observation that DN of the digital extensors markedly improved finger flexion, while DN of flexors improved extension within few minutes of needle removal provided an indication that co-contraction as the myofascial pathology could be responsible for stiffness and weakness of CRPS. Similar cause and effect observations on MSKUSG of routine reduction of peri-tendinous effusion and skin temperature at 10 days after 4 – 5 DN sessions provided objective confirmation that the sudomotor and vasomotor changes also were consequent to co-contraction induced synovial inflammation. Specific movement restrictions could be correlated with the fibrosis seen ultrasonographically in concerned muscles. For example, fibrosis in the pronator teres, pronator quadratus, and the supinator could be correlated with fixed pronation deformity. Specific USGDN of these muscles produced a progressive reduction of the pronation deformity with a concomitant reappearance of normal muscle architecture and a documented increase in size. Similarly, if the index finger flexion was difficult, USGDN targeted extensor indicis, extensor digitorum (antagonists), the FDS, FDP (agonists), and the interossei and lumbricals of the index finger (synergists). This ability to isolate the problem to address it made USGDN a systematic approach with predictable results. We have recently published the use of USGDN in reversing a much more benign version of co-contraction in a patient with writer's cramp (30).

The stages of ischemic contracture and ankylosis of CRPS (dystrophic and atrophic phases of Bonica) are phases where it is no longer the pain that limits movements but an actual muscle contracture from fibrosis or ankylosed joints of claw hand which makes movements impossible. Fatty degeneration, fiber atrophy, and nuclear clumping in the histopathology of muscles of the amputated CRPS-affected extremity have been previously reported (31,32). The inability to move probably reduces sympathetic recruitment as there is no pain or inflammation to provoke a sympathetic response. Hence a sympathetic block at this stage is logically unlikely to help because there is hardly any blockable sympathetic involvement in the CRPS pathology. Analgesia from CBPB may help the patient to do better PT but with a return of tendinoses (3). SGB/CBPB alone

could help only if performed before the co-contraction progresses to ischemic fibrosis. However DN as a sole treatment modality produces a significant reduction in recurring tendinoses probably by relaxing the few co-contracted muscle fibers left viable by the ischemic process. Our USG observations of hypoechoic muscle fibers making a reappearance in the previously hyper-echoic fibrotic mass that occupies the forearm confirms the surmise that DN also brings in muscle regeneration from these few viable fibers (Figs. 1, 4, 7). Clinically, the regenerated new muscle fibers make movements easier, improves the ROMs and later, strength of the muscle seen in the dynamometer readings and improved DASH scores.

Thus, co-contraction provides a different explanation for the 2 major mechanisms in the current understanding of CRPS pathophysiology, namely inflammation and ischemia (33). However this inflammation is mainly at the tendons (all 44 patients) and ischemia in muscles. Muscle edema seen in a few patients (10 patients in this series, 22.72%) is probably reactionary edema from micro tears. The anti-inflammatory action of steroids would reduce this reactionary edema from micro tears but would be ineffective against the severe co-contraction that produced the micro tears in the first place. This might be the reason why intramuscular steroids have never been demonstrated to be a viable option for producing any lasting effect in CRPS (34,35). However we have never tried injecting the muscles as we have found that DN does the job of reducing muscle edema within 2 – 3 sittings (Fig. 1). We have found that injecting steroids into the synovial sheaths and into the IPJs, MPJs, and the wrist joints in some patients helped in reducing the inflammation, pain, and swelling in the hand (not in the 44 patients in this series). The ROM also improved marginally. But the stiffness from co-contraction was still present 2 weeks after the injection and was re-inducing the tendinoses gradually. Again USGDN of forearm muscles could reverse the tendinoses within a week (2 – 3 sessions) and the disability in the next 3 – 4 weeks.

The routine return of discernible muscle architecture and bulk on MSKUSG in parallel with clinical improvement in all the CDC after 30 days of DN as the sole therapeutic modality provided objective corroboration of our surmise that motor impairment of co-contraction was indeed the primary pathology amenable to reversal by DN.

This kind of routine predictable cause and effect relationship has not been reported previously with any

of the other CRPS treatments where a persistence of CDC years after the initial onset has been reported to be the norm (36) along with the associated disability. USG shows the reversal of fibrosis within 1 – 2 months. However only histopathological studies before and after DN would provide the final confirmation.

Sandroni et al (37) showed 11% permanent disability based on retrospective chart reviews, but prospective outcome studies in CRPS (36,38,39) demonstrated that 64% of patients still fulfill IASP criteria at 5.8 years, with 31% being permanently incapable of work and 28% having to make working adjustments. A web-based epidemiological survey reported a 62% disability rate, a 96% sleep disturbance rate, 86% restricted mobility, and self-care issues in 57% of patients after failure of multiple pharmacological and non-pharmacological interventions (39). A complete reversal of CRPS and its associated disability is unusual, as is the return to prior functionality. The uniform reversal of CRPS and its disability by DN in all our patients, including those patients with a sympathetically independent CRPS (not included in this 44 patients to avoid confusion of efficacy between SGB and DN), highlights the primary role of the myofascial system in the pathogenesis of CRPS-1.

We are not certain what initiates the co-contraction in CRPS. It could be that pain afferents from a fracture or injury alter the motor processing in the central nervous system, replacing the normal agonist/antagonist coordination with co-contraction of both groups to naturally "splint" the fractured/injured limb (19,20). Since DN which has been described as a specific treatment for myofascial trigger points (MTrPs) appears to address not only the motor impairment, disability, and reverse the MSKUSG findings, but also the CDC, it is logical to assume that MTrPs in both agonists and antagonists might be involved in the mediation of co-contraction. The pathophysiology of MTrPs (40-50) and the role of a compromised local blood supply, hypoxia, and acidosis at the MTrPs (42-45,47,48) in causing muscle pain and dysfunction in many chronic pain conditions is being increasingly accepted (51,52). The efficacy of DN in alleviating pain and MTrPs has also been extensively demonstrated by various authors (53-59).

PT, the historical therapeutic mainstay in CRPS, has always been limited by allodynia and the mechanical hyperalgesia characteristic of CRPS. Lack of uniformity amongst PT regimes (60) forms yet another limitation. The predictability of DN in providing repetitive relieves from symptoms of recurrent inflammation led to a more effective PT in our patients, with a steady and

incremental motor improvement resulting in disability reversal.

CONCLUSION

We present a new perspective that agonist/antagonist muscle co-contractions causes the early inflammatory and later ischemic manifestations of CRPS. DN complemented by PT reversed all manifestations of CRPS by reversing the motor impairment and the disability.

USGDN of specific muscles not only provided objective documentation of muscle structure abnormality and its later reversal but also provided objective evidence that reversal of motor pathology with DN could reverse CRPS. However, in patients with severe pain, hyperaesthesia, and allodynia it would be kinder to administer a SGB or better still a CBPB to reduce/abolish the pain of DN.

REFERENCES

1. Harden RN, Bruehl S, Stanton-Hicks M, Wilson PR. Proposed new diagnostic criteria for complex regional pain syndrome. *Pain Med* 2007; 8:326-331.
2. Merskey H, Bogduk N. *Classification of Chronic Pain: IASP Task Force on Taxonomy*. 2nd edition. IASP Press, Seattle, 1994.
3. Vas L, Pai R. An observational study of the efficacy of musculoskeletal ultrasonography in distinguishing muscle changes in complex regional pain syndrome-type 1 from those of neuropathic pains from. Accepted for publication in *Pain Practice*. {Is this ok to include?}
4. Vas L, Pai R, Radhakrishnan M. Ultrasound appearance of forearm muscles in eighteen patients with complex regional pain syndrome type-1 of the upper extremity. *Pain Practice* 2013; 13:76-88.
5. Vas L, Pai R. Complex regional pain syndrome- type 1 presenting as deQuervain's stenosing tenosynovitis. In press, *Pain Physician*. {Is this ok to include?}
6. Vas L, Pai R. Successful reversal of complex regional pain syndrome type 1 of both upper extremities in five patients. *Pain Medicine* 2012; 13:1253-1256.
7. Vas L, Pai R. Reversal of complex regional pain syndrome-type 2, and the subsequent management of complex regional pain syndrome-type 1 occurring after corrective surgery for residual ulnar claw. *Pain Medicine* 2014; 15:1059-1063.
8. Hudak PL, Amadio PC, Bombardier C. Development of an upper extremity outcome measure: the DASH (disabilities of the arm, shoulder and hand) [corrected]. The Upper Extremity Collaborative Group (UECG). *Am J Ind Med* 1996; 29:602-608. Erratum in: *Am J Ind Med* 1996; 30: 372.
9. Veldman PHJM, Reynen HM, Arntz IE, Goris RJA. Signs and symptoms of reflex sympathetic dystrophy: Prospective study of 829 patients. *Lancet* 1993; 342:1012-1016. {Need volume}
10. Maihöfner C, Baron R, De Col R, Binder A, Birklein F, Deuschl G, Handwerker HO, Schattschneider J. The motor system shows adaptive changes in complex regional pain syndrome. *Brain* 2007; 130:2671-2687.
11. Schwartzman RJ, Kerrigan J. The movement disorder of reflex sympathetic dystrophy. *Neurology* 1990; 40:57-61.
12. Livingston WK. *Pain Mechanisms*. McMillan, New York, 1943.
13. Rashid S, Galer BS. Motor dysfunction in complex regional pain syndrome. *Clin J Pain* 1999; 15:151-153.
14. Agrawal SK, Rittley CD, Harrower NA, Goddard JM, Mordekar SR. Movement disorders associated with complex regional pain syndrome in children. *Develop Med Child Neurol* 2009; 51:557-562.
15. Oaklander AL. Progression of dystonia in complex regional pain syndrome. *Neurology* 2004; 27:751.
16. Munts AG, van Rootselaar AF, van der Meer JN, Koelman JHTM, van Hilten JJ, Tijssen MAJ. Clinical and neurophysiological characterization of myoclonus in complex regional pain syndrome. *Movement Disorders* 2008; 23:581-587.
17. Navani A, Rusy LM, Jacobson RD, Weisman SJ. Treatment of tremors in complex regional pain syndrome. *J Pain Symptom Manage* 2003; 25:386-390.
18. Schilder JCM, Schouten AC, Perez RSGM, Huygen FJPM, Dahan A, Noldus LPJJ, van Hilten JJ, Marinus J. Motor control in complex regional pain syndrome: A kinematic analysis. *Pain* 2012; 153:805-812.
19. Galer BS, Schwartz L, Allen RJ. Causalgia and other reflex sympathetic dystrophies. In: Bonica JJ (ed). *Management of Pain*. 3rd ed. Lippincott, Williams & Wilkin, Philadelphia, 2001, pp 388-411.
20. Evans J. Reflex sympathetic dystrophy. *Surg Clin N Am* 1946; 26:780-790.
21. Lee H-J, Kim, P-T, Iman WA, Han-Pyo H, Jong-Pil Y, In-Ho J. Surgical release of the first extensor compartment for de Quervain's tenosynovitis clinics in orthopedic surgery. 2014; 6:405-409. {Need journal}
22. *Mosby's Medical Dictionary*. 8th edition. Elsevier, St Louis, 2009.
23. Adams MA, Black SM, Dolan P, Partridge {first initial?}. Functional anatomy of the musculoskeletal system. In: Standing S (ed). *Gray's Anatomy*. 40th edition. Churchill Livingstone, Philadelphia, 2008, pp 114-115.
24. Agur AMR, Dalley AF (eds). *Grant's Atlas of Anatomy*. 11th edition. Lippincott Williams & Wilkins, Philadelphia, 2009, pp 541.
25. Jankovic J, VanDer Linder C. Dystonia and tremor induced by peripheral trauma: predisposing factors. *J Neurol Neurosurg Psychiatry* 1998; 51:1512-1519.
26. Campbell JN, Meyer RA, Raja SN. Painful sequelae of nerve injury. In: Dubner R, et al. {List all editors} (eds). Proceedings of the 5th World Congress of Pain. Elsevier, St Louis, 1988, pp 135-143.
27. Roberts WJ. A hypothesis on the physiological basis of causalgia and related pains. *Pain* 1986; 24:297-311.
28. Bonica JJ. Causalgia and other reflex sympathetic dystrophies. In: Bonica JJ (ed). *Management of Pain*. 2nd ed. Lea & Febiger, Philadelphia, 1990, pp 243.
29. Bruehl S, Harden RN, Galer BS, Saltz S, Backonja M, Stanton-Hicks M. Complex regional pain syndrome: Are there dis-

- tinct subtypes and sequential stages of this syndrome? *Pain* 2002; 95:119-124.
30. Vas L, Pai R, Khandagale N, Pattnaik M. Myofascial trigger points as a cause of co-contraction in writer's cramps. In press, *Pain Medicine*. {Is this ok to include?}
 31. Hulsman NM, Geertzen JH, Dijkstra PU, van den {der?} Dungen JJ, den {der?} Dunnen WF. Myopathy in CRPS-I: Disuse or neurogenic? *Eur J Pain* 2009; 13:731-736.
 32. Van der Laan L, ter Laak HJ, Gabreels-Festen A, Gabreels F, Goris RJ. Complex regional pain syndrome type I (RSD): Pathology of skeletal muscle and peripheral nerve. *Neurology* 1998; 51:20-25.
 33. deMos M, Sturkenboom MCJM, Huygen FJPM. Current understanding on the complex regional pain syndrome. *Pain Practice* 2009; 9:86-99.
 34. Zyluk A, Puchalski P. Treatment of early complex regional pain syndrome type 1 by a combination of mannitol and dexamethasone. *Journal of Hand Surgery (European Volume)* 2008; 33:130-136.
 35. Perez RS, Zollinger PE, Dijkstra PU, Thomassen-Hilgersom IL, Zuurmond WW, Rosenbrand KCJ, Geertzen JH and the CRPS I task force. Evidence based guidelines for complex regional pain syndrome type 1. *BMC Neurology* 2010; 10:20.
 36. deMos M, Huygen FJPM, van der Hoven-Borgman M, Dieleman JP, Stricker BHC, Sturkenboom MCJM. Outcome of the complex regional pain syndrome. *Clin J Pain* 2009; 25:590-597.
 37. Sandroni P, Benrud-Larson LM, McClelland RL, Low PA. Complex regional pain syndrome type I: Incidence and prevalence in Olmsted County, a population-based study. *Pain* 2003; 103:199-207.
 38. Zyluk A. The natural history of post-traumatic reflex sympathetic dystrophy. *J Hand Surg [Br]* 1998; 23:20-23.
 39. Sharma A, Agarwal S, Broatch JA, Raja SN. Web-based cross-sectional epidemiological survey of complex regional pain syndrome. *Regional Anesthesia and Pain Medicine* 2009; 34:110-115.
 40. Dommerholt J, Shah J. Myofascial pain syndromes In: Ballantyne JC, Fishman SM (eds). *Bonica's Management of Pain*. 4th ed. Lippincott, Williams & Wilkins, Philadelphia, 2010, pp 450-470.
 41. Hubbard DR, Berkoff GM. Myofascial trigger points show spontaneous needle EMG activity. *Spine* 1993; 18:1803-1807.
 42. Simmons DG. Do endplate noise and spikes arise from normal motor end plates? *Am J Phys Med Rehabil* 2001; 80:134-140.
 43. Simons DG. New views of myofascial trigger points: Etiology and diagnosis. *Arch Phys Med Rehabil* 2008; 89:157-159.
 44. Maekawa K, Clark GT, Kuboki T. Intramuscular hypoperfusion, adrenergic receptors, and chronic muscle pain. *J Pain* 2002; 3:251-260.
 45. Bruckle W, Suckfull M, Fleckenstein W, Weiss C, Muller W. Gewebe-pO₂-Messung in derverspannten Ruckenmuskulatur (m. erectorspinae). *J Rheumatol* 1990; 49:208-216.
 46. Sikdar S, Shah JP, Gebreab T, Yen R-H, Gilliams E, Danoff J, Gerber LH. Novel applications of ultrasound technology to visualize and characterize myofascial trigger points and surrounding soft tissue. *Arch Phys Med Rehabil* 2009; 90:1829-1838.
 47. Shah JP, Danoff JV, Desai MJ, Parikh S, Nakamura LY, Phillips TM, Gerber LH. Biochemicals associated with pain and inflammation are elevated in sites near to and remote from active myofascial trigger points. *Arch Phys Med Rehabil* 2008; 89:16-23.
 48. Shah JP, Phillips T, Danoff JV, Gerber L. Novel microanalytical technique distinguishes three clinically distinct groups: 1) subjects without pain and without myofascial trigger points; 2) subjects without pain and with myofascial trigger point; 3) subjects with pain and myofascial trigger point. *Am J Phys Med Rehabil* 2004; 83:231.
 49. Chen Q, Bensamoun S, Basford JR, Thompson JM, An KN. Identification and quantification of myofascial taut bands with magnetic resonance elastography. *Arch Phys Med Rehabil* 2007; 88:1658-1661.
 50. Fisher AA, Chang CH. Objective documentation of myofascial trigger points by thermography. *Pain* 1984; 1:5137.
 51. Mense S, Gerwin RD (eds.). *Muscle Pain: Diagnosis and Treatment*. Springer-Verlag, Berlin-Heidelberg, 2010.
 52. Simons DG, Travell JG, Simons LS. *Travell & Simons' Myofascial Pain and Dysfunction: The Trigger Point Manual*. Vol 1, 2nd ed. Williams & Wilkins, Baltimore, 1999.
 53. Lewit K. The needle effect in the relief of myofascial pain. *Pain* 1979; 6:83-90.
 54. Gunn CC. Neuropathic myofascial pain syndromes. In: Bonica JJ (ed). *Management of Pain*. 3rd ed. Lippincott, Williams & Wilkins, Philadelphia, 200, pp 522-529. {Need year}
 55. Chen JT, Chung KC, Hou CR, Kuan CR, Chen CR, Hong CZ. Inhibitory effect of dry needling on spontaneous electrical activity recorded from myofascial trigger points of rabbit skeletal muscle. *Am J Phys Med Rehabil* 2001; 80:729-735.
 56. Kalichman L, Vulfsons S. Dry needling in the management of musculoskeletal pain. *JABFM* 2010; 23: {Need pages}
 57. Cummings TM, White AR. Needling therapies in the management of myofascial trigger point pain: A systematic review. *Arch Phys Med Rehabil* 2001; 82:986-992.
 58. Tough EA, White AR, Cummings TM, Richards SH, Campbell JL. Acupuncture and dry needling in the management of myofascial trigger point pain: A systematic review and meta-analysis of randomized controlled trials. *Eur J Pain* 2009; 13:3-10.
 59. Baldry PE. *Acupuncture, Trigger Points and Musculoskeletal Pain*. Churchill Livingstone, Edinburgh, UK, 2005.
 60. Daly AE, Bialocerkowski AE. Does evidence support physiotherapy management of adult complex regional pain syndrome type one? A systematic review. *Euro Jour Pain* 2009; 13:339-353.

