

Case Report

Ultrasound-Guided Pulsed Radiofrequency Application via the Pterygopalatine Fossa: A Practical Approach to Treat Refractory Trigeminal Neuralgia

Antoun Nader, MD, Bernard R. Bendok, MD, Jeremy J. Prine, MD, and Mark C. Kendall, MD

From: ¹Departments of Anesthesiology and ²Neurosurgery, Northwestern University, Feinberg School of Medicine, Chicago, IL

Dr. Nader is Professor in Anesthesiology and Orthopaedic Surgery. Dr. Bendok is Professor in Neurological Surgery, Neurology, Otolaryngology, Head and Neck Surgery and Radiology. Dr. Prine is a Pain Fellow in Anesthesiology. Dr. Kendall is Research Assistant Professor of Anesthesiology.

Address Correspondence:
Mark C. Kendall, M.D.
Department of Anesthesiology
251 E. Huron, F5-704
Chicago, IL 60611
E-mail: m-kendall@northwestern.edu

Disclaimer: There was no external funding in the preparation of this manuscript.

Conflict of interest: Each author certifies that he or she, or a member of his or her immediate family, has no commercial association (i.e., consultancies, stock ownership, equity interest, patent/licensing arrangements, etc.) that might pose a conflict of interest in connection with the submitted manuscript.

Manuscript received: 05-21-2014
Revised manuscript received: 01-29-2015
Accepted for publication:
02-06-2015

Free full manuscript:
www.painphysicianjournal.com

Although pharmacological therapy is the primary treatment modality for trigeminal neuralgia associated pain, ineffective analgesia and dose limiting side effects often prompt patients to seek alternative pharmacological solutions such as interventional nerve blockade. Blockade of the Gasserian ganglion or its branches is an effective analgesic procedure for trigeminal neuralgia, traditionally performed using fluoroscopy or CT imaging. Ultrasonography allows point of care and real time visualization of needle placement within the surrounding anatomical structures. The use of ultrasonography with pulsed radiofrequency therapy for trigeminal neuralgia has not been reported.

Our case is a 66-year-old male suffering from trigeminal neuralgia for 4 years that was refractory to pharmacologic therapy. Neurological examination was normal with no sensory deficit. Imaging showed no vascular compression or mass involving the trigeminal nerve. A diagnostic ultrasound-guided trigeminal nerve block via the pterygopalatine fossa with 4 mL of bupivacaine 0.25% and 4 mg dexamethasone provided immediate pain relief (100%) with sustained analgesia >50% at 2 weeks. Pain relief was not sustained at one month, with return to pretreatment symptoms. A series of injections were performed with similar intermittent analgesic effectiveness. The decision was made that the patient was a suitable candidate for pulsed radiofrequency application in the pterygopalatine fossa.

We successfully used an alternative approach through the pterygopalatine fossa to treat trigeminal neuralgia using ultrasound guidance in an office setting. Our case demonstrates the utility of ultrasound-guidance pulsed radiofrequency treatment in the pterygopalatine fossa as a potential alternative to other percutaneous techniques for patients with medical refractory trigeminal neuralgia.

Key words: Pulsed radiofrequency, trigeminal nerve, ultrasound-guided, trigeminal neuralgia, facial pain

Pain Physician 2015; 18:E411-E415

Trigeminal neuralgia is one of the most painful debilitating conditions involving the face. The International Association for the Study of Pain defines trigeminal neuralgia as sudden, usually unilateral, severe, brief, stabbing, recurrent episodes of pain in the distribution of the trigeminal

nerve primarily involving the maxillary (V2) and mandibular branch (V3) (1). The American Academy of Neurology recommends pharmacological treatment as the first line of therapy (2). Although pharmacologic management is effective in about 75% of patients, a significant number of patients do

not achieve effective relief or experience intolerable side effects (3).

A temporary or permanent block of the trigeminal ganglion or one of the nerve branches with an injection of local anesthetics or steroids or application of low energy pulsed radiofrequency have been used in an effort to achieve long-lasting pain relief. More invasive procedures such as Gamma-Knife radiation, microvascular decompression, and radiofrequency ablation at 90°C have been shown to provide relief in treating trigeminal neuralgia (4) but are not without potential adverse effects.

X-ray guided therapy through the foramen ovale is considered the standard imaging modality in radiofrequency ablation of the trigeminal ganglion. However, x-ray techniques rely on bony anatomical landmarks which can be technically difficult and often challenging to interpret. The use of ultrasonography has increased from a diagnostic tool to a highly accurate imaging tool for needle localization for nerve blockade. The advantages of ultrasonography include bedside application, no radiation exposure, real-time visualization of soft tissues and needle tip advancement, and visualization of the injectate spread. We present a case of a refractory trigeminal neuralgia patient where ultrasound-guided pulsed radiofrequency application in the pterygopalatine fossa provided months of sustained pain relief.

CASE REPORT

A 66-year-old Caucasian man presented with a 4-year history of right-sided facial pain to the pain medicine clinic. The pain was unilateral and described as a sharp, stabbing, paroxysmal shooting that extended from below his right eye to the corner of his mouth including the right side of his tongue. The pain attacks were exacerbated by painless sensory stimulation to the perioral area such as talking, brushing teeth, and chewing. The patient was prescribed carbamazepine, gabapentin, and pregabalin by his primary care physician with minimal improvement in his symptoms. Increasing the dosage regimens was limited by intolerable vertigo and confusion. He was currently taking hydrocodone 10 mg with acetaminophen 325 mg every 4 hours as needed for pain with minimal pain relief. He was referred by his primary care physician to the neurosurgery center for further evaluation to confirm the diagnosis of trigeminal neuralgia (ICHD-II Diagnostic Criteria 13.1.1) and to exclude other treatable causes of facial pain.

The neurological examination was normal with no trigeminal sensory deficit. A magnetic resonance imag-

ing with and without contrast showed no evidence of vascular compression or mass involving the trigeminal nerves. After reviewing the patient's options and discussing possible surgical intervention, it was deemed that he was not a surgical candidate and it was agreed upon that he should be further evaluated by pain medicine specialists for further assessment and treatment of his unilateral facial pain.

In the pain medicine clinic, the patient received a diagnostic ultrasound-guided trigeminal nerve block via the pterygopalatine fossa with 4 mL of bupivacaine 0.25% and 4 mg dexamethasone. The procedure was performed by placing the patient in the left lateral recumbent position with the ultrasound machine positioned on the opposite side of the table (5). Standard ASA (American Society of Anesthesiologists) monitors were applied. The high frequency transducer probe (GE11-L) covered with a sterile sheath was positioned longitudinally on the side of the face just below the zygomatic bone, superior to the mandibular notch, and anterior to the mandibular condyle (Fig. 1A/1B). The lateral pterygoid muscle and maxillary artery were identified (LOGIQ P6; GE Healthcare, Waukesha, WI). Following negative blood aspiration, the injectate was placed in pterygopalatine fossa below the lateral pterygoid muscle anterior to the lateral pterygoid plate with real-time observation of the needle trajectory (Fig. 1C). Good local anesthetic spread was observed. No immediate paresthesia was reported and the patient experienced no complications. He reported immediate pain relief (100%) with sustainment of pain relief (> 50%) at 2 week follow-up; however, the pain relief was not sustained at one month. A series of injections were performed with similar intermittent analgesic effects. At this point the decision was made that the patient was a suitable candidate for pulsed radiofrequency application in the pterygopalatine fossa.

With the patient's consent, a pulsed radiofrequency application was performed at 42°C for 90 seconds. The cannula sheathed needle was positioned in the pterygopalatine fossa below the lateral pterygoid plate anterior to the maxilla. With sensory stimulation at 50 Hz, the patient reported pain along the back of the upper teeth at 0.7 V. Motor stimulation at 2 Hz reproduced a similar pain pattern at 1.0 V. Pulsed radiofrequency ablation was performed at 42°C for 90 seconds with impedance of 240 Ohms. The ablation procedure was followed by a 5 mL injection of bupivacaine 0.25% and triamcinolone 40 mg. The needle was withdrawn and there were no immediate complications. Following the

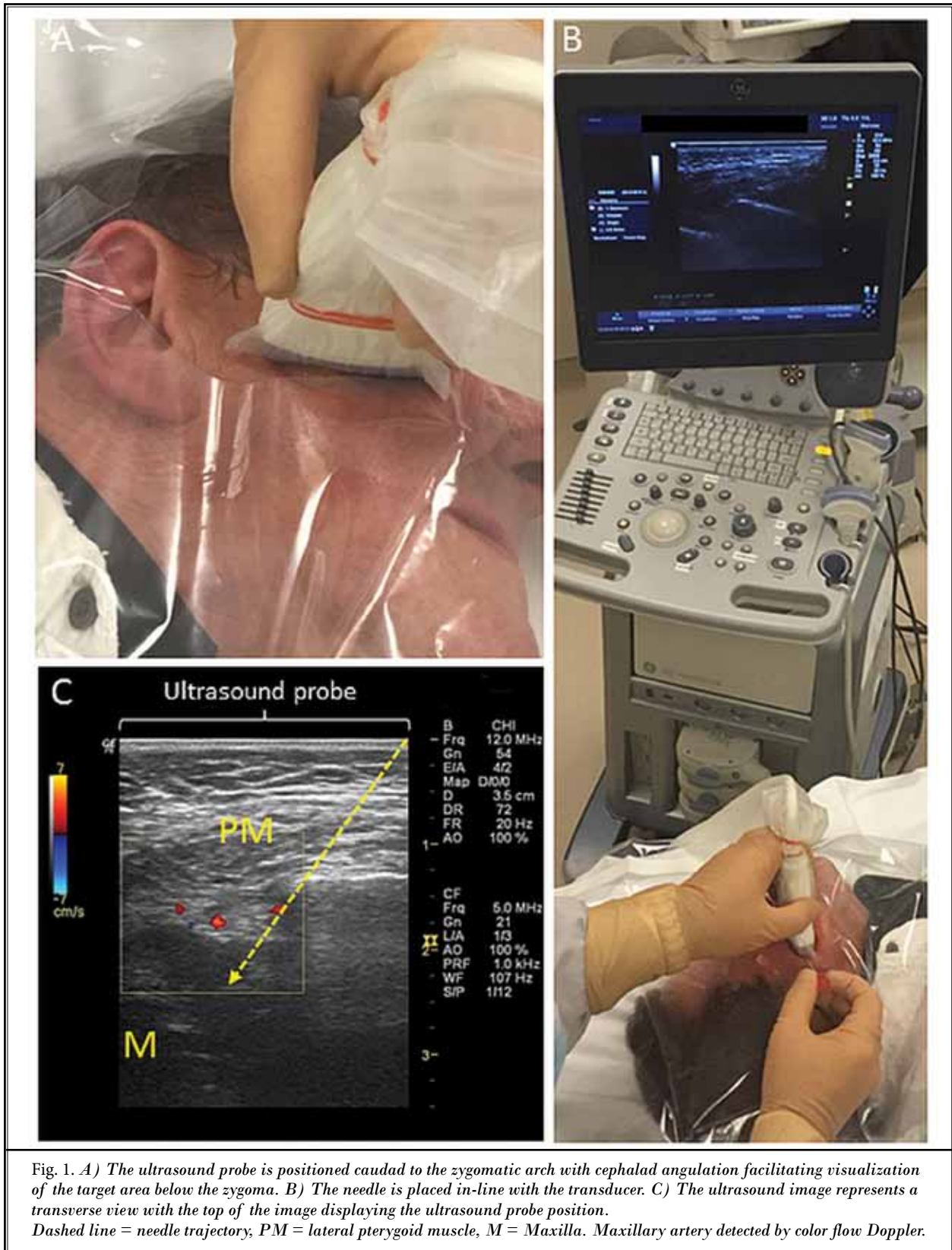


Fig. 1. A) The ultrasound probe is positioned caudad to the zygomatic arch with cephalad angulation facilitating visualization of the target area below the zygoma. B) The needle is placed in-line with the transducer. C) The ultrasound image represents a transverse view with the top of the image displaying the ultrasound probe position. Dashed line = needle trajectory, PM = lateral pterygoid muscle, M = Maxilla. Maxillary artery detected by color flow Doppler.

procedure the patient reported 100% pain relief immediately and currently experiences ongoing sustained pain relief for more than 6 months. No neurological side effects or complications were noted.

Discussion

We successfully and safely applied pulsed radiofrequency energy at 42°C in the pterygopalatine fossa using ultrasound guidance in an office setting. Within the pterygopalatine fossa resides the pterygopalatine ganglion and its branches, the maxillary branch of the trigeminal nerve, and the distal portion of the maxillary artery (6). The classic percutaneous approach to the Gasserian ganglion involves insertion of a cannula through the foramen ovale and is performed using x-ray in either the fluoroscopy suite or operating room, or CT in the radiology department. These methods rely on bony anatomical demarcations, making it difficult to accurately target neuronal tissues in the adjacent anatomical areas. CT scan guidance may result in excessive radiation exposure. When using this approach the radiofrequency cannula is advanced in a straight line towards the foramen ovale to reach Meckel's cave. This cave is a space formed between 2 layers of the dura matter that contains cerebrospinal fluid and is positioned at the posterolateral aspect of the cavernous sinus on either side of the sphenoid bone in the middle cranial fossa (7). The trigeminal ganglion lies within the Meckel's cave and gives rise to 3 branches, ophthalmic (V1), maxillary (V2), and mandibular (V3), which exit the skull through distinct foramina: the superior orbital fissure, the foramen rotundum and the foramen ovale. The stylet is removed from the cannula and aspiration is performed to ensure there is no cerebrospinal fluid or blood. The electrode is advanced 2 – 4 mm further through the canal of the foramen ovale such that the tip of the electrode reaches the junction of the petrous ridge of the temporal bone and the clivus. The ganglion is then disrupted using heat or glycerol, or by mechanical decompression resulting in potential hemifacial numbness, masseter numbness, and extratrigeminal sequelae such as trochlear nerve and oculomotor palsy (8,9).

Despite the success of nerve ablation procedures, adverse effects are likely encountered as a result of imprecise positioning of the needle which has lead clinicians to search for an alternative way to approach ablation of the trigeminal nerve and ganglion. In 260 rhizotomies, Blomstedt and Bergenheim (10) reported

technical difficulties of performing the procedure using this approach in 47% of patients. The procedures were complicated by vasovagal reactions, cardiac arrest, or difficulties of locating the trigeminal cistern in 8% of the patients. Transient or persistent sensory complications were as high as 67%, and more severe complications including dysesthesia (23%), chemical or infectious meningitis (1.5%), or anesthesia dolorosa (0.8%) occurred (10). Kanpolat et al (11) retrospectively reviewed 2,138 percutaneous radiofrequency rhizotomies of the trigeminal ganglion and reported a similar complication rate of masseter weakness (4.1%) and anesthesia dolorosa (0.8%), but a much reduced rate of diminished corneal reflex (5.7%) and dysesthesias (1%).

We performed our procedure in the pterygopalatine fossa. In contrast to x-ray guided procedures, ultrasonography allows visualization of the soft tissues and vascular structures in real time. Ultrasound guidance via the pterygopalatine fossa allows identification of the maxilla, lateral pterygoid plate, lateral pterygoid muscle, and the maxillary artery. This imaging tool is advantageous because it allows real-time visualization of the needle trajectory and needle tip placement in the targeted area.

Traditional radiofrequency lesioning of the Gasserian ganglion is thought to destroy the pain fibers by heat at > 65°C which helps reduce the pain but is responsible for the undesirable effects. An alternative method, pulsed radiofrequency is a nondestructive treatment that delivers short bursts of radiofrequency current from the tip of the electrode at 42°C with long pauses between to allow heat to dissipate in the target tissue. These short bursts of heat are thought to cause microscopic damage to axonal microfilaments and microtubules with greater changes occurring in C fibers than in A fibers, potentially minimizing the occurrence of sensory or motor deficit in the surrounding tissues (12). Erdine et al (13) performed an electron microscopic analysis comparing the effects of pulsed radiofrequency versus continuous radiofrequency current on rabbit dorsal root ganglion and reported that pulsed radiofrequency was substantially less destructive than continuous radiofrequency. However, a recent randomized controlled trial comparing conventional radiofrequency with pulsed radiofrequency in the traditional technique showed that pulsed radiofrequency was not effective in reducing pain in patients with trigeminal neuralgia (14). Therefore we believe that pulsed radiofrequency ablation using ultrasound guidance via the

pterygopalatine fossa may be an effective alternative method for treating medically refractory trigeminal neuralgia and can be used as a basis for conducting future studies.

CONCLUSION

Long-lasting response to therapy can be difficult to achieve in patients with trigeminal neuralgia. We have

described an alternative method to approach the trigeminal nerve branches through the pterygopalatine fossa. Our case suggests that ultrasound-guided pulsed radiofrequency treatment in the pterygopalatine fossa maybe a potential alternative to other percutaneous techniques and surgical options for patients with trigeminal neuralgia when pharmacological therapy is not sufficient or is not tolerated.

REFERENCES

1. Van Kleef M, Van Genderen WE, Narouze S, Nurmikko TJ, Van Zundert J, Geurts JW, Mekhail N. World Institute of Medicine. Trigeminal neuralgia. *Pain Practice* 2009; 9:252-259.
2. Cruccu G, Gronseth G, Alksne J, Argoff C, Brainin M, Burchiel K, Nurmikko T, Zakrzewska JM, American Academy of Neurology Society, European Federation of Neurological Society. AAN-EFNS guidelines on trigeminal neuralgia management. *Eur J Neurol* 2008; 15:1013-1028.
3. Dalessio DJ. Trigeminal neuralgia. A practical approach to treatment. *Drugs* 1982; 24:248-255.
4. Haridas A, Mathewson C, Eljamel S. Long-term results of 405 refractory trigeminal neuralgia. *Zentrabl Neurochir* 2008; 69:170-174.
5. Nader A, Kendall MC, DeOliveira GS, Chen JQ, Vanderby B, Rosenow JM, Bendock BR. Ultrasound-guided trigeminal nerve block via the pterygopalatine fossa: An effective treatment for trigeminal neuralgia and atypical facial pain. *Pain Physician* 2013; 16:E537-E545.
6. Kim HS, Kim DI, Chung IH. High-resolution CT of the pterygopalatine fossa and its communications. *Neuroradiology* 1996; 38:S120-S126.
7. Kamel HAM, Toland J. Trigeminal nerve anatomy: Illustrated using examples of abnormalities. *AJR Am J Roentgenol* 2001; 176:247-251.
8. Urculo E, Alfaro R, Arrazola M, Astudillo E, Rejas G. Trochlear nerve palsy after repeated percutaneous balloon compression for recurrent trigeminal neuralgia: Case report and pathogenic considerations. *Neurosurgery* 2004; 54:505-508.
9. Skirving DJ, Dan NG. A 20-year review of percutaneous balloon compression of the trigeminal ganglion. *J Neurosurg* 2001; 94:913-917.
10. Blomstedt PC, Bergenheim AT. Technical difficulties and perioperative complications of retrogasserian glycerol rhizotomy for trigeminal neuralgia. *Stereotact Funct Neurosurg* 2002; 79:168-181.
11. Kanpolat Y, Savas A, Bekar A, Berk C. Percutaneous controlled radiofrequency trigeminal rhizotomy for the treatment of idiopathic trigeminal neuralgia: 25-year experience with 1600 patients. *Neurosurgery* 2001; 48:524-532.
12. Bogduk N. Pulsed radiofrequency. *Pain Medicine* 2006; 7:396-407.
13. Erdine S, Yucel A, Cimen A, Aydin S, Sav A, Bilir A. Effects of pulsed versus conventional radiofrequency current on rabbit dorsal root ganglion morphology. *Eur J Pain* 2005; 9:251-256.
14. Erdine S, Bilir A, Cosman ER, Cosman ER Jr. Ultrastructural changes in axons following exposure to pulsed radiofrequency fields. *Pain Practice* 2009; 9:407-417.

