

Brief Commentary

Clostridium Sacroiliitis (Gas Gangrene) Following Sacroiliac Joint Injection – Case Report and Review of the Literature

Lakshmi N. Kurnutala, MD, Dipti Ghatol, MD, and Aman Upadhyay, MD

From: Department of
Anesthesiology, Henry Ford
Hospital, Detroit, MI

Address Correspondence:
Lakshmi N Kurnutala, MD
Department of
Anesthesiology, Henry Ford
Hospital,
2799, W Grand Blvd,
Detroit, MI. 48202
E-mail: drnarasimhulu_k@
yahoo.com:

Disclaimer: There was
no external funding in
the preparation of this
manuscript.

Free full manuscript:
www.painphysicianjournal.com

An 80-year-old woman presented with chronic lumbosacral pain since her laminectomy and instrumentation 10 years ago. Examination was consistent with left sacroiliitis, and the patient underwent an elective left sacroiliac joint injection. Two days following her procedure she fell and landed on her left hip and on the next day, she presented to the emergency room with acutely worsening left gluteal pain. On evaluation in the emergency department, she was found to be suffering from a fever, headache, nausea, vomiting, and dysuria. A computed tomography (CT) scan was performed and this showed extensive foci of gas throughout the posterior aspect of the left iliopsoas muscle, sacrum, and ileum surrounding the left sacroiliac joint. The patient underwent emergent surgical debridement. The microbiology report of blood culture revealed clostridium perfringens, while her pathology showed necrosis and acute inflammation of fibroadipose tissue, skeletal muscle, and fat. The patient's hospital course resulted in multi-organ failure and the family elected for comfort care measures only. Unfortunately, she passed away 36 hours later.

Septic arthritis is a potential catastrophic complication following intra-articular steroid therapy. The cause of the septic joint can be multifactorial but is likely caused by one of the following processes: direct inoculation of bacteria by the injection, hematogenous seeding of the percutaneous injection tract, or due to activation of a quiescent infection by the injected steroid. Clostridial spores are very resistant to standard aseptic skin preparations, including chlorhexidine and betadine solutions. The only effective methods to eliminate the spores is to heat them at a temperature greater than 100 degrees Celsius for 10 minutes or with use of a 10% potassium hydroxide (KOH) solution. We hypothesize that clostridium spores were present on the patient's skin from previous stool soiling, and that these were introduced directly into the soft tissue by needle trauma. Rare complications such as this one are scarcely reported in the literature and thus it becomes difficult to adequately identify risk factors or to formulate strategies to improve practice management.

Key words: Lower back pain, sacroiliitis, sacroiliac joint injection, clostridium perfringens, gas gangrene

The sacroiliac (SI) joint is a diarthrodial synovial joint with abundant innervation (1), and has been recognized as a source of pain in 10% to 25% of patients with persistent mechanical low back pain (2). SI joint injections can be performed for the treatment chronic lower back pain and they serve the dual role of being both diagnostic as well as therapeutic injections. (1,3,4). Despite the fact that the number of interventional procedures being performed for chronic pain has drastically increased over the past 2 decades, the overall incidence of infections has remained constant. In this report we

would like to discuss an incidence of gas gangrene due to clostridium perfringens following a SI joint steroid injection.

Case Report

An 80-year-old woman presented to the pain clinic with a recent exacerbation of her chronic low back pain. The patient has a history significant for L3-L5 laminectomy and instrumentation performed approximately 10 years ago. The patient's current pain was described as being left sided, non-radiating, and stabbing in nature. Thus far, treatment with naproxen sodium,

acetaminophen-hydrocodone, and physical therapy had provided minimal to no relief. She had received a lumbar epidural steroid injection at an outside hospital for similar pain in the past, but this afforded her with no relief. History and physical exam findings were consistent with a diagnosis of left-sided sacroiliitis. On physical exam she had a strongly positive Patrick's and Gaenslen's test, as well as tenderness over the left SI joint. The remainder of her past medical history was sig-

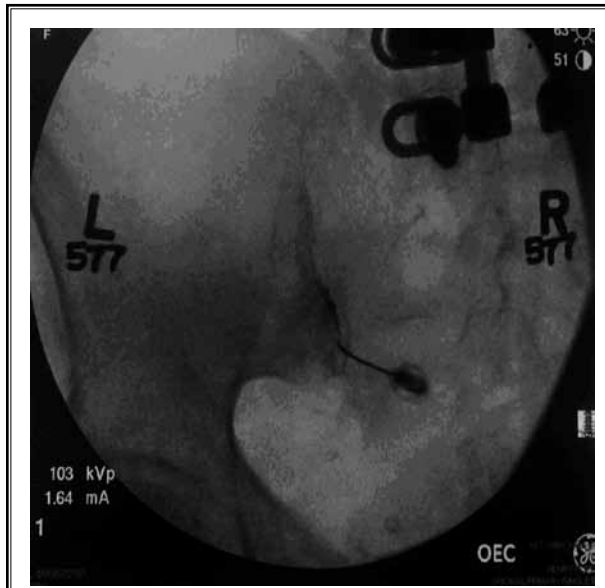


Fig. 1. Fluoroscopic image of left SI joint injection.

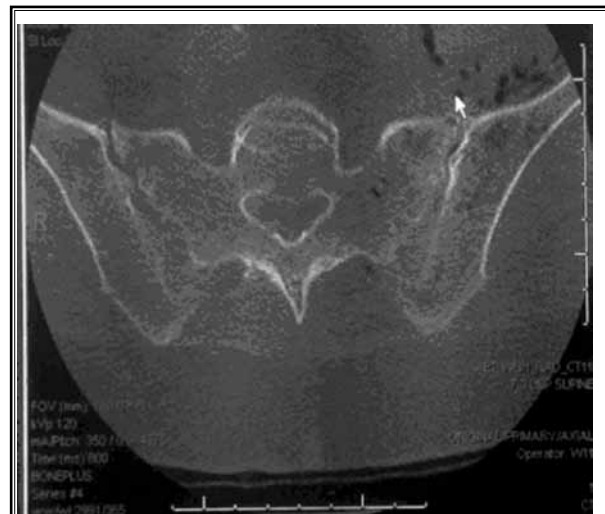

Fig. 2. CT Image of Pelvis - gas around left SI joint and iliopsoas muscle

nificant for well controlled diabetes, asthma, hypothyroidism, osteoarthritis of the knees, and breast cancer in 2001 with no remission. After having discussed the risks, benefits, and complications, she was scheduled for an elective left SI joint steroid injection under fluoroscopic guidance. On the morning of her procedure, she presented in good health, was hemodynamically stable, and did not display any constitutional symptoms suggestive of a pre-existing infection. She presented no evidence of skin break down or decubitus ulcerations at the injection site. After obtaining consent, she was taken to the procedure suite and was placed in the prone position and the lumbo-sacral area was prepared with a single use 26 mL applicator of 2% chlorhexidine gluconate and 70% isopropyl alcohol. Complete asepsis was maintained with the use of sterile drapes, sterile gloves, bouffant caps, and face masks. Under fluoroscopic guidance the lower pole of the left SI joint was identified and marked. The skin over the marked area was anesthetized with 1 mL of 1% lidocaine using a 27-gauge 1.5 inch needle. A 22-gauge 3½ inch spinal needle with stylet was advanced into the lower pole of the SI joint. After entering into SI joint, the stylet was removed, after negative aspiration of blood, air, and without eliciting any paresthesia, 0.5 mL of Isovue-300 contrast was injected and this confirmed excellent spread into the SI joint. We then injected 3 mL of a block solution (mixture of 2 mL of 0.5% preservative-free bupivacaine and 1 mL of methylprednisone 40 mg prepared by the pain physician performing the procedure under sterile precautions) into the left SI joint (Fig. 1). The patient tolerated the procedure well and was discharged home 30 minutes after the procedure with stable vital signs and now negative Patrick's test on the left.

Two days after her procedure, the patient suffered a fall, and landed on her left hip. The next day she began to suffer severe, sharp left gluteal pain and also had a fever, nausea, vomiting, dysuria, and a headache. This prompted her to present to the emergency department (ED). Laboratory evaluation in the ED revealed leukocytosis (WBC count- 12,600/mcL with pre-procedure WBC count 6,900/mcL). An emergent computed tomography (CT) scan showed extensive foci of gas throughout the posterior aspect of the left iliopsoas muscle, the sacrum, the ileum, and surrounding the left SI joint. This was highly suspicious for an aggressive infectious process, possibly representing septic arthritis of the left SI joint, emphysematous osteomyelitis of the left sacrum, and necrotizing fasciitis involving the left iliopsoas muscle (Fig. 2).

Broad-spectrum antibiotics were initiated and she was transferred to the intensive care unit (ICU) for further management. In the ICU she became hemodynamically unstable and required vasopressor support. She was assessed by trauma and orthopedic surgery and surgical debridement was recommended. She underwent an emergency exploration and debridement of the left iliopsoas and retroperitoneum. At the time of surgery, she was found to have a large volume of murky fluid and gas in the retroperitoneal tissue. She returned to the ICU on mechanical ventilation, under sedation, and on high dose vasopressors. Pathology of the soft tissue of the retroperitoneum revealed fibroadipose tissue, skeletal muscle with fat necrosis and acute inflammation. Blood culture results were positive for clostridium perfringens. In next 2 days she underwent repeat retroperitoneal washout and debridement. Despite continued antibiotic treatment, mechanical ventilation and vasopressor support, her clinical condition deteriorated. She developed acute renal failure and dialysis was recommended but due to her multi-organ failure, the patient's family elected to pursue comfort measures only. Terminal weaning was initiated and the patient was placed on a fentanyl drip. The patient died 36 hours after having started terminal weaning and 10 days after her SI joint injection (Table 1).

Discussion

Septic arthritis is a catastrophic complication following intra-articular steroid therapy. Its cause can be multifactorial but is typically due to one of the following mechanisms: direct inoculation of bacteria by the injection, hematogenous seeding of the percutaneous injection tract, or due to activation of a quiescent infection by the injected steroid. Bacterial arthritis of any cause is associated with up to 15% mortality and residual impairment of joint function is present in 50% patients (5). Risk factors associated with joint infections are joint surgery, pre-existing joint disease, diabetes mellitus, presence of prosthetic material, localized skin infection, advanced age, and immunosuppressive medication (5).

On review of the orthopedic literature, there are only a few case reports of gas gangrene of a joint, and these are mainly associated with traumatic fractures and punctured wounds with soft tissue contamination (6-8). Clostridial myonecrosis following intraarticular injection of steroid (9-12) has been reported in the literature. In these cases the patients received either an intraarticular shoulder or knee steroid injection, result-

Table 1. *Timeline of Events:*

Day 0- Sacroiliac joint injection
↓
Day 2- Fall at home over left hip.
↓
Day 3- Emergency room for worsening of left hip pain, fever, nausea, vomiting, dysuria and vomiting, WBC-12,600/L, CT scan- gas in the soft tissue suspicious for necrotizing fasciitis, antibiotics, hospitalization.
↓
Day 4- ICU- Hemodynamic instability, Norepinephrine infusion, Surgical debridement, Postoperative ventilation.
↓
Day 5 -Repeat retroperitoneal washout. Blood cultures clostridium perfringens.
↓
Day 6- Acute renal failure, decreased UO
↓
Day 7- Repeat washout and debridement with fascial closure
↓
Day 8- continued worsening of electrolyte abnormality and uremia, dialysis refused, terminal weaning and comfort care
↓
Day 10-Death

ing in subsequent fatal gas gangrene.

Clostridium perfringens is the most common organism that causes traumatic gas gangrene, whereas spontaneous gas gangrene is most commonly caused by clostridium septicum. Clostridium perfringens is an anaerobic, gram positive, spore forming rod. It is a common inhabitant in the gastrointestinal tract of mammals and in the soil (6). Clostridium perfringens is the most common clinical isolate, especially of soft tissue infections involving gas gangrene (13). The incubation period is typically 24 – 48 hours but can be as early as 6 hours. It is important to note that the clostridial spores are resistant to standard practices of aseptic skin preparation, including the use of chlorhexidine or betadine. The only effective method to eliminate these spores is with the use of direct heat at a temperature greater than 100 degrees Celsius for 10 minutes or with 10% potassium hydroxide (KOH) solution (11).

During a SI joint steroid injection, there is always the potential risk of contamination from the physician hands, needles, medications, or from the area of the block. Although our procedure was performed in a des-

ignated procedure room using all aseptic precautions possible, the above risks still cannot be completely excluded. The clinical presentation in most cases of gas gangrene is with a fulminant skin and tissue necrosis with gas formation, and extensive infection leading to septicemia. Treatment usually requires surgical exploration and debridement supplemented with intravenous antibiotics. In our patient, even after repeated surgical exploration and debridement and treatment with broad spectrum antibiotics, the patient's condition deteriorated, leading to acute renal failure, hemodynamic instability, and a prolonged ventilatory requirement. Eventually the patient died due to her septicemia while receiving comfort care.

On review of the existing literature we found only one prior case report of clostridial myonecrosis following SI joint injection at the Mayo clinic (14). The patient had a history of stool incontinence and the authors had hypothesized that the site of injection was contaminated by clostridial spores and they were introduced into the soft tissue by the needle injection. Our patient differs in that she had no known history of any fecal incontinence but had a history of a fall onto the left hip after the procedure and a history of diabetes. The possi-

ble hypothesis for the clostridial infection in our patient is likely skin contamination with clostridial spores prior to the actual SI joint injection. Following the injection, the spores were likely translocated into the soft tissue leading to myonecrosis. Another possible mode of infection could have been skin contamination with soil at her injection site following her procedure, when she had her fall. In either case she likely had impaired host defenses due to her diabetic state.

CONCLUSION

Clostridial sacroiliitis is a rare but potentially fatal complication of an intraarticular SI joint steroid injection. Any worsening joint pain or discomfort should be thoroughly investigated to rule out any possible joint infection. Rare complications such as this one are scarcely reported in the literature and thus it becomes difficult to adequately identify risk factors or to formulate strategies to improve practice management. Practitioners in the field of interventional pain management need to be encouraged to report complications more regularly so that our group as a whole can give better patient care in the future.

REFERENCES

- Hansen HC, McKenzie-Brown AM, Cohen SP, Swicegood JR, Colson JD, Manchikanti L. Sacroiliac joint interventions: A systematic review. *Pain Physician* 2007; 10:165-184.
- Simopoulos TT, Manchikanti L, Singh V, Gupta S, Hameed H, Diwan S, Cohen SP. A systematic evaluation of prevalence and diagnostic accuracy of sacroiliac joint interventions. *Pain Physician* 2012; 15:E305-E344.
- Hart R, Wendsche P, Kociš J, Komzák M, Okál F, Krejzla J. Injection of anaesthetic-corticosteroid to relieve sacroiliac joint pain after lumbar stabilization. *Acta Chir Orthop Traumatol Cech* 2011; 78:339-342. (Article in Czech, abstract in English)
- Rupert MP, Lee M, Manchikanti L, Datta S, Cohen SP. Evaluation of sacroiliac joint interventions: A systematic appraisal of the literature. *Pain Physician* 2009; 12:399-418.
- Charalambous CP, Tryfonidis M, Sadiq S, Hirst P, Paul A. Septic arthritis following intra-articular steroid injection of the —knee – a survey of current practice regarding antiseptic technique used during intra-articular steroid injection of the knee. *Clin Rheumatol* 2003; 22:386-390.
- Schiller M, Donnelly PJ, Melo JC, Raff MJ. Clostridium perfringens septic arthritis. Report of a case and review of the literature. *Clin Orthop Relat Res* 1979; 139:92-96.
- Harrington TM, Torretti D, Viozzi FJ, Davis DE Clostridium perfringens. An unusual case of septic arthritis. *Ann Emerg Med* 1981; 10:315-317.
- Fauser DJ, Zuckerman JD Clostridial septic arthritis: Case report and review of the literature. 1988; 31:295-298.
- Spindler AJ, Musa H. Clostridium sor-delli septic arthritis: A case report. *Clin Orthop Rel Res* 1989; 241:245-247.
- Seradge H, Anderson MG. Clostridial myonecrosis following intra-articular steroid injection. *Clin Orthop Relat Res* 1980; 147:207-209.
- Yangco BG, Germain BF, Deresinski SC. Case report of fatal gas gangrene following intraarticular steroid injection. *Am J Med Sci* 1982; 283:94-98.
- Nolan B, Leers WD, Schatzker J. Septic arthritis of the knee due to clostridium bifermentans: Report of a case. *J Bone Joint Surg Am* 1972; 54:1275-1278.
- Mandell GL, Bennett JE, R D. Mandell, Bennett, and Dolin. *Principles and Practice of Infectious Diseases. 6th edition*, Philadelphia, PA, Churchill Livingstone, 2005.
- McHugh RC, Tiede JM, Weingarten TN. Clostridial sacroiliitis in a patient with fecal incontinence: a case report and review of the literature. *Pain Physician*. 2008 Mar-Apr;1:249-1252.