

Prospective Evaluation

## Symptomatic Cervical Vertebral Hemangioma Treated by Percutaneous Vertebroplasty

Wang Jian, MD

From: Xinqiao Hospital  
China

Address correspondence:  
Wang Jian, MD  
Xinqiao Hospital  
Dept. of Orthopaedics  
Xinqiao Street,  
Shapingba District  
China

E-mail:  
tonywjxq@yahoo.com.cn

Disclaimer: There was no  
external funding in the  
preparation of this manuscript.  
Conflict of interest: None.

Manuscript received: 02-15-2013  
Revised manuscript received:  
03-20-2013 Accepted for  
publication:  
04-01-2013

Free full manuscript:  
www.painphysicianjournal.com

**Background:** Vertebral hemangioma (VH) is considered to be a benign lesion of bone with a rich vasculature. Most incidentally discovered hemangiomas are asymptomatic. Percutaneous vertebroplasty (PVP) has demonstrated efficacy in the treatment of symptomatic thoracic and lumbar VHS. To our knowledge, the reports concerning PVP on symptomatic cervical VHS are quite rare.

**Objective:** Our intent was to assess PVP as treatment for symptomatic cervical hemangiomas.

**Study Design:** Prospective evaluation.

**Setting:** An interventional pain management practice, single medical center.

**Methods:** Eight patients with symptomatic cervical VHS were enrolled between December 2008 and February 2012, all of whom underwent magnetic resonance imaging (MRI) of the cervical spine. The patients with 8 vertebral bodies of VHS were treated by using PVP. The clinical and radiological data were collected and analyzed. Postoperative outcomes were determined using a visual analog scale.

**Results:** Surgical levels include C3 (2 patients), C4 (3 patients), C5 (2 patients), and C6 (one patient). The average follow-up period was 27.4 months, with a minimum of 12 months. Mean operative time and x-ray exposure time were respectively  $35 \pm 7.1$  minutes and  $25 \pm 7.7$  seconds. The visual analogue scale for neck pain decreased significantly from  $6.9 \pm 0.6$  preoperatively to  $1.3 \pm 0.5$  ( $P < 0.01$ ) on the second day after surgery, with a final score of  $1.2 \pm 0.5$  ( $P < 0.01$ ). Cement distribution was always diffuse and homogeneous. No cement leakage was observed in all cases except for 2 patients. There were no other major complications at the time of last follow-up evaluation.

**Limitations:** An observational clinical trial with a relatively small sample size.

**Conclusion:** Short-term results indicate that PVP appears to be an effective and safe treatment for symptomatic cervical VHS.

**Key words:** Percutaneous vertebroplasty, symptomatic, cervical vertebral, hemangiomas

**Pain Physician 2013; 16:-E419-E425**

**V**ertebral hemangiomas (VHS) are benign lesions of dysembryogenetic origin leading to resorption of underlying bone (1,2). Usually not more than one vertebra is involved. Most incidentally discovered hemangiomas are asymptomatic. Only 0.9 – 1.2% of all hemangiomas are

symptomatic (3,4). Magnetic resonance imaging (MRI) is helpful for the differentiation between intraosseous and extraosseous hemangioma. In a large majority of symptomatic VHS, pain is the most conspicuous and distressing symptom. With VHS a variety of treatment modalities are used, such as surgery (5), alcohol ablation

(6), endovascular embolization (7), radiotherapy (8,9), percutaneous vertebroplasty (10-13), and balloon kyphoplasty (14-16). Surgical therapy has been the treatment of choice for aggressive VHs, which increases the risk of complications related to bleeding and trauma. Intralesional injection of absolute alcohol, in spite of its high efficacy, is rarely performed because of a high incidence of severe complications. Endovascular treatment is rarely used as an independent treatment modality. Radiation-related sarcoma development in the late period has been reported (17).

As previously mentioned, the most common symptom of VHs is pain. Recently, percutaneous vertebroplasty (PVP) has been introduced into clinical practice as an alternative to the surgical and radiotherapy therapy of symptomatic VHs with or without features of aggressiveness at imaging studies. PVP is efficacious and safe to treat symptomatic VHs. Compared with other techniques, PVP is a valuable, minimally invasive procedure and provides immediate and lasting pain relief in carefully selected patients with symptomatic VHs. To our knowledge, few studies on the treatment of symptomatic cervical VHs using PVP have been reported.

## METHODS

From December 2008 to February 2012, 8 consecutive patients with symptomatic cervical VHs were treated with PVP, with a mean age of 43 years (range, 31-52). Each patient had a diagnosis of VHs made based on clinical symptoms, neurologic examinations, and confirmatory MRI evidence of the cervical spine (Figs. 1, 2). The study was approved by our Institutional Review Board and all of patients signed an informed consent form. The patients with symptomatic VHs presented neck pain and varying degrees of shoulder pain. Patients complained of neck pain ( $n = 8$ ), unilateral shoulder pain ( $n = 3$ ), and bilateral shoulder pain ( $n = 2$ ). No radiculopathy and myelopathy occurred in this series. Surgical areas include C3 in 2 patients, C4 in 3 patients, C5 in 2 patients, and C6 in one patient. Patients with the following conditions were excluded: more than one level, extraosseous VHs, or VHs with compression fracture or neurological deficit. All of the PVP procedures were performed by the first author. The patients' demographic data and clinical characteristics are listed in Table 1.

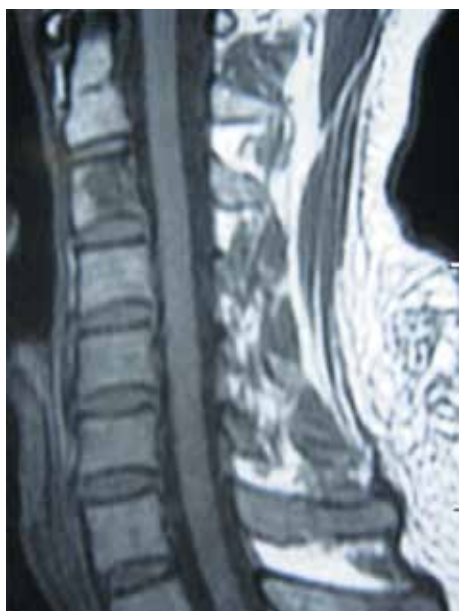

Fig. 1. T1-weighted sagittal MRI image of 43-year-old man with neck and left shoulder pain revealed low signals at the C3 vertebral body.

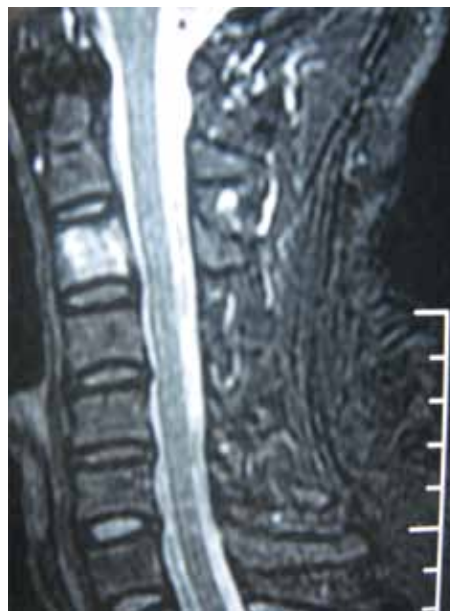

Fig. 2. T2-weighted sagittal MRI showed well-distributed high signals.

Table 1. Patient Demographic Data and Clinical Characteristic

Number	Gender	Age	Neck Pain VAS	Lesion Site	Clinical Presentation
1	Male	43	7	C3	Neck and left shoulder pain
2	Male	52	6.5	C4	Neck pain
3	Female	37	7.4	C4	Neck and bilateral shoulder pain
4	Female	31	7.2	C6	Neck and left shoulder pain
5	Male	50	6.1	C3	Neck pain
6	Female	39	7.5	C5	Neck and bilateral shoulder pain
7	Female	47	6.0	C4	Neck and right shoulder pain
8	Female	45	7.2	C5	Neck pain

### Surgical Technique

All PVP procedures were performed in a surgical operating room. Local anesthesia was used. With the patient in the supine position, the skin was prepared and draped in a standard fashion. The targeted vertebral body was determined by lateral fluoroscopy. After palpating the beats of the carotid artery, the surgeon pushed the trachea or larynx toward the opposite side with the index finger and then slipped the finger inside towards the front of the vertebral body. A small skin incision was made along the medial border of the right sternocleidomastoid muscle at the targeted site. Under anteroposterior (AP) and lateral fluoroscopic guidance, the angle and direction of the puncture needle (10 gauge bone access needle used specially for PVP procedure) would be adjusted before it arrived at the anterior surface of the vertebral body by opening the natural tissue planes medial to the carotid artery sheath and lateral to the trachea and esophagus. Under fluoroscopic control, the puncture needle was gradually advanced to 5 mm within the vertebral body. The puncture needle was then removed and replaced by a guiding needle. A working channel was then inserted into the lesion area along the guiding needle. Care must be taken to avoid advancing the guiding needle further as the working channel was placed. Intraoperative venography was performed with injection of nonionic contrast material into vertebral body in the first case. The venography was not performed for the other patients.

Bone cement (polymethylmethacrylate, PMMA) was prepared into the "toothpaste" stage. The cement introduction was always performed under lateral fluoroscopic visualization with a slow and careful injection of high viscosity material (Fig. 3). The mixture should be visualized filling the vertebral body (Figs. 4, 5). Injec-

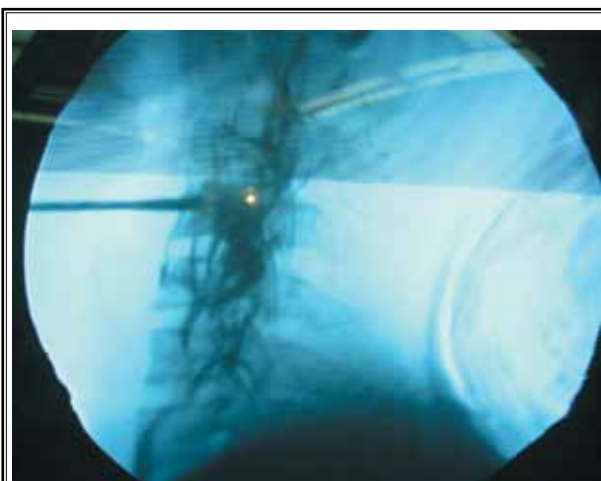


Fig. 3. Bone cement was injected into the C4 vertebral body under fluoroscopic control.

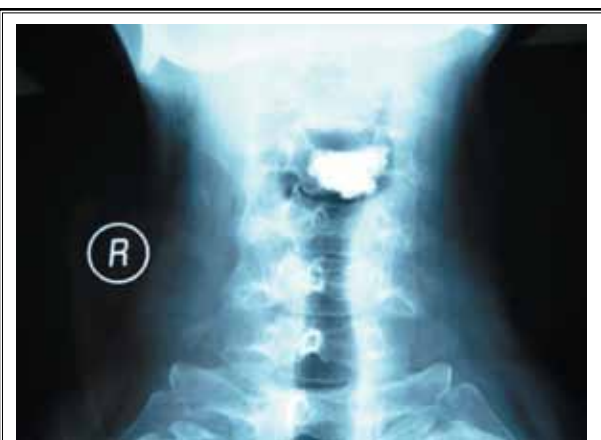

Fig. 4. Postoperative AP radiograph of a 52-year-old male with symptomatic C4 VH showed cement filling within the vertebral body.

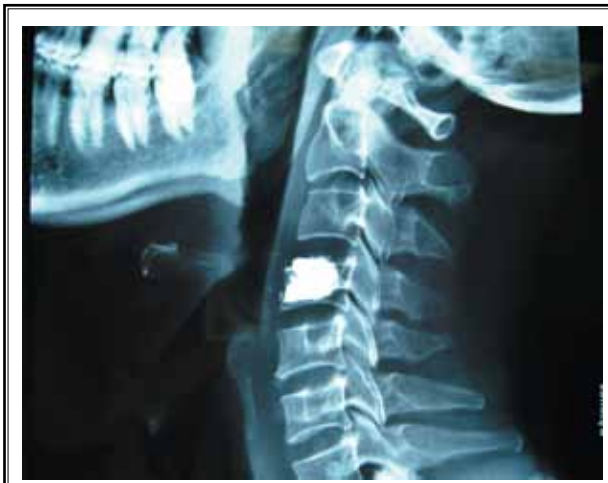

Fig. 5. Postoperative lateral radiograph revealed adequate and homogeneous cement distribution.

tion was halted if PMMA began to escape the vertebral body into vasculature, through an endplate into a disc, or into the posterior aspect of the vertebral body near the thecal sac. After surgery, the patient was ordered to lie down for 2 hours, before gradually sitting up and walking slowly. They were also given post-procedural instructions including avoidance of strenuous activity for 24 hours.

### Clinical and Radiological Evaluation

Pre-operative radiological evaluation included AP and lateral plain radiograph and MRI. Operative time, x-ray exposure time, and complications were collected. Post-operative radiographs were obtained for documentation of cement filling and to determine whether any cement leakage has occurred. Neck pain was quantified by visual analog scale (VAS) scores collected

from the patients pre-operatively, post-operatively, and during last follow-up.

### Statistical Analysis

Statistical analyses were performed using SPSS 13.0 for windows (SPSS, Inc., Chicago, IL, USA. Data are shown as mean  $\pm$  SD. Student t-test was used for the comparison of continuous variables. *P* values below 0.05 were considered significant.

### RESULTS

Eight patients with symptomatic cervical VHs who had undergone a PVP in our department were analyzed. The study included 3 men and 5 women with a mean age of 43 years (range, 31-52 years). Average follow-up time was 27.4 months (range, 12-37 months). The mean operative time and x-ray exposure time were respectively  $35 \pm 7.1$  minutes and  $25 \pm 7.7$  seconds. Usually one to 2 mL of bone cement was enough to fill up the lesion but not the entire vertebral body. On the second day after the procedure and the last follow-up, the VAS for neck and shoulder pain scores respectively decreased from  $6.9 \pm 0.6$  preoperatively to  $1.3 \pm 0.5$  and  $1.2 \pm 0.5$ . These pre- and post-operative outcome variables had statistical significance ( $P < 0.01$ ). The operative data and clinical outcomes are shown in Table 2. Cement distribution was diffuse and homogeneous in all 8 cases. Paravertebral cement leakage was only observed in 2 patients without clinical symptoms (Fig. 6). There were no other major complications related to the surgery such as such as esophageal perforation, carotid artery laceration, spinal cord or nerve root injury, and dysphagia.

### DISCUSSION

VHs are characterized by diverse clinical histories, radiological features, and results of different treat-

Table 2. Operative Data and Clinical Results in 8 patients

No.	operative time (min)	X-ray exposure time (second)	neck pain VAS at the second day	neck pain VAS at final follow-up	neurological function	complication
1	48	36	1.3	2.0	normal	cement leakage
2	39	35	1.0	1.0	normal	cement leakage
3	35	26	1.5	0.5	normal	none
4	28	23	2.0	1.3	normal	none
5	40	27	1.0	1.4	normal	none
6	30	20	2.0	1.0	normal	none
7	27	14	1.0	0.5	normal	none
8	33	19	0.8	1.5	normal	none

ments. Usually asymptomatic for a lifetime, VHs may cause symptoms in 1% of cases, the most common symptom being local pain. Rarely it may cause neurological symptoms and compressive myelopathy and thus should be considered in the differential diagnosis of metabolic, inflammatory, and neoplastic myelopathies. Predominant anatomical sites are the thoracic and the upper lumbar spine. It is very rare that symptomatic VHs occur in the cervical spine. Four cases with symptomatic cervical VHs were reported in a clinical study of 86 consecutive patients (2). MRI is highly sensitive to spinal hemangiomas. VHs with aggressive behavior present with low signal intensity on T1-weighted and high signal intensity on T2-weighted MRI.

VHs causing pain only and having no extraosseous extension can be treated with alcohol ablation, endovascular embolization, radiotherapy, PVP, or kyphoplasty, whereas those with progressive neurological deficits should be treated with surgery (18). Intralésional injection of absolute alcohol and endovascular therapy is rarely performed because of complications and other disadvantages. Radiation-related sarcoma development in the late period has been reported (17), which may be challenging.

Vertebroplasty, the percutaneous administration of acrylic bone cement into a vertebral body, was developed in France in 1984, initially as a treatment for a painful VH (19). To the best of our knowledge, there are few reports in English describing PVP as a treatment for symptomatic cervical VHs, although this procedure has been used extensively in the treatment of painful VHs occurring in thoracic and lumbar spine (10-16). Vertebroplasty was performed using a posterior approach and 4 mL acrylic cement was injected into the center of the intraosseous component of the C7. Surgery performed 5 days later consisted of excision of the intracanalicular part of the hemangioma (12). Feydy et al (20) reported significant improvement of symptoms in 2 cases with cervical VHs treated by vertebroplasty. A 14 G needle was introduced in the vertebral body by an anterolateral approach. Dousset et al (21) reported a 17-year-old asymptomatic patient with a partially collapsed seventh cervical vertebra due to a hemangioma treated by PVP. A 3 mm diameter, 10 cm long needle was placed in the center of the vertebral body via an anterolateral approach. The patient remains asymptomatic a year later.

PVP technique involves injection of acrylic cement, usually PMMA, into the vertebral body. The mechanism of action for this procedure is not entirely clear, but it

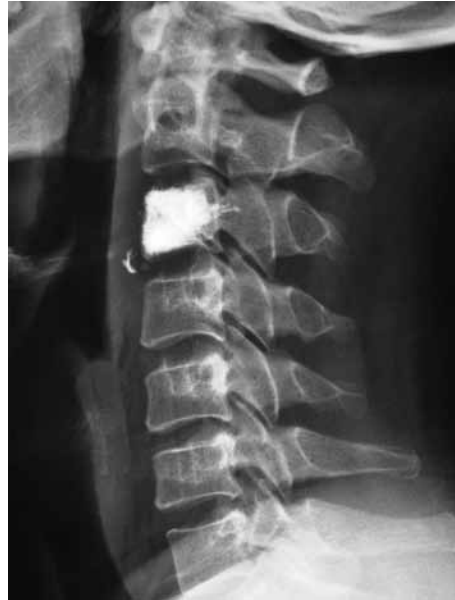

Fig. 6. Paravertebral cement leakage was found in one patient with symptomatic C3 VH.

is believed that stabilization of microfractures, prevention of further compression, and PMMA-chemical ablation of pain-sensitive neural roots in the vertebral body provide a cure for the pain. It is preserved for lesions causing pain only and is not suitable for lesions showing extraosseous extension (22). In addition, PMMA-related spinal cord injuries have been reported secondary to PMMA escaping into the spinal canal.

The target site for deposition of cement is the hemangioma lesion within the vertebral body. The anterolateral approach is chosen to allow the needle tip to terminate as close as possible to the target site in the cervical spine, which is different from the transpedicular and parapedicular approach in the thoracic and lumbar spine. The unilateral approach is enough to obtain optimum injection in the cervical spine. By taking an anterolateral approach, and entering bone at the anterior margin of the vertebral body, it is easy to position the needle tip in the anterior third of the vertebral body by unilateral access. Care must be taken to not place the needle too deeply, which may increase the complication risk.

Intraoperative intraosseous venography shows plentiful draining veins around vertebral body and predicts the direction of cement leaking to veins effectively, which could provide valuable information in taking

measures to prevent cement leakage. It is stressed that cement should be injected very slowly in the "tooth-paste" stage. AP and lateral fluoroscopic guidance is very useful for direct visualization of flow during cement injection. AP projection must be viewed intermittently to be sure there is no escape into vasculature lateral to the vertebral body. Injection should be halted before PMMA may escape the vertebral body into vasculature, through an endplate into a disc, or into the posterior aspect of the vertebral body near the thecal sac. A relatively small volume of cement (1-2 mL) may achieve adequate filling in the cervical spine. As a part of the PVP technique, we emphasize slow and careful cement injection under fluoroscopy.

A decrease in pain is evident immediately after the procedure. The VAS for neck and shoulder pain decreased from  $6.9 \pm 0.6$  pre-operatively to  $1.3 \pm 0.5$  at the second day post-operatively ( $P < 0.01$ ). Persistent pain relief was obtained in all patients. The final VAS for neck and shoulder pain was  $1.2 \pm 0.5$  at last follow-up. Paravertebral cement leakage was found in 2 patients without any symptomatic complications. There were no

other major complications such as esophageal perforation, carotid artery laceration, spinal cord or nerve root injury, and dysphagia.

### LIMITATIONS

There are several limitations to the present study. Aside from the small sampling and brief follow-up interval, the procedural outcomes were measured subjectively as patient pain scores. A randomized controlled trial for comparing PVP with other therapies should be considered to provide convincing evidence-based conclusions in the future.

### CONCLUSION

Short-term outcomes indicate that PVP appears to be a safe and highly effective treatment for symptomatic cervical VH. The anterolateral approach for cervical VH offers sufficient and safe access to the pathological entities and ensures effective and safe cement injection without major complications.

### REFERENCES

- Raco A, Ciappetta P, Artico M, Salvati M, Guidetti G, Guglielmi G. Vertebral hemangiomas with cord compression: The role of embolization in five cases. *Surg Neurol* 1990; 34:164-168.
- Pastushyn AI, Slin'ko EI, Mirzoyeva GM. Vertebral hemangiomas: Diagnosis, management, natural history and clinicopathological correlates in 86 patients. *Surg Neurol* 1998; 50:535-547.
- Nguyen JP, Djindjian M, Gaston A. Vertebral hemangiomas presenting with neurologic symptoms. *Surg Neurol* 1987; 27:391-397.
- Bremnes RM, Hauge HN, Sagsveen R. Radiotherapy in the treatment of symptomatic vertebral hemangiomas: Technical case report. *Neurosurgery* 1996; 39:1054-1058.
- Kato S, Kawahara N, Murakami H, Demura S, Koshioka Y, Okayama T, Fujita T, Tomitani K. Surgical management of aggressive vertebral hemangiomas causing spinal cord compression: Long-term clinical follow-up of five cases. *J Orthop Sci* 2010; 15:350-356.
- Goyal M, Mishra NK, Sharma A, Gaikwad SB, Mohanty BK, Sharma S. Alcohol ablation of symptomatic vertebral hemangiomas. *AJNR Am J Neuroradiol* 1999; 20:1091-1096.
- Jayakumar PN, Vasudev MK, Srikanth SG. Symptomatic vertebral hemangioma: Endovascular treatment of 12 patients. *Spinal Cord* 1997; 35:624-628.
- Miszczuk L, Tukiendorf A. Radiotherapy of painful vertebral hemangiomas: The single center retrospective analysis of 137 cases. *Int J Radiat Oncol Biol Phys* 2012; 82:e173-e180.
- Rades D, Bajrovic A, Alberti W, Rudat V. Is the dose-effect relationship for the treatment of symptomatic vertebral hemangioma? *Int J Radiat Oncol Biol Phys* 2003; 55:178-181.
- Cotton A, Boutry N, Cortet B, Assaker R, Demondion X, Leblond D, Chastanet P, Duquesnoy B, Deramond H. Percutaneous vertebroplasty: State of the art. *Radiographics* 1998; 18:311-320.
- Deramond H, Depriester C, Galibert P, Le Gars D. Percutaneous vertebroplasty with polymethylmethacrylate. Technique, indications, and results. *Radiol Clin North Am* 1998; 36:533-546.
- Ide C, Gangi A, Rimelin A, Beaujeux R, Maitrot D, Buchheit F, Sellal F, Diemann JL. Vertebral hemangiomas with spinal cord compressions: The place of preoperative percutaneous vertebroplasty with methyl methacrylate. *Neuroradiology* 1996; 38:585-589.
- Brunot S, Berge J, Barreau X, Ménégon P, Dousset V. Long term clinical follow up of vertebral hemangiomas treated by percutaneous vertebroplasty. *J Radiol* 2005; 214:314-318.
- Jones JO, Bruel BM, Vattam SR. Management of painful vertebral hemangiomas with kyphoplasty: A report of two cases and a literature review. *Pain Physician* 2009; 12:297-303.
- Muto M, Perotta V, Guarnieri G. Vertebroplasty or kyphoplasty: Friends or foes? *Radiol Med* 2008; 113:1171-1184.
- Hao J, Hu ZM. Percutaneous cement vertebroplasty in the treatment of symptomatic vertebral hemangiomas. *Pain Physician* 2012; 15:43-49.
- Acosta FL, Dowd CF, Chin C, Tihan T, Ames CP, Weinstein PR. Current treatment strategies and outcomes in the management of symptomatic vertebral hemangiomas. *Neurosurgery* 2006; 58:287-295.
- Vergel De Dios AM, Bond JR, Shives TC, McLeod RA, Unni KK. Aneurysmal bone

- cyst. A clinicopathologic study of 238 cases. *Cancer* 1992; 69:2921-2931.
19. Galibert P, Deramond H, Rosat P, Le Gars D. [Preliminary note on the treatment of vertebral angioma by percutaneous acrylic vertebroplasty.] *Neuro Chir* 1987; 33:166-168.
  20. Feydy A, Cognard C, Miaux Y, Solatínez MT, Weill A, Rose M, Chiras J. Acrylic vertebroplasty in symptomatic cervical vertebral haemangiomas: Report of 2 cases. *Neuroradiology* 1996; 38:389-391.
  21. Dousset V, Mousselard H, de Monck d'User L, Bouvet R, Bernard P, Vital JM, Senegas J, Caillé JM. Asymptomatic cervical haemangioma treated by percutaneous vertebroplasty. *Neuroradiology* 1996; 38:392-394.
  22. Cohen JE, Lylyk P, Ceratto R, Kaplan L, Umanskyt F, Gomori JM. Percutaneous vertebroplasty: Technique and results in 192 procedures. *Neurol Res* 2004; 26:41-49.

