

Case Control Study

Lumbar Retrodiscal Versus Post-Ganglionic Transforaminal Epidural Steroid Injection for the Treatment of Lumbar Intervertebral Disc Herniations

Chan Hong Park, MD, PhD, Sang Ho Lee, MD, PhD, and Hahck Soo Park, MD

From: Department of Anesthesiology and Pain Medicine, Daegu Woorldul Spine Hospital, Daegu, South Korea

Address correspondence:
Hahck Soo Park, MD
Department of Anesthesiology and Pain Medicine, School of Medicine, Ewha Womans University, 911-1, Mok 5-dong, Yangcheon-gu, Seoul 158-710, Korea
E-mail: ingo097@lycos.co.kr

Disclaimer: There was no external funding in the preparation of this manuscript.

Conflict of interest: None.

Manuscript received: 10/20/2010
Revised manuscript received: 01/02/2011
Accepted for publication: 05/25/2011

Free full manuscript:
www.painphysicianjournal.com

Background: Lumbar transforaminal epidural steroid injections (TFESIs) are procedures often utilized in the treatment of radicular pain. TFESIs with a preganglionic approach have been reported to be more effective than TFESIs performed using a classic approach. However, it is unknown whether TFESIs using a retrodiscal approach are as effective as other approaches.

Objective: To investigate the effect of an epidural steroid injection (ESI) on radicular pain, we conducted a randomized, controlled trial comparing a retrodiscal approach with a classic approach to treat lumbar disc herniation.

Design: A case control study.

Methods: Forty patients were randomized to receive lumbar TFESIs with either a retrodiscal approach (n=20) or with a classic approach (n=20). Measurements were taken before as well as 4 and 8 weeks after treatment using a visual analog scale (VAS) score, Patient Satisfaction Index (PSI) and the Roland 5-point pain score.

Results: In the retrodiscal group, there was a statistically significant improvement in the VAS score after injection compared to baseline. In the classic group, there was a statistically significant improvement in the VAS score after injection compared to baseline. There was no statistically significant difference in the VAS score, PSI, or the Roland 5-point pain score between those treated with a retrodiscal approach and those treated with a classic approach.

Limitations: Secondary outcomes were not measured and the study did not include a mid- or long-term follow-up period.

Conclusion: In this study, TFESIs performed using a retrodiscal or classic approach had similar effects on radicular pain. The classic and the retrodiscal transforaminal steroid injection resulted in equivalent pain relief.

Key words: Corticosteroids, lumbar disc herniation, radicular pain, retrodiscal, transforaminal epidural injection

Pain Physician 2011; 14:353-360

Epidural steroid injections (ESI) may be used to treat lumbar radiculopathy (1-9). Steroid injections may be delivered to the epidural space via a caudal, interlaminar, or transforaminal approach, and the reported success rates ranged from 20 to 100%, with an average of 67% (1-12).

Compared with an interlaminar or caudal ESI, a transforaminal epidural steroid injection (TFESI) is expected to provide minimal risk of dural puncture, better delivery of medication to the site of radiculopathy, and increased distribution of the drug into the ventral epidural space (7,9,11-21).

In comparison studies of the effectiveness of interlaminar and bilateral TFESIs, they allow a higher concentration of the injectants to be delivered into the ventral epidural space bilaterally, and resulted in better short-term pain relief and fewer long-term surgical interventions compared to the interlaminar ESI (3,4,7,9,11,12,22-32). In follow-up studies, significant pain reduction was achieved for up to one year after initiation of treatment in patients with discogenic pain and possibly in patients with spinal stenosis (33).

To increase the efficacy of steroid injection, various TFESI approaches have been studied (34-36). The TFESIs via a preganglionic approach provide a shorter delivery route and also allow the delivery of a higher dose of medication to the target site (34,35,37). Another advantage of the preganglionic approach is that the injectant distributes predominantly in the epidural space at the disc level. Kabatas et al (34) demonstrated that fluoroscopically guided TFESIs via a preganglionic approach in patients with foraminal stenosis due to lumbar spinal stenosis and lumbar discogenic pain with radiculopathy are effective and that patients responding to injection have significantly lower post-injection pain scores. Jasper (36) reported that retrodiscal contrast medium injection results in reliable coverage of the retrodiscal region, the exiting nerve at that foraminal level, and the proximal portion of the transiting segmental neural sleeve. In addition, retrodiscal TFESIs may flow centrally toward the midline or reach the first segment of the retrodiscal radicular canal and may flow caudally across the disc below.

As mentioned previously, the retrodiscal approach may cover more of the paracentral space of the intervertebral disc. Thus, we attempted to determine whether retrodiscal TFESIs were more effective than the classic approach in patients with intervertebral disc herniation.

METHODS

This study was conducted with the full approval of the Institutional Review Board (IRB) and written informed consent was obtained from all participants. Forty consecutive patients were enrolled and followed for 8 weeks in this randomized, double-blind, single center study. The study included patients between the ages of 18 and 80 with a diagnosis of lumbar radicular pain based on an appropriate distribution of pain and magnetic resonance imaging (MRI) showing paracentral or subarticular and single level intervertebral disc herniation. Exclusion criteria were as follows: foraminal and/

or extraforaminal herniated intervertebral disc (HIVD), spinal stenosis of any type, chronic use of oral steroid medication, oral, peripheral, or epidural steroid use within the last 3 months, having an oral temperature greater than 100.4°F, pregnancy, cognitive impairment, inability to give consent, use of aspirin, clopidogrel, warfarin, or heparin use in the previous 2 weeks, a history of bleeding disorders, a history of lumbar surgery, and axial pain.

Participants were randomly assigned to one of 2 groups. Those in the first group received classic TFESIs (Group 1, n=20) and those in the second group received retrodiscal TFESIs (Group 2, n=20). All injections were performed by the same anesthesiologist. Each participant was placed in the prone position.

For the classic transforaminal approach, after sterile preparation, draping, and local anesthesia, a 23 G, 3.5-inch spinal needle was gently advanced under fluoroscopic guidance with an oblique view to the safe-triangle, which is formed by the pedicle, a tangential base that corresponds to the exiting nerve root, and the lateral border of the vertebral body. Both the anteroposterior (AP) and lateral fluoroscopic projections confirmed proper needle placement. At each level, 0.5 mL of contrast medium (iohexol) was injected to confirm the position. An adequate flow of contrast medium to the target area was documented using real-time fluoroscopy and no blood or cerebrospinal fluid (CSF) was aspirated. In the absence of intravascular injection, the physician injected the 40 mg of triamcinolone acetate (Triam, Shinpoong, South Korea) diluted with 1-3 mL of local anesthetics (Fig. 1).

For the retrodiscal transforaminal injection, the patient was placed prone on the x-ray table. The targeted disc's endplates were aligned as for discography with an appropriate caudal or cranial tilt of the C-arm. The beam was then rotated so that the lateral surface of the superior articular process (SAP) bisected the interspace. A 10 cm Tuohy 23G epidural needle was advanced slowly and cautiously past the lateral surface of the SAP, avoiding penetration of both the segmental nerve and the disc. Lateral radiographic imaging was also used while advancing past the SAP to minimize the risk of disc penetration. Additionally, the resistance to needle advancement was used as a sign to stop advancing the needle. The AP view most often demonstrated the tip of the needle in the interpedicular line. Transforaminal injection may be performed through the needle with 1-3 mL of contrast medium; if this injection is adequate to cover the target, it is followed by 1-3 mL of 1% li-

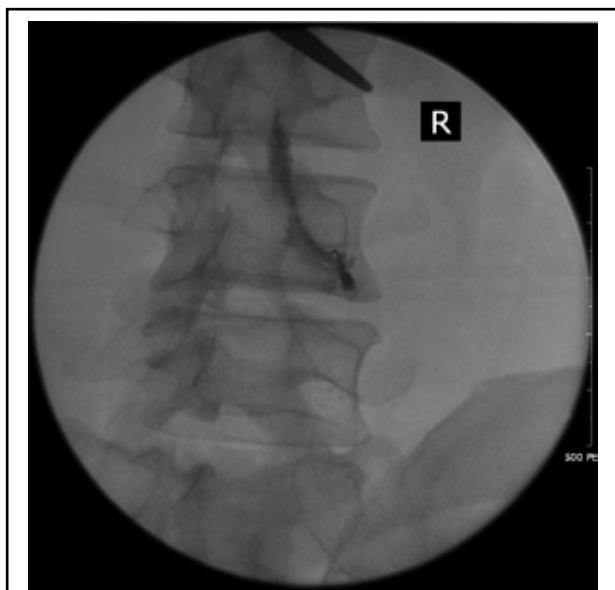
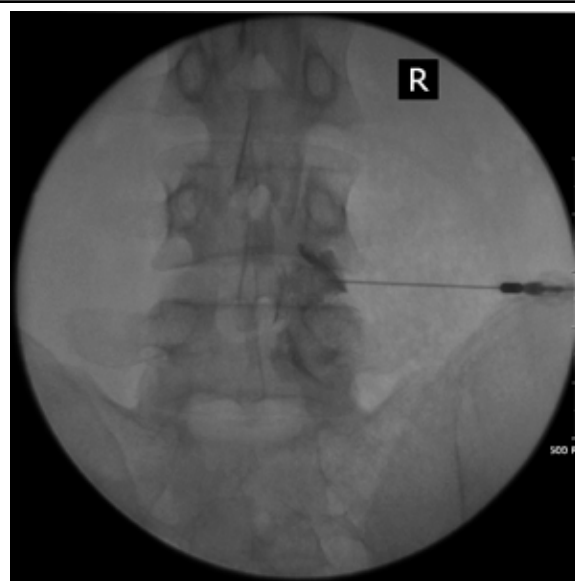
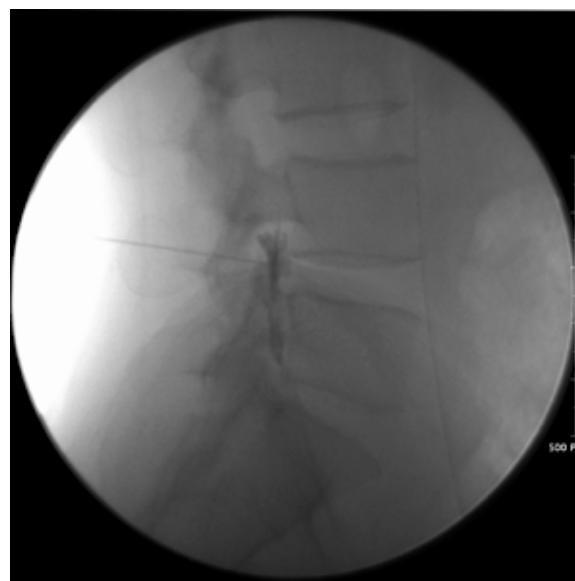


Fig 1. Classic transforaminal epidural steroid injection at L4-5. An oblique radiograph shows that contrast material has spread to L4-5 disc.



A



B

Fig 2. Radiographs of a 38-year old man with radicular pain to the right buttock and lower leg in the L5 dermatome. An MRI image (not shown) revealed a right paracentral L4-5 disc herniation with compression of the right L5 nerve root. TFESI with a retrodiscal approach was performed at L4-5. (a) A posteroanterior spot radiograph shows that contrast material has spread to the L4-5 disc. (b) A lateral spot radiograph shows the needle tip in the posterior aspect of the L4-5 disc space.

docaine and 1-2 mL of corticosteroid (Figs 2A, B). The volumes needed were determined from the contrast medium volume required to achieve the desired coverage in both groups.

Patients were evaluated individually by visual analog scale (VAS) pain score, a patient satisfaction index (PSI) score, and the Roland 5-point pain score at pre-treatment, and at 2, 4, and 8 weeks after treatment. The Roland 5-point pain scale is as follows: 0- absent of pain; 1 - little pain; 2 - moderate pain; 3 - bad pain; 4 - very bad pain; and 5- almost unbearable pain. The PSI scores (North American Spine Society Score) were as follows: 1 - the treatment met my expectations; 2 - I did not improve as much as I had hoped, but I would undergo the same treatment for the same outcome; 3 - I did not improve as much as I had hoped, and I would not undergo the same treatment for the same outcome; and 4 - I am the same or worse than before treatment.

Repeated measure of analysis of variance (ANOVA) was used to compare the efficacy of different approaches. All statistical analyses were performed using a statistical software program (SPSS 17, IBM, Armonk, New York). A P value of less than or equal to 0.05 was considered statistically significant.

RESULTS

The 40 participants were randomized into equal groups of 20. The 2 groups did not differ significantly with respect to age, gender, or spinal segment treated (Table 1). The mean values of the pain scores before treatment were not significantly different between the two groups (Table 2).

None of the patients experienced any complications, and all the patients completed the follow-up vis-

it. After treatment, both groups significantly improved their mean pain scores, but there were no significant differences between both groups (Table 2). One patient in Group 1 and 2 patients in Group 2 underwent surgery. In addition, the proportion of patients who achieved pain relief was not significantly different between the groups (Tables 3 and 4).

Notwithstanding these improvements and the difference between pain scores, the post-treatment scores using the Roland 5-point pain scale and PSI score were not significantly different between the groups (Figs. 3 and 4).

Table 1. *The demographic and clinical features of patients with lumbar radicular pain treated with transforaminal injections of either classic or retrodiscal approach.*

	Classic (n=20)	Retrodiscal (n=20)
Age	48.9 ± 13.5	42.8 ± 13.2
Sex (M : F)	9 : 11	12 : 8
Weight (kg)	60.3 ± 11.0	64.8 ± 10.0
Height (cm)	162.9 ± 9.2	167.4 ± 8.0
Site		
L34	3	1
L45	10	18
L5S1	7	1
Duration of pain (month)	6.5 ± 9.0	4.0 ± 4.2

DISCUSSION

A systematic review of 7 controlled trials found Level II-1 evidence that transforaminal injection of steroids is effective for the short-term relief of radicular pain (8). Our results are consistent with this previous evidence. Significant improvement in pain was achieved irrespective of approaches used. Also, our study demonstrated that for the relief of lumbar radicular pain, transforaminal injections using the classic approach or retrodiscal approach were not different.

Several studies have compared TFESI with other methods (interlaminar or caudal approaches) (8,22,23,38). This result is similar to that of Vad et al (16), who reported an 84% success in patients with lumbosa-

Table 2. *Comparative responses from visual analogue scale score pre- and post-injection for both classic and retrodiscal approach*

	Pre-treat	2 weeks	4 weeks	8 weeks	P value
Classic	6.7 ± 1.9	3.2 ± 2.0	3.1 ± 1.6	3.0 ± 1.6	0.000
Retrodiscal	7.5 ± 1.3	4.0 ± 2.3	3.7 ± 1.7	3.5 ± 1.5	0.000

Table 3. *The distribution of visual analogue scores (VAS) for radicular pain before and after treatment of patients treated with transforaminal injection of classic approach*

Classic Transforaminal epidural injections						
ΔVAS%	2 weeks		4 weeks		8 weeks	
	frequency	%	frequency	%	frequency	%
90-100	0	0	0	0	0	0
80-89	2	10.5	0	0	0	0
70-79	6	31.6	6	31.6	5	26.3
60-69	1	5.3	2	10.6	3	15.9
50-59	3	15.8	5	26.4	5	26.4
< 50	8	31.6	5	26.4	5	26.4

Table 4. The distribution of visual analogue scores (VAS) for radicular pain before and after treatment of patients treated with transforaminal injection of retrodiscal approach

Retrodiscal transforaminal epidural injections						
	2 weeks		4 weeks		8 weeks	
	frequency	%	frequency	%	frequency	%
90-100	0	0	0	0	0	0
80-89	2	10.0	0	0	0	0
70-79	4	20.0	6	30.0	6	30.0
60-69	3	15.0	1	5.0	1	5.0
50-59	2	10.0	4	15.0	4	20.0
< 50	8	40	5	30.0	4	20.0

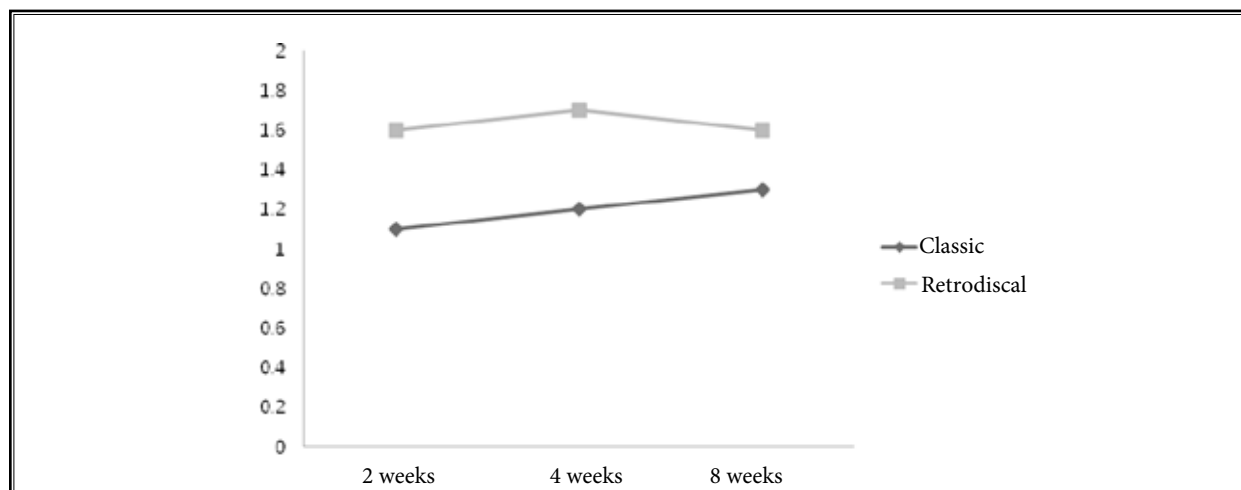


Fig 3. Change of Roland 5-point pain scale

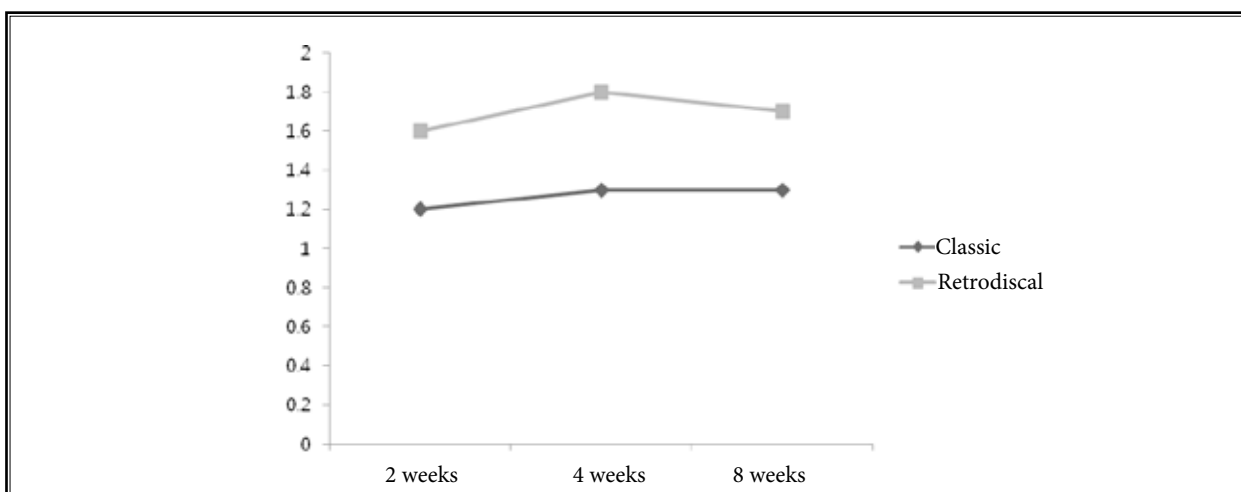


Fig 4. Changes of Patient Satisfaction Index

cral radiculopathy who underwent TFESI. This finding is also consistent with theoretical expectation that TFESIs should be more effective because they directly deliver medication to the exact pathologic location (16).

In the present study, there was no significant difference in efficacy between the classic or the retrodiscal approach for lumbar transforaminal injections. A retrodiscal approach technique is similar to preganglionic TFESIs. Jeong et al (13) reported that a TFESI for lumbosacral radiculopathy with preganglionic approach is more effective than TFESI with a ganglionic approach. The reason is that in the preganglionic approach, injectants distribute themselves predominantly in the epidural space at the disc level and most of the injectant is deposited into the epidural space (3). However, the effects of retrodiscal and preganglionic injections are different. The retrodiscal injection results in more coverage of the retrodiscal region, the exiting nerve at that foraminal level, and the proximal portion of the transiting segmental neural sleeve than the preganglionic approach does (36).

In our study, both approaches relieved pain. We had hypothesized that both approaches would achieve coverage of both the intervertebral disc level and the affected segmental nerve.

However, Jeong et al's study (13) included patients with foraminal or extraforaminal herniated nucleus pulposus (HNP) and a fixed injection volume. Although previous studies demonstrated no significant differences between small (2 mL) and large volumes (8 mL) of injectant using the transforaminal approach (22), when more than 2.8 mL of contrast medium was injected, 95% of the L-TFESIs spread to the superior aspect of the superior intervertebral disc (IVD) at the corresponding

level of injection (39). Therefore, it did not guarantee similar coverage of both the intervertebral disc level and the affected segmental nerve in both approaches. Because of those conditions, our results are different from the previous study. We confirmed, with radiography, the contrast flow and the volumes needed to fully cover the pain sources.

TFESI is an effective method for treating spinal pain but can cause devastating complications that result from accidental vascular uptake of the injectant, a direct vascular injury, or intradiscal injection (40-50). Nahm et al (40) reported that the overall incidence of intravascular injection was 10.5% and that the incidence at the lumbar levels is 6.1%. Levi (41) reported the occurrence of intradiscal injections despite the needle having been placed in the conventional location during TFESIs. The retrodiscal TFESI approach may carry a higher risk of intradiscal placement of contrast medium. But in our study, intradiscal injection did not occur in either group. The location of the radiculomedullary artery has been shown to be along the superoanterior aspect of the foramen (51).

A limitation of our results is that the significant improvements in pain that we identified were not corroborated with any secondary outcomes. Second, follow-up was less than 6 months, so there were no results from mid- or long-term follow-up periods.

CONCLUSION

For the short-term relief of lumbar radicular pain, transforaminal injection is effective, but neither classic nor retrodiscal transforaminal steroid injection resulted in superior pain improvement in patients with paracentral herniation of an intervertebral disc..

REFERENCES

1. Chou R, Huffman L. *Guideline for the Evaluation and Management of Low Back Pain: Evidence Review*. American Pain Society, Glenview, IL, 2009. www.ampainsoc.org/pub/pdf/LBPEvidRev.pdf
2. Staal JB, de Bie RA, de Vet HC, Hildebrandt J, Nelemans P. Injection therapy for subacute and chronic low back pain: An updated Cochrane review. *Spine (Phila Pa 1976)* 2009; 34:49-59.
3. Manchikanti L, Boswell MV, Singh V, Benyamin RM, Fellows B, Abdi S, Buenaventura RM, Conn A, Datta S, Derby R, Falco FJE, Erhart S, Diwan S, Hayek SM, Helm S, Parr AT, Schultz DM, Smith HS, Wolfer LR, Hirsch JA. Comprehensive evidence-based guidelines for interventional techniques in the management of chronic spinal pain. *Pain Physician* 2009; 12:699-802.
4. Manchikanti L, Boswell MV, Datta S, Fellows B, Abdi S, Singh V, Benyamin RM, Falco FJE, Helm S, Hayek S, Smith HS. Comprehensive review of therapeutic interventions in managing chronic spinal pain. *Pain Physician* 2009; 12:E123-E198.
5. Conn A, Buenaventura R, Datta S, Abdi S, Diwan S. Systematic review of caudal epidural injections in the management of chronic low back pain. *Pain Physician* 2009; 12:109-135.
6. Parr AT, Diwan S, Abdi S. Lumbar interlaminar epidural injections in managing chronic low back and lower extremity pain: A systematic review. *Pain Physician* 2009; 12:163-188.
7. Benyamin RM, Singh V, Parr AT, Conn A, Diwan S, Abdi S. Systematic review of the effectiveness of cervical epidurals in the management of chronic neck pain.

- Pain Physician* 2009; 12:137-157.
8. Buenaventura RM, Datta S, Abdi S, Smith HS. Systematic review of therapeutic lumbar transforaminal epidural steroid injections. *Pain Physician* 2009; 12:233-251.
 9. Roberts ST, Willick SE, Rho ME, Rittenberg JD. Efficacy of lumbosacral transforaminal epidural steroid injections: A systematic review. *PM R* 2009; 1:657-668.
 10. Cooper G, Lutz GE, Boachie-Adjei O, Lin J. Effectiveness of transforaminal epidural steroid injections in patients with degenerative lumbar scoliotic stenosis and radiculopathy. *Pain Physician* 2004; 7:311-317.
 11. Bogduk N, Cherry D. Epidural corticosteroid agents for sciatica. *Med J Aust* 1985; 143:402-406.
 12. Bogduk N. Epidural steroids. *Spine (Phila Pa 1976)* 1995; 20:845-848.
 13. Jeong HS, Lee JW, Kim SH, Myung JS, Kim JH, Kang HS. Effectiveness of transforaminal epidural steroid injection by using a preganglionic approach: A prospective randomized controlled study. *Radiology* 2007; 245:584-90.
 14. Cluff R, Mehio AK, Cohen SP, Chang Y, Sang CN, Stojanovic MP. The technical aspects of epidural steroid injections: A national survey. *Anesth Analg* 2002; 95:403-408.
 15. Manchikanti L. Transforaminal lumbar epidural steroid injections. *Pain Physician* 2000; 3:374-98.
 16. Vad VB, Bhat AL, Lutz GE, Cammisa F. Transforaminal epidural steroid injections in lumbosacral radiculopathy: A prospective randomized study. *Spine (Phila Pa 1976)* 2002; 27:11-16.
 17. Riew KD, Park JB, Cho YS, Gilula L, Patel A, Lenke LG, Bridwell KH. Nerve root blocks in the treatment of lumbar radicular pain. A minimum five-year follow-up. *J Bone Joint Surg Am* 2006; 88:1722-1725.
 18. Riew KD, Yin Y, Gilula L, Bridwell KH, Lenke LG, Laurusen C, Goette K. The effect of nerve-root injections on the need for operative treatment of lumbar radicular pain. A prospective, randomized, controlled, double-blind study. *J Bone Joint Surg Am* 2000; 82-A:1589-1593.
 19. Devulder J. Transforaminal nerve root sleeve injection with corticosteroids, hyaluronidase, and local anesthetic in the failed back surgery syndrome. *J Spinal Disord* 1998; 11:151-154.
 20. Karppinen J, Malmivaara A, Kurunlahti M, Ohinmaa A, Pienimäki T, Nieminen P, Ohinmaa A, Tervonen O, Vanharanta H. Periradicular infiltration for sciatica: A randomized controlled trial. *Spine (Phila Pa 1976)* 2001; 26:1059-1067.
 21. Karppinen J, Ohinmaa A, Malmivaara A, Kurunlahti M, Kyllönen E, Pienimäki T, Nieminen P, Tervonen O, Vanharanta H. Cost effectiveness of periradicular infiltration for sciatica: Subgroup analysis of a randomized controlled trial. *Spine (Phila Pa 1976)* 2001; 26:2587-2595.
 22. Lee JH, An JH, Lee SH. Comparison of the effectiveness of interlaminar and bilateral transforaminal epidural steroid injections in treatment of patients with lumbosacral disc herniation and spinal stenosis. *Clin J Pain* 2009; 25:206-210.
 23. Schaufele MK, Hatch L, Jones W. Interlaminar versus transforaminal epidural injections for the treatment of symptomatic lumbar intervertebral disc herniations. *Pain Physician* 2006; 9:361-366.
 24. Manchikanti L, Cash KA, McManus CD, Pampati V, Smith HS. One-Year Results of a Randomized, Double-Blind, Active Controlled Trial of Fluoroscopic Caudal Epidural Injections With or Without Steroids in Managing Chronic Discogenic Low Back Pain Without Disc Herniation or Radiculitis Randomized Trial. *Pain Physician* 2011; 14:25-36.
 25. Manchikanti L, Singh V, Cash KA, Pampati V, Damron KS, Boswell MV. Preliminary results of randomized, equivalence trial of fluoroscopic caudal epidural injections in managing chronic low back pain: Part 2. Disc herniation and radiculitis. *Pain Physician* 2008; 11:801-815.
 26. Manchikanti L, Singh V, Cash KA, Pampati V, Datta S. Management of Pain of Post Lumbar Surgery Syndrome: One-Year Results of a Randomized, Double-Blind, Active Controlled Trial of Fluoroscopic Caudal Epidural Injections. *Pain Physician* 2010; 13:509-521.
 27. Manchikanti L, Cash KA, McManus CD, Pampati V, Abdi S. Preliminary results of randomized, equivalence trial of fluoroscopic caudal epidural injections in managing chronic low back pain: Part 4. Spinal stenosis. *Pain Physician* 2008; 11:833-848.
 28. Manchikanti L, Cash KA, Pampati V, Wargo BW, Malla Y. Cervical epidural injections in chronic discogenic neck pain without disc herniation or radiculitis: Preliminary results of a randomized, double-blind, controlled trial. *Pain Physician* 2010; 13:E265-E278.
 29. Manchikanti L, Cash KA, Pampati V, Wargo BW, Malla Y. The effectiveness of fluoroscopic cervical interlaminar epidural injections in managing chronic cervical disc herniation and radiculitis: Preliminary results of a randomized, double-blind, controlled trial. *Pain Physician* 2010; 13:223-236.
 30. Manchikanti L, Singh V, Falco FJE, Cash KA, Pampati V. Evaluation of the effectiveness of lumbar interlaminar epidural injections in managing chronic pain of lumbar disc herniation or radiculitis: A randomized, double-blind, controlled trial. *Pain Physician* 2010; 13:343-355.
 31. Manchikanti L, Cash KA, McManus CD, Pampati V, Benyamin RM. Preliminary results of a randomized, double-blind, controlled trial of fluoroscopic lumbar interlaminar epidural injections in managing chronic lumbar discogenic pain without disc herniation or radiculitis. *Pain Physician* 2010; 13:E279-E292.
 32. Manchikanti L, Cash KA, McManus CD, Pampati V, Benyamin RM. A preliminary report of a randomized double-blind, active controlled trial of fluoroscopic thoracic interlaminar epidural injections in managing chronic thoracic pain. *Pain Physician* 2010; 13:E357-E369.
 33. Rosenberg SK, Grabinsky A, Kooser C, Boswell MV. Effectiveness of transforaminal epidural steroid injections in low back pain: A one year experience. *Pain Physician* 2002; 5:266-270.
 34. Kabatas S, Cansever T, Yilmaz C, Kocyigit OI, Coskun E, Demircay E, Akar A, Caner H. . Transforaminal epidural steroid injection via a preganglionic approach for lumbar spinal stenosis and lumbar discogenic pain with radiculopathy. *Neurol India* 2010; 58:248-252.
 35. Lew HL, Coelho P, Chou LH. Preganglionic approach to transforaminal epidural steroid injections. *Am J Phys Med Rehabil* 2004; 83:378.
 36. Jasper JF. Lumbar retrodiscal transforaminal injection. *Pain Physician* 2007; 10:501-510.
 37. Lee JW, Kim SH, Choi JY, Yeom JS, Kim KJ, Chung SK, Kim HJ, Kim C, Kwack KS, Kwon JW, Moon SG, Jun WS, Kang HS. Transforaminal epidural steroid injection for lumbosacral radiculopathy: Preganglionic versus conventional approach. *Korean J Radiol* 2006; 7:139-44.
 38. Smith CC, Booker T, Schaufele MK, Weiss P. Interlaminar versus transforaminal epidural steroid injections for the treatment of symptomatic lumbar spinal stenosis. *Pain Med* 2010; 11:1511-

- 1515.
39. Furman MB, Mehta AR, Kim RE, [Simon JI](#), Patel R, Lee TS, Reeves RS. . Injectate volumes needed to reach specific landmarks in lumbar transforaminal epidural injections. *PM R* 2010; 2:625-635.
40. Nahm FS, Lee CJ, Lee SH, Kim TH, Sim WS, Cho HS, Park SY, Kim YC, Lee SC. Risk of intravascular injection in transforaminal epidural injections. *Anaesthesia* 2010; 65:917-921.
41. Levi D. Intradiscal flow during a transforaminal epidural steroid injection. *Pain Med* 2010; 11:716-718.
42. Huntoon MC, Martin DP. Paralysis after transforaminal epidural injection and previous spinal surgery. *Reg Anesth Pain Med* 2004; 29:494-495.
43. Houten JK, Errico TJ. Paraplegia after lumbosacral nerve root block: Report of three cases. *Spine (Phila Pa 1976)* 2002; 27:70-75.
44. Somayaji HS, Saifuddin A, Casey AT, Briggs T. Spinal cord infarction following therapeutic computed tomography-guided left L2 nerve root injection. *Spine (Phila Pa 1976)* 2005; 30:E106-E108.
45. Martin DP, Huntoon MA. Spinal cord infarction following therapeutic computed tomography-guided left L2 nerve root injection. *Spine (Phila Pa 1976)* 2005; 30:1558.
46. Glaser SE, Shah RV. Root cause analysis of paraplegia following transforaminal epidural steroid injections: The 'unsafe' triangle. *Pain Physician* 2010; 13:237-244.
47. Helm S, Glaser S, Falco F, Henry B. A medical-legal review regarding the standard of care for epidural injections, with particular reference to a closed case. *Pain Physician* 2010; 13:145-150.
48. Glaser SE, Falco F. Paraplegia following a thoracolumbar transforaminal epidural steroid injection. *Pain Physician* 2005; 8:309-314.
49. Helm S 2nd, Jasper JF, Racz GB. Complications of transforaminal epidural injections. *Pain Physician* 2003; 6:389-390.
50. Windsor RE, Falco FJE. Paraplegia following selective nerve root blocks. *ISIS Scientific Newsletter*, 2001: 4:53-54.
51. Murthy NS, Maus TP, Behrns CL. Intraforaminal location of the great anterior radiculomedullary artery (artery of Adamkiewicz): A retrospective review. *Pain Med* 2010; 11:1756-1764.